

Unipolar and Bipolar Electrogram Analysis During Mapping

AF, VT, VF Summit 2019

Chicago, IL

December 6, 2019

Warren “Sonny” Jackman, MD

Heart Rhythm Institute

University of Oklahoma Health Sciences Center

Oklahoma City, OK

Disclosure

Consulting:

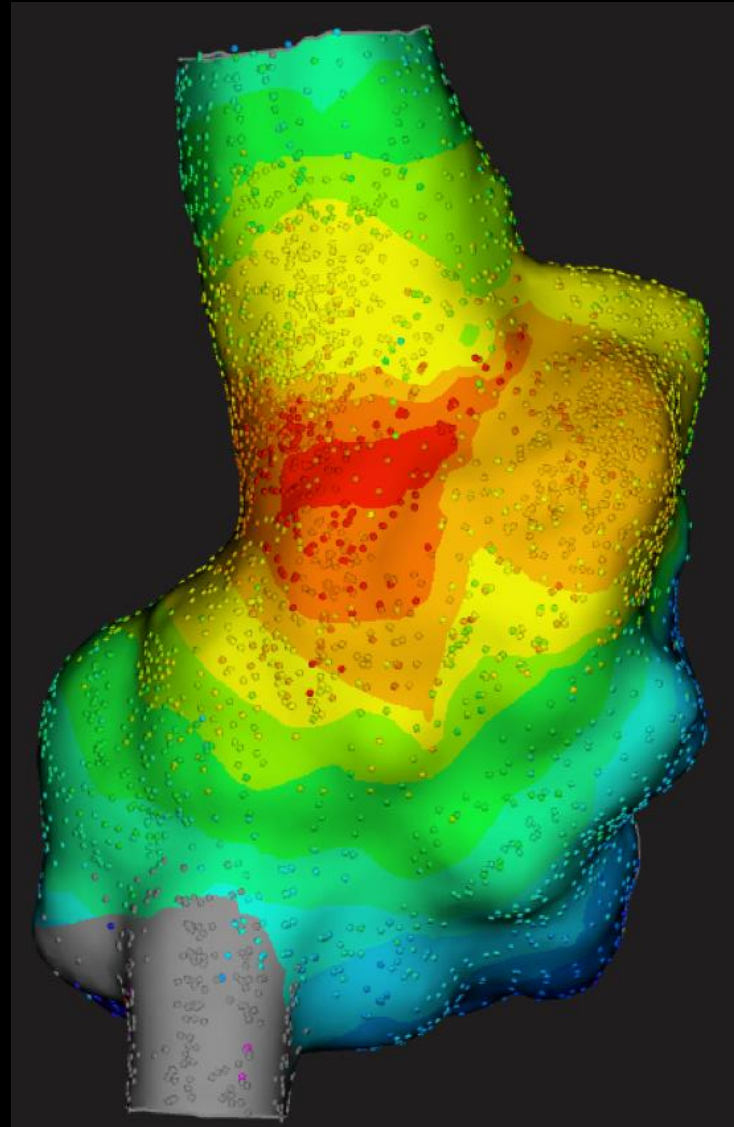
- Biosense Webster
- Affera (Stock)
- APN Health (Stock)
- Spectrum Dynamics

Lecture Honoraria:

- Biosense Webster
- Boston Scientific
- Biotronik
- Abbott

Crista Terminalis RA Tachycardia

Rapid, High Resolution
Multi-Electrode Mapping

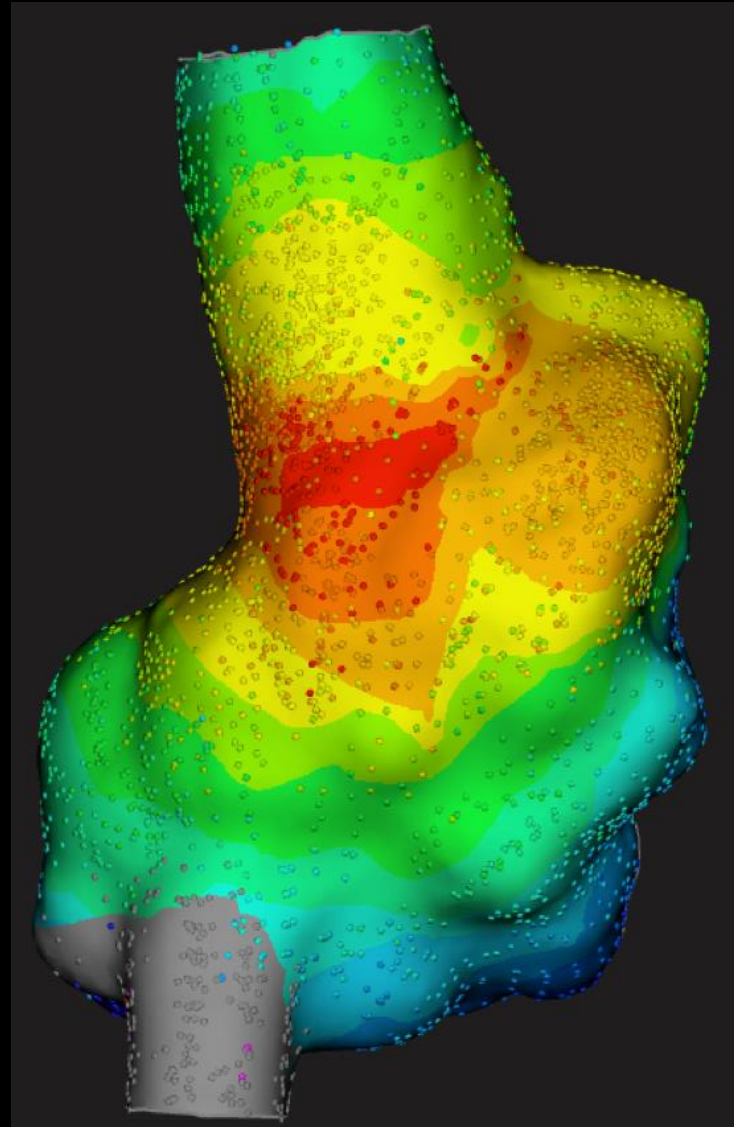


RAO Projection

Crista Terminalis RA Tachycardia

Rapid, High Resolution
Multi-Electrode Mapping

- Accurately Time Electrograms



RAO Projection

Crista Terminalis RA Tachycardia

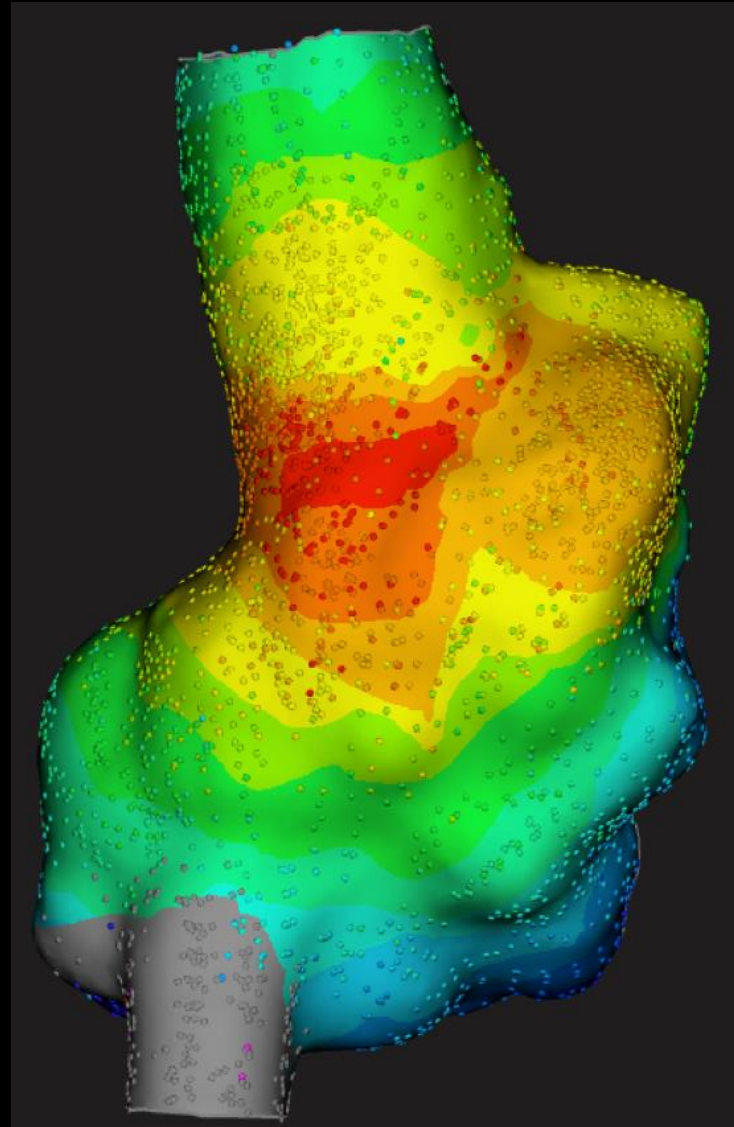
Rapid, High Resolution
Multi-Electrode Mapping

- Accurately Time Electrograms

Combine:

Bipolar EGM

Unipolar EGM



RAO Projection

Crista Terminalis RA Tachycardia

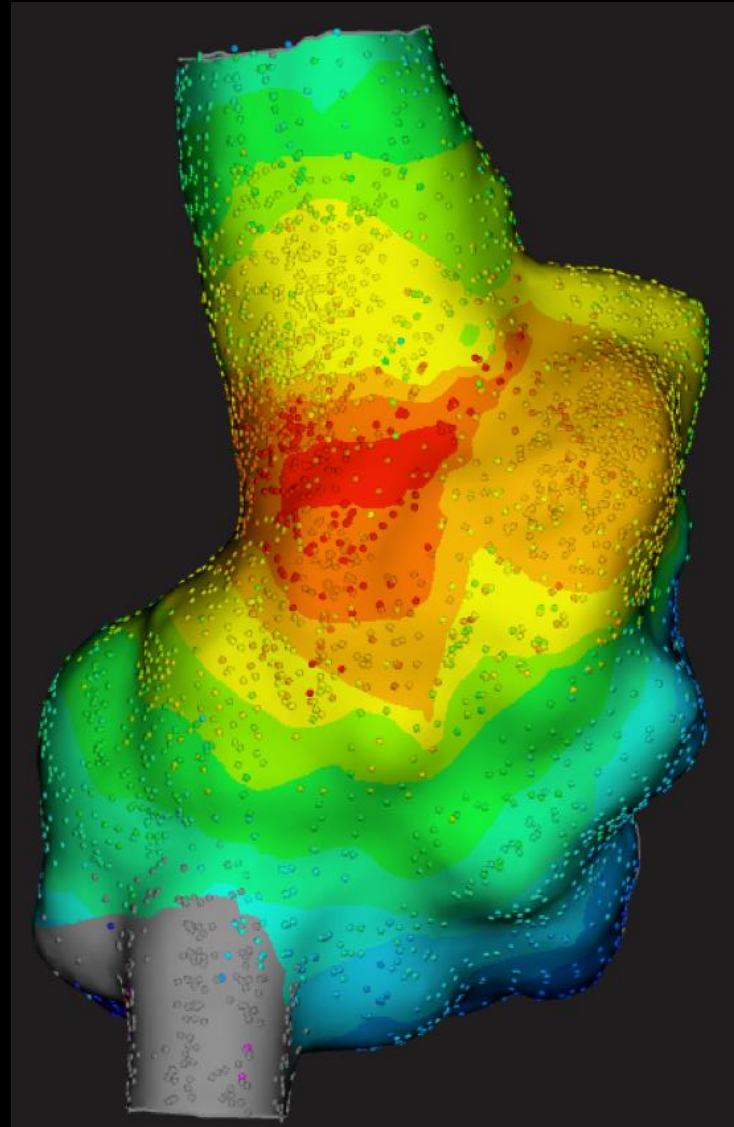
Rapid, High Resolution
Multi-Electrode Mapping

- Accurately Time Electrograms

Combine:

Bipolar EGM

– Eliminates Far-Field Components



RAO Projection

Crista Terminalis RA Tachycardia

Rapid, High Resolution
Multi-Electrode Mapping

- Accurately Time Electrograms

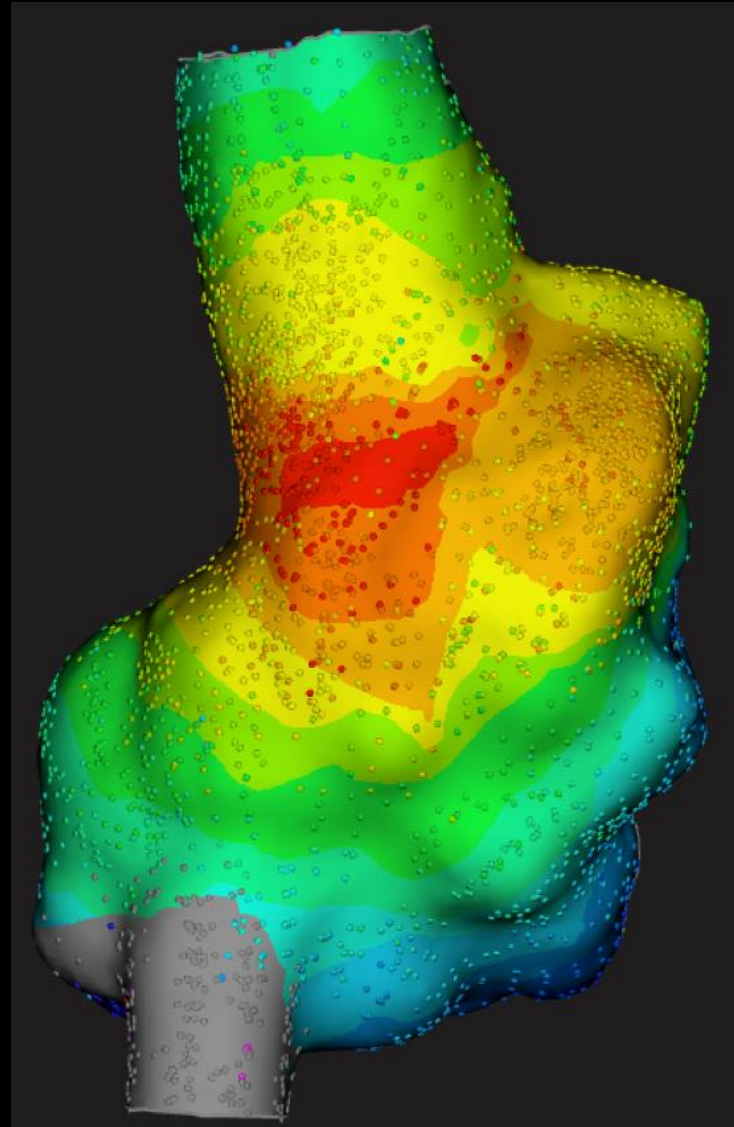
Combine:

Bipolar EGM

- Eliminates Far-Field Components

Unipolar EGM

- Actual Local Activation Time



RAO Projection

Crista Terminalis RA Tachycardia

Rapid, High Resolution
Multi-Electrode Mapping

- Accurately Time Electrograms

Combine:

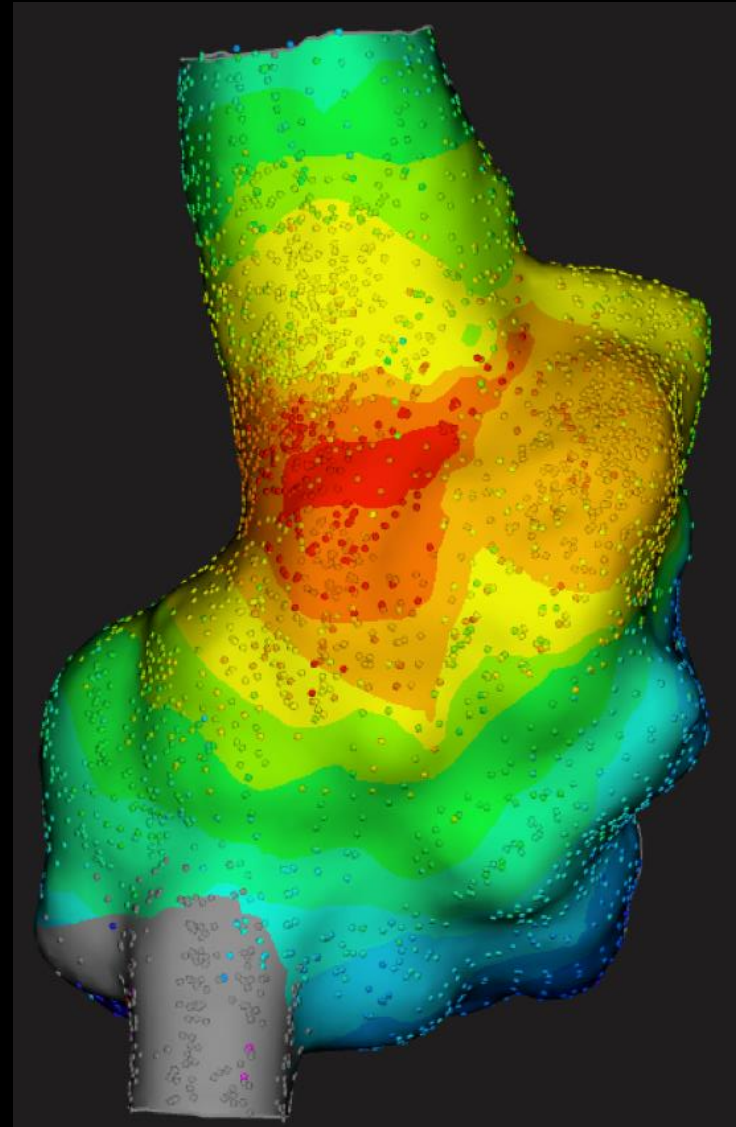
Bipolar EGM

– Eliminates Far-Field Components

Unipolar EGM

– Actual Local Activation Time

- Verify Activation Time



RAO Projection

Crista Terminalis RA Tachycardia

Rapid, High Resolution
Multi-Electrode Mapping

- Accurately Time Electrograms

Combine:

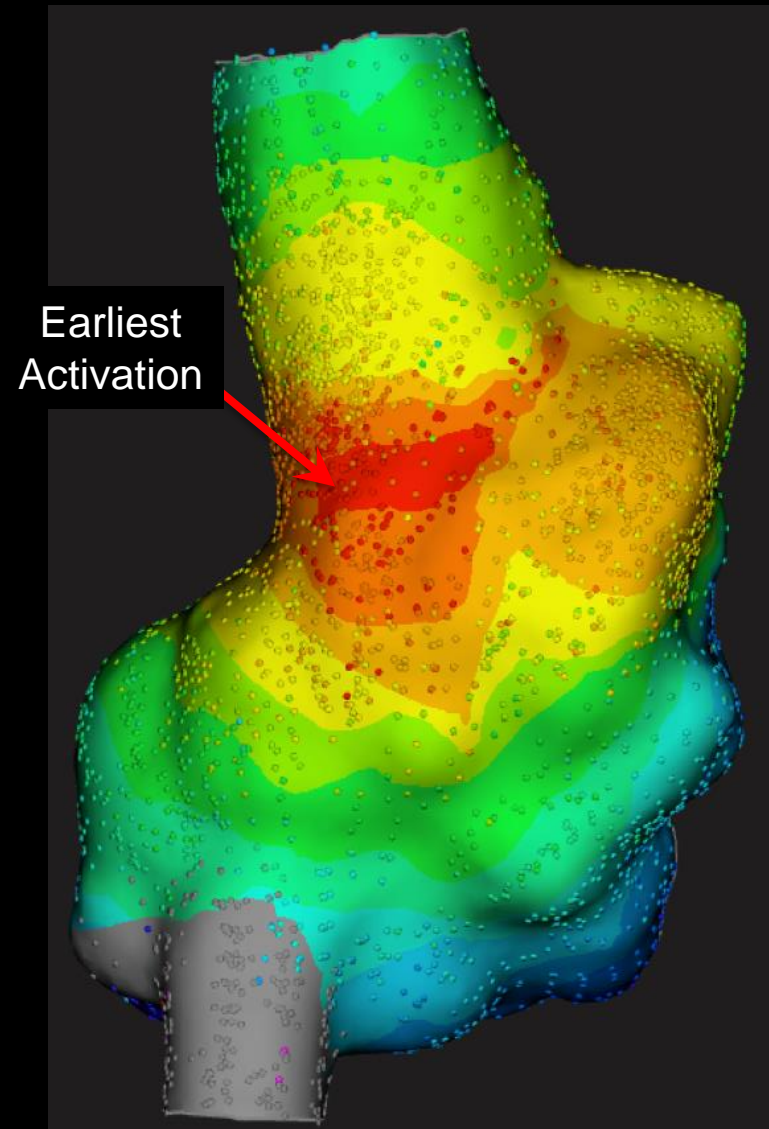
Bipolar EGM

– Eliminates Far-Field Components

Unipolar EGM

– Actual Local Activation Time

- Verify Activation Time



RAO Projection

Crista Terminalis RA Tachycardia

Rapid, High Resolution
Multi-Electrode Mapping

- Accurately Time Electrograms

Combine:

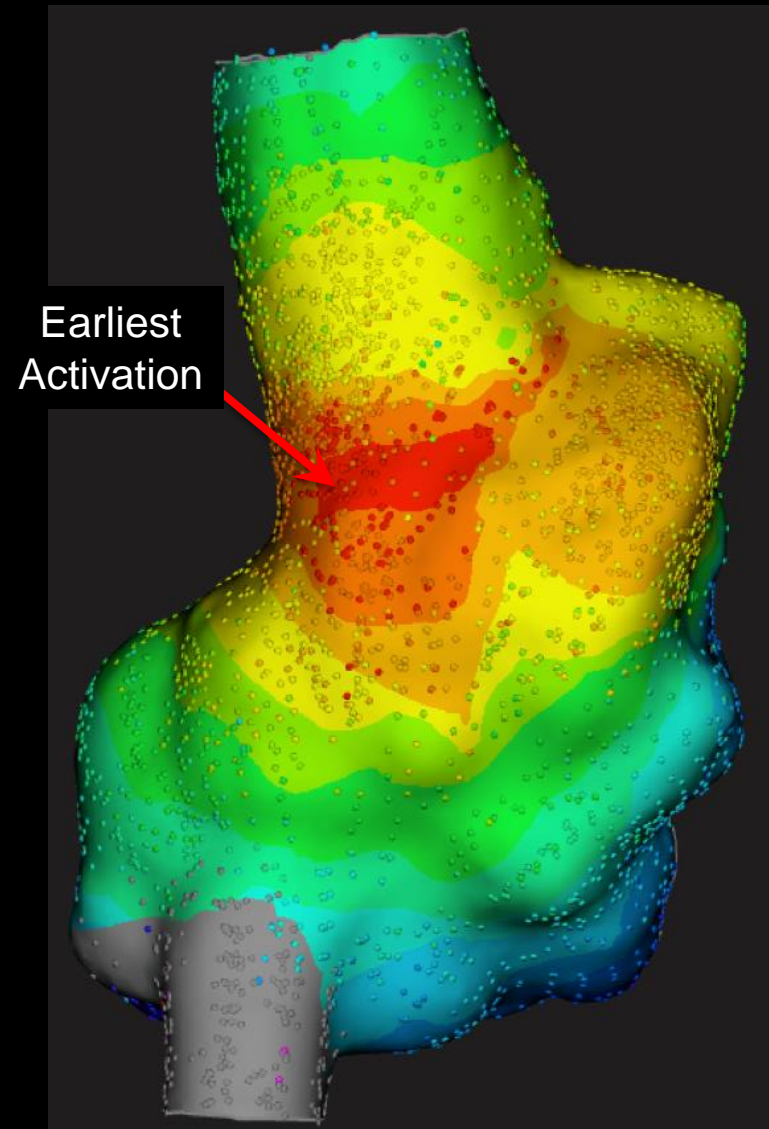
Bipolar EGM

– Eliminates Far-Field Components

Unipolar EGM

– Actual Local Activation Time

- Verify Activation Time
- Ablation Catheter



RAO Projection

Crista Terminalis RA Tachycardia

Rapid, High Resolution
Multi-Electrode Mapping

- Accurately Time Electrograms

Combine:

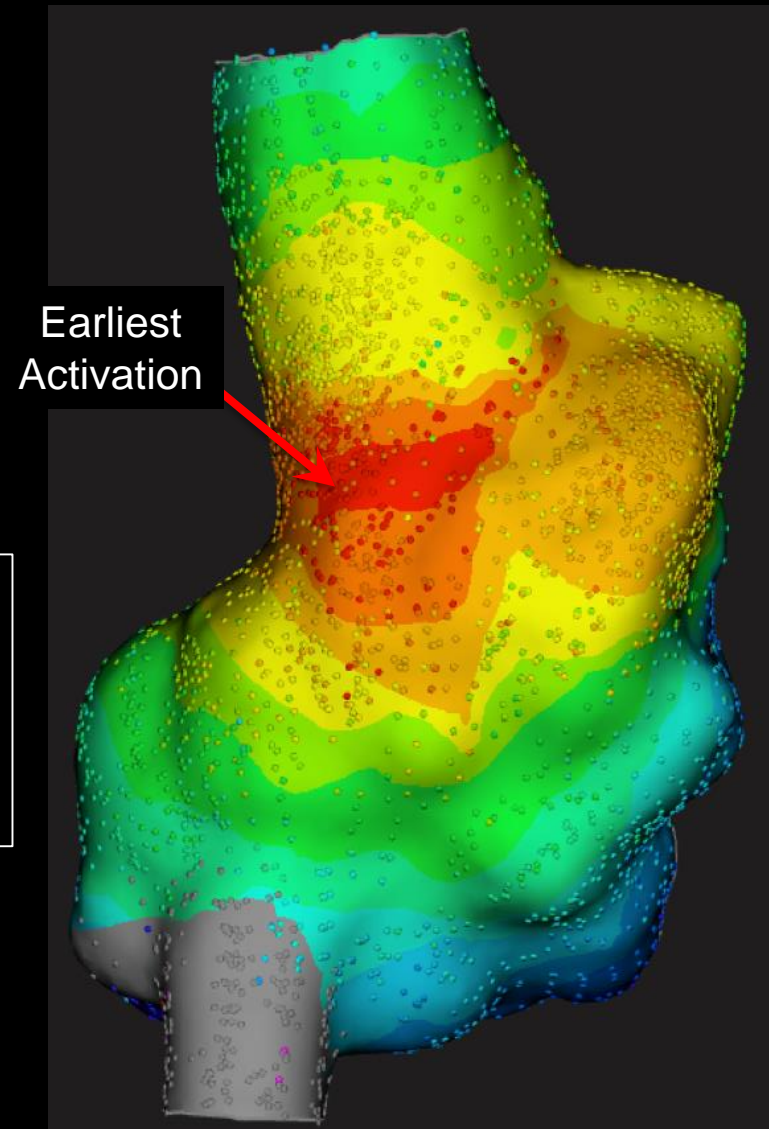
Bipolar EGM

– Eliminates Far-Field Components

Unipolar EGM

– Actual Local Activation Time

- Verify Activation Time
- Ablation Catheter



RAO Projection

Crista Terminalis RA Tachycardia

Rapid, High Resolution
Multi-Electrode Mapping

- Accurately Time Electrograms

Combine:

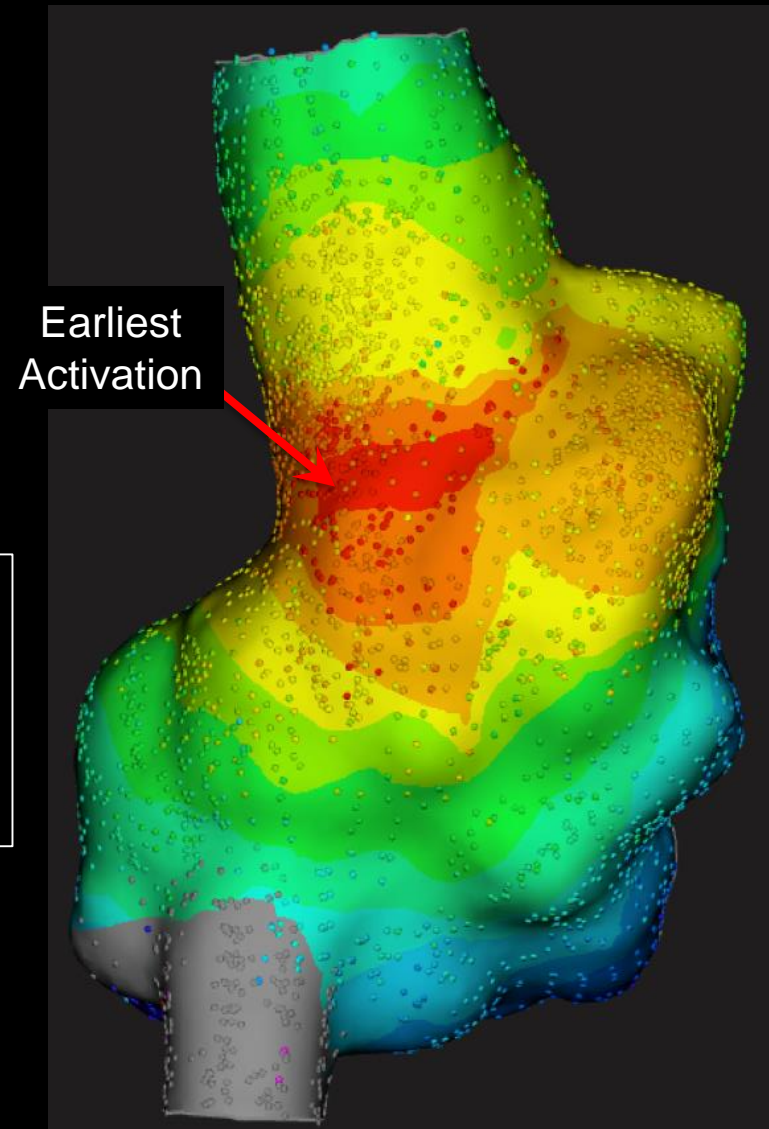
Bipolar EGM

– Eliminates Far-Field Components

Unipolar EGM

– Actual Local Activation Time

- Verify Activation Time
- Ablation Catheter



RAO Projection

Unipolar Electrogram



Differential Amplifier



Unipolar Electrogram



⊕ Mapping Electrode


⊖

Unipolar Electrogram




- ⊕ Mapping Electrode
- ⊖ Reference Electrode (Out of Chest)

Unipolar Electrogram



Unipolar Electrogram




Unipolar Electrogram



Toward Electrode - Positive

Away From electrode - Negative

Unipolar Electrogram

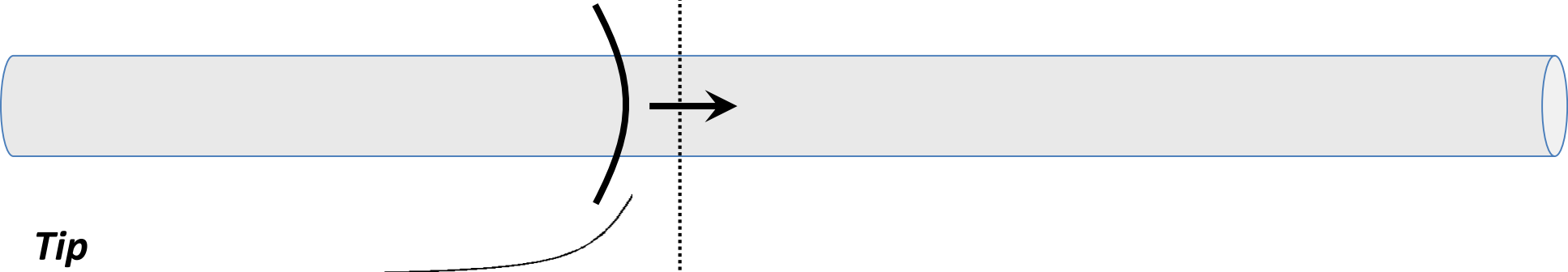


Tip

Toward Electrode - **Positive**

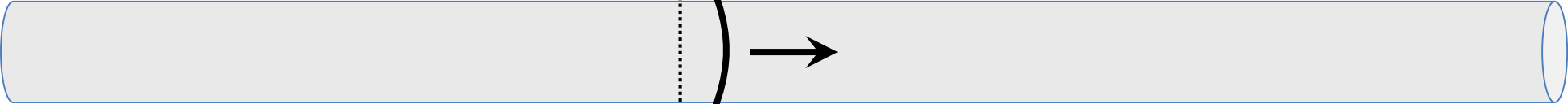
Away From electrode - Negative

Unipolar Electrogram



Toward Electrode – **Positive**
Away From electrode – Negative


Unipolar Electrogram




Tip

Toward Electrode – Positive

Away From electrode – **Negative**



Unipolar Electrogram




Tip

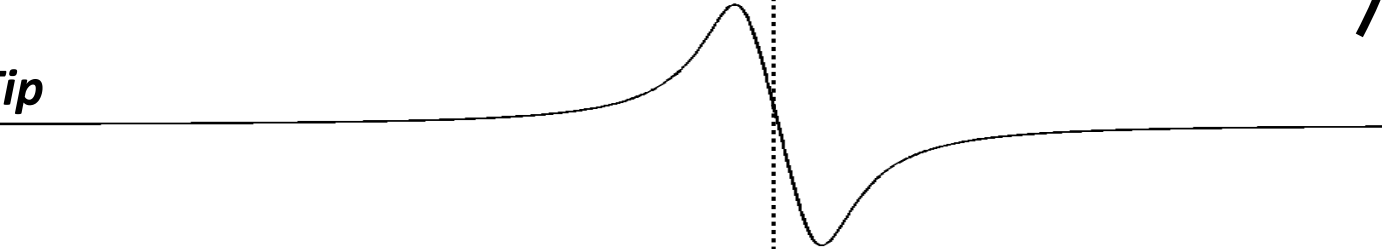
Toward Electrode – Positive

Away From electrode – **Negative**

Unipolar Electrogram




Tip



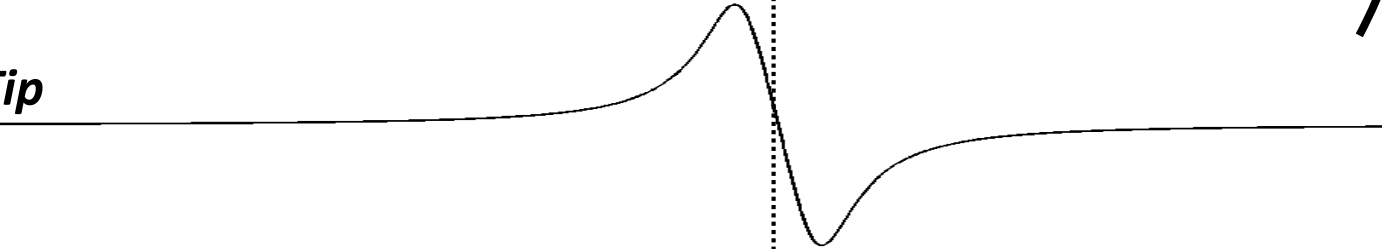
Toward Electrode – Positive

Away From electrode – **Negative**

Unipolar Electrogram



Tip



Local Activation Time
(Steep Negative)

Focal Pattern of Activation

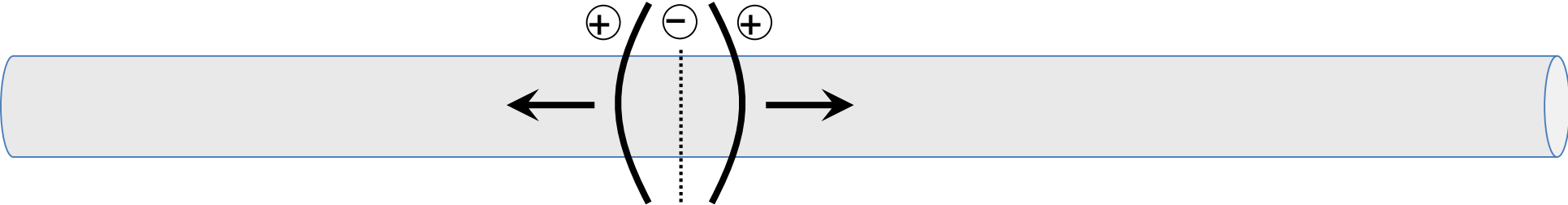
How do you know when you are at the
Site of Earliest Atrial Activation?

Focal Pattern of Activation

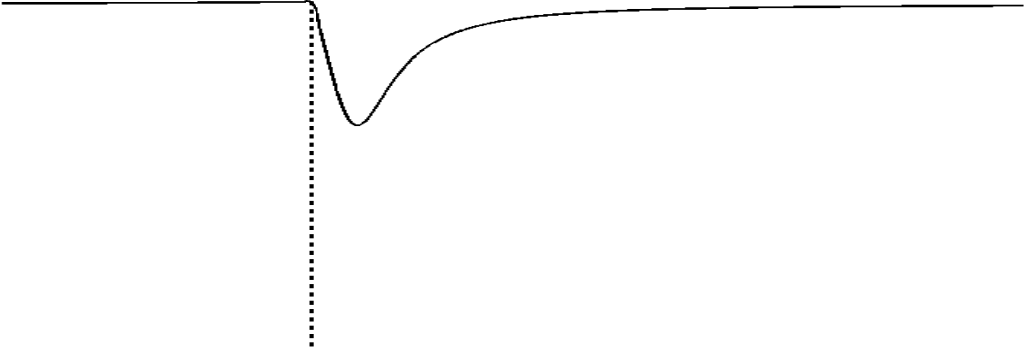
How do you know when you are at the
Site of Earliest Atrial Activation?

Unipolar EGM Begins Steep Negative

Unipolar Electrogram




Tip




Away From electrode – **Negative**

Rare Sites Mimicking
Earliest Activation



Tip

Isoelectric Segment
(Not at Site of
Onset of Activation)



How do you know when you are at the
Site of Earliest Atrial Activation?

1. Activation is as Early as Earliest Far-Field Potential Recorded

How do you know when you are at the
Site of Earliest Atrial Activation?

1. Activation is as Early as Earliest Far-Field Potential Recorded
 - Trigger Sweep (200 mm/s)
 - Time Line at Earliest Far-Field

How do you know when you are at the
Site of Earliest Atrial Activation?

1. Activation is as Early as Earliest Far-Field Potential Recorded
 - Trigger Sweep (200 mm/s)
 - Time Line at Earliest Far-Field
2. Distal Bipolar EGM and Unipolar 1 EGM Begin Simultaneously

How do you know when you are at the *Site of Earliest Atrial Activation?*

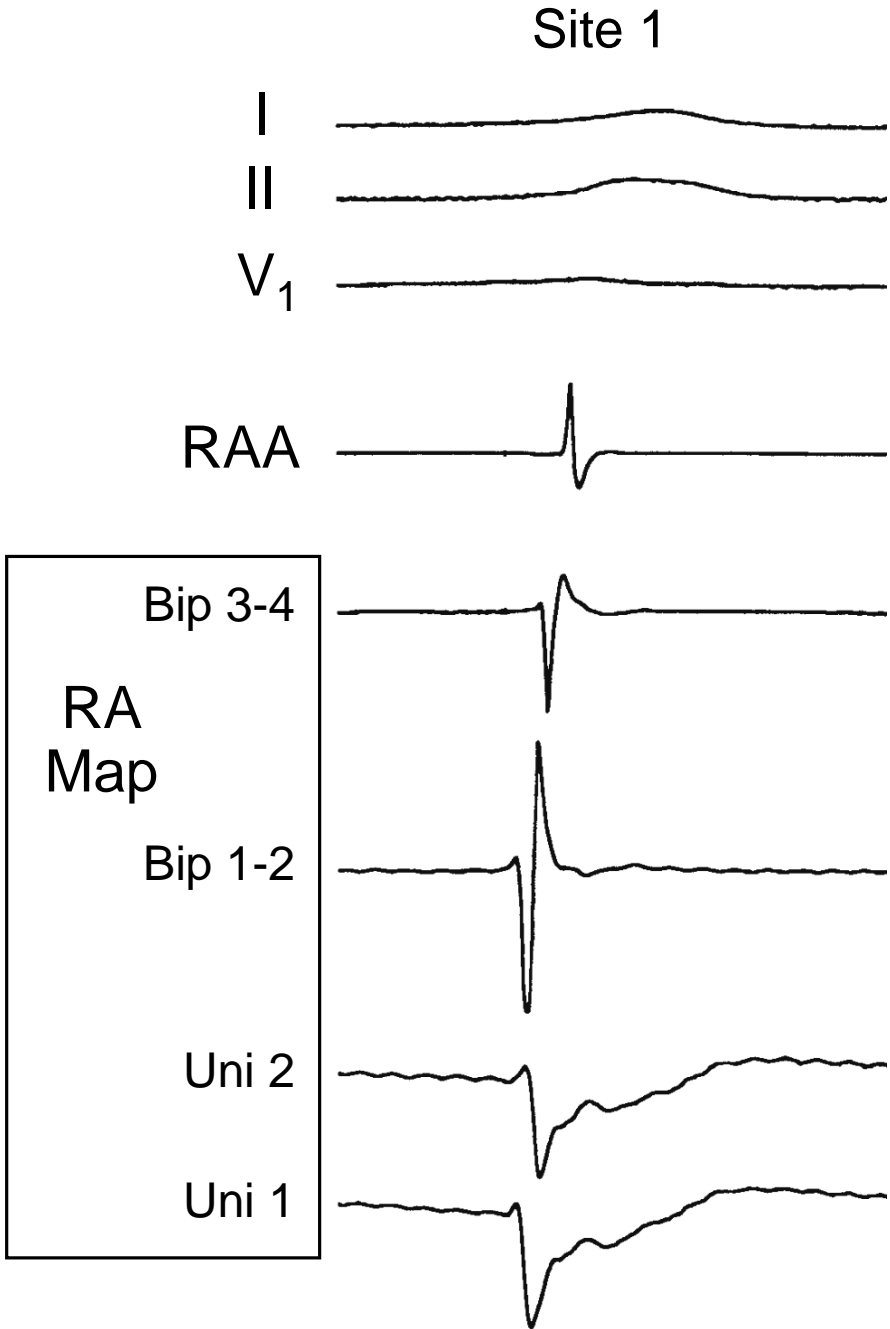
1. Activation is as Early as Earliest Far-Field Potential Recorded
 - Trigger Sweep (200 mm/s)
 - Time Line at Earliest Far-Field
2. Distal Bipolar EGM and Unipolar 1 EGM Begin Simultaneously
 - Indicates No Earlier Far-Field Activation

How do you know when you are at the *Site of Earliest Atrial Activation?*

1. Activation is as Early as Earliest Far-Field Potential Recorded
 - Trigger Sweep (200 mm/s)
 - Time Line at Earliest Far-Field
2. Distal Bipolar EGM and Unipolar 1 EGM Begin Simultaneously
 - Indicates No Earlier Far-Field Activation
3. Unipolar EGM Begins with a Steep Negative Component

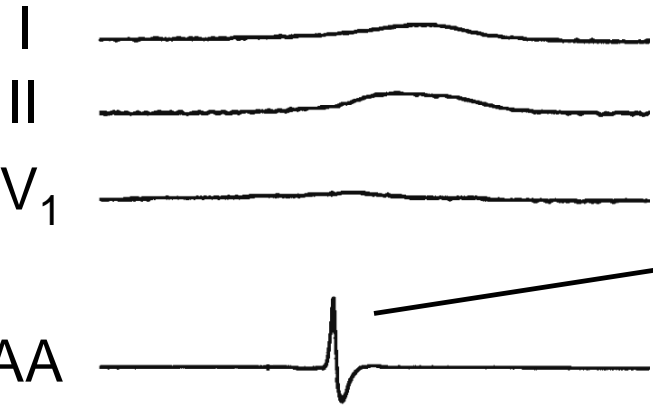
Mapping Focal
RA Tachycardia

Ablation Catheter
Electrodes

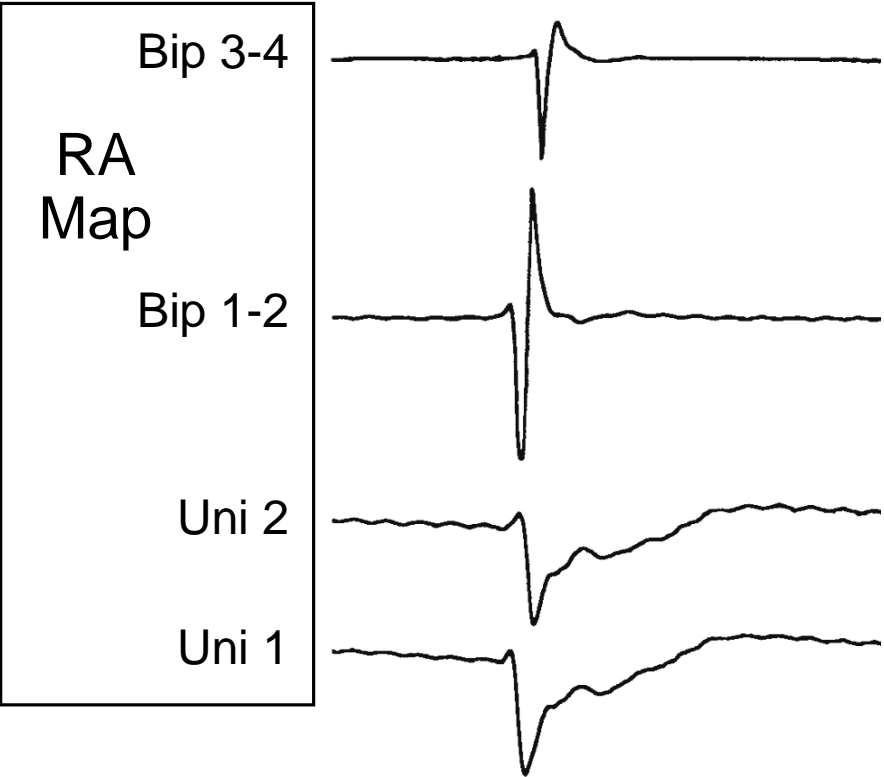


Mapping Focal
RA Tachycardia

Site 1

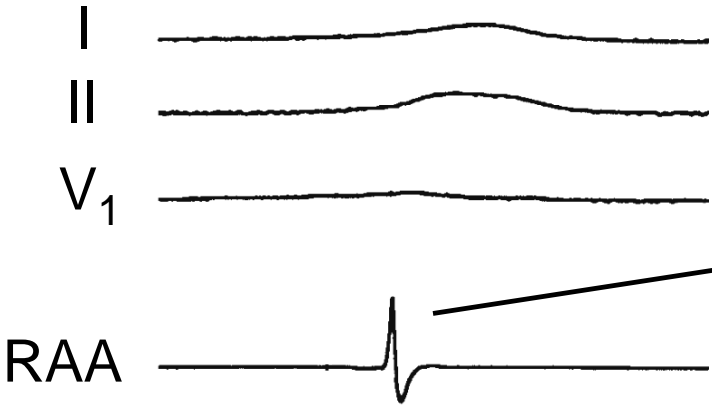


Reference Atrial
Potential (RAA)

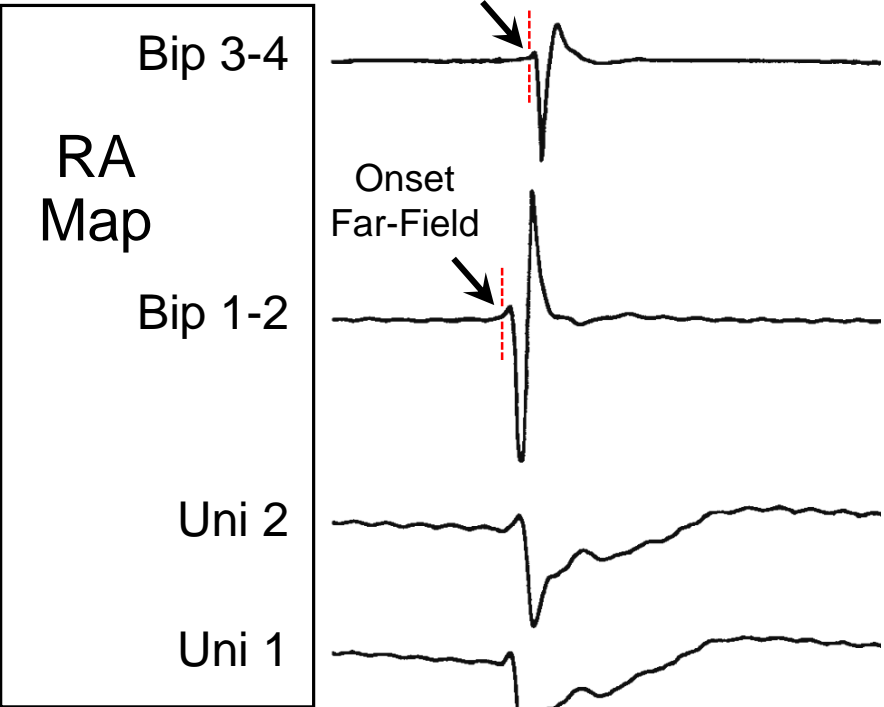


Mapping Focal
RA Tachycardia

Site 1

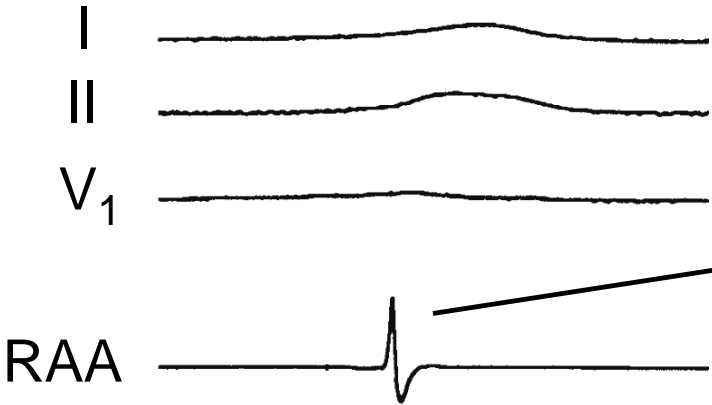


Reference Atrial
Potential (RAA)

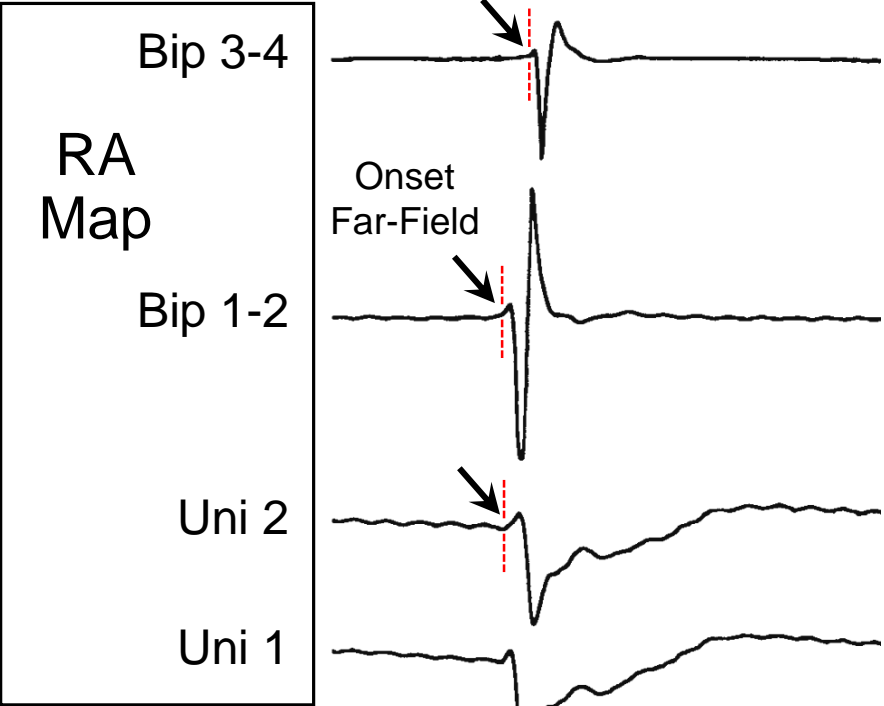


Mapping Focal
RA Tachycardia

Site 1

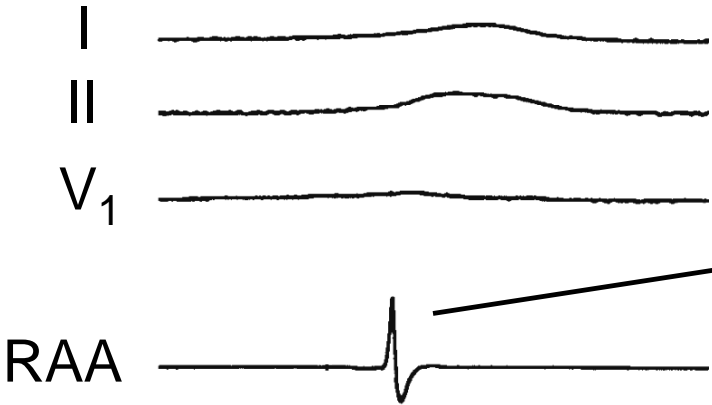


Reference Atrial
Potential (RAA)

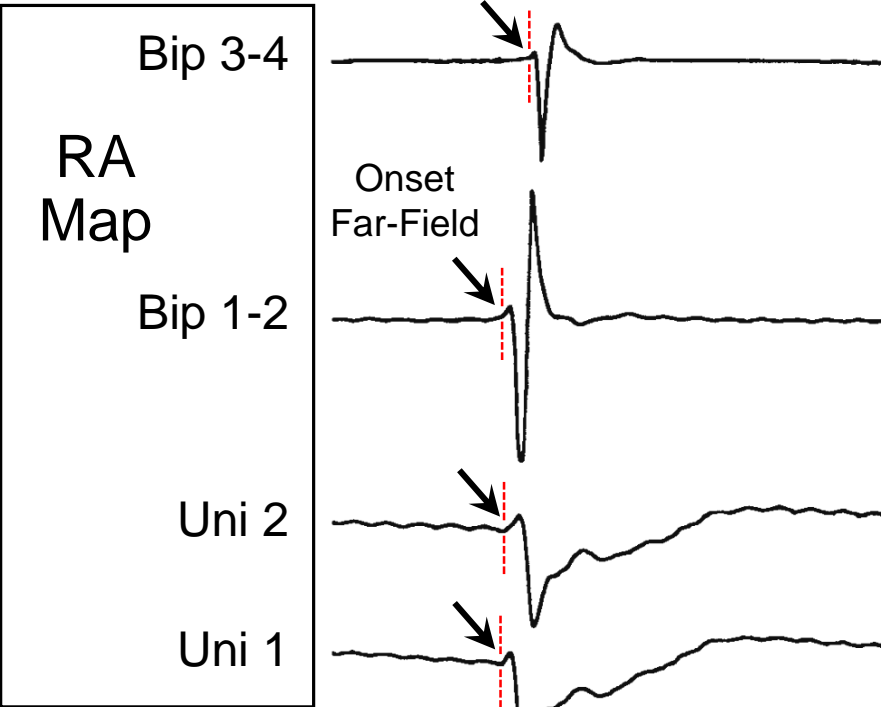


Mapping Focal
RA Tachycardia

Site 1

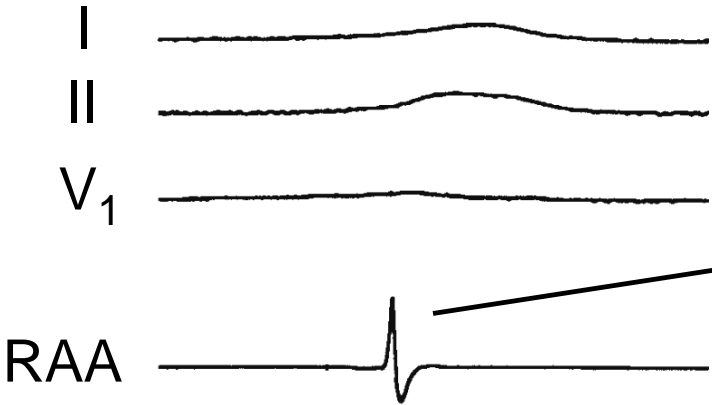


Reference Atrial
Potential (RAA)

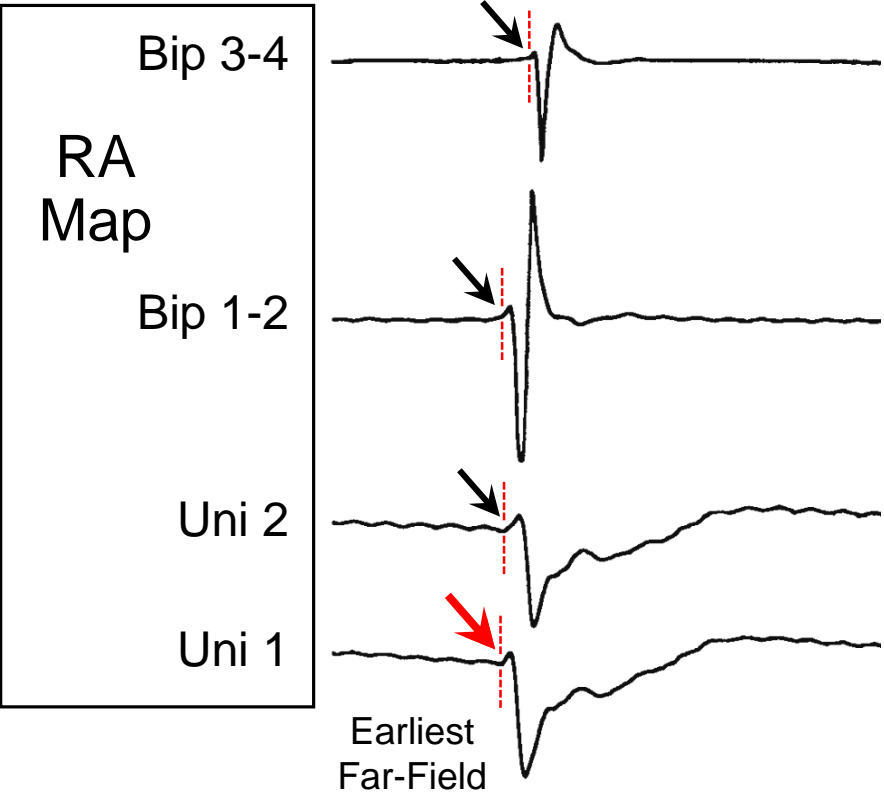


Mapping Focal
RA Tachycardia

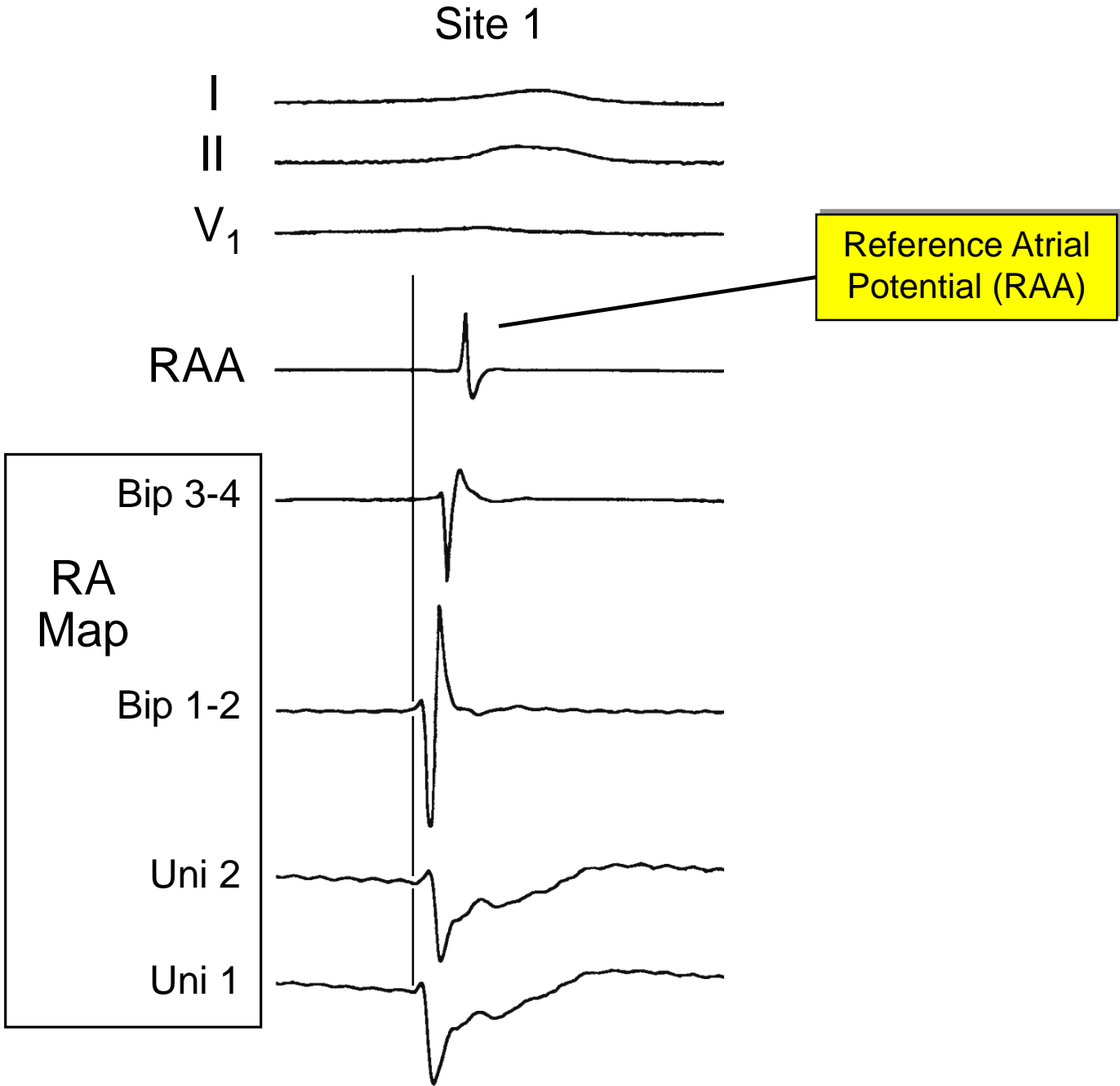
Site 1



Reference Atrial
Potential (RAA)

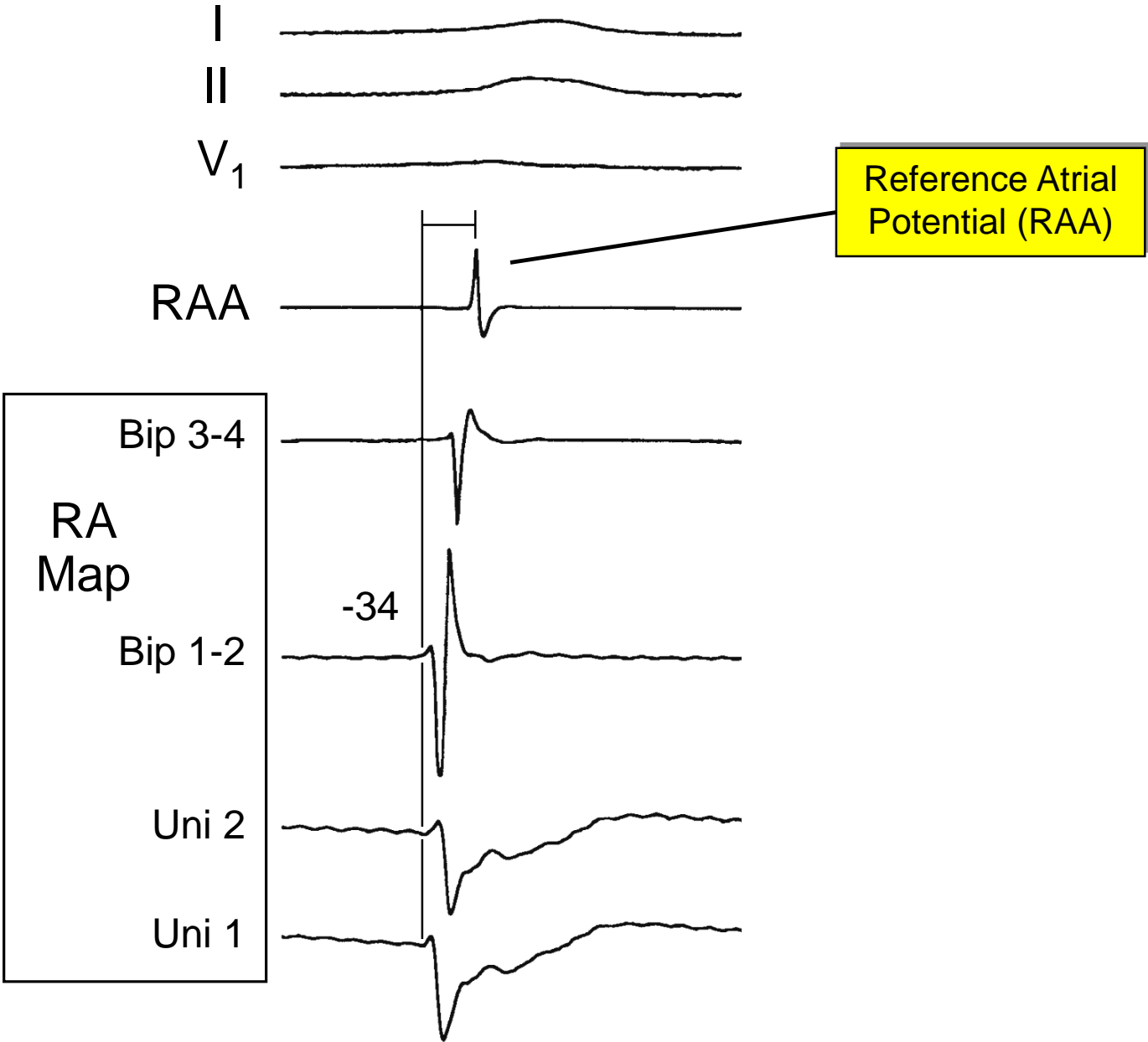


Mapping Focal
RA Tachycardia



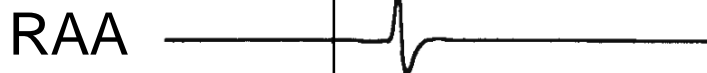
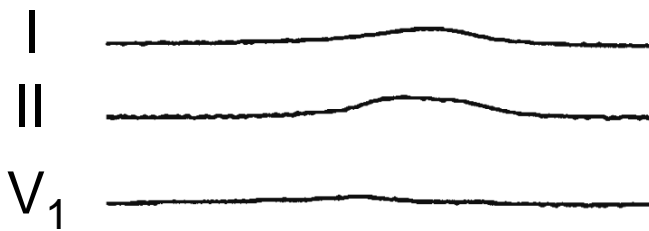
Mapping Focal
RA Tachycardia

Site 1



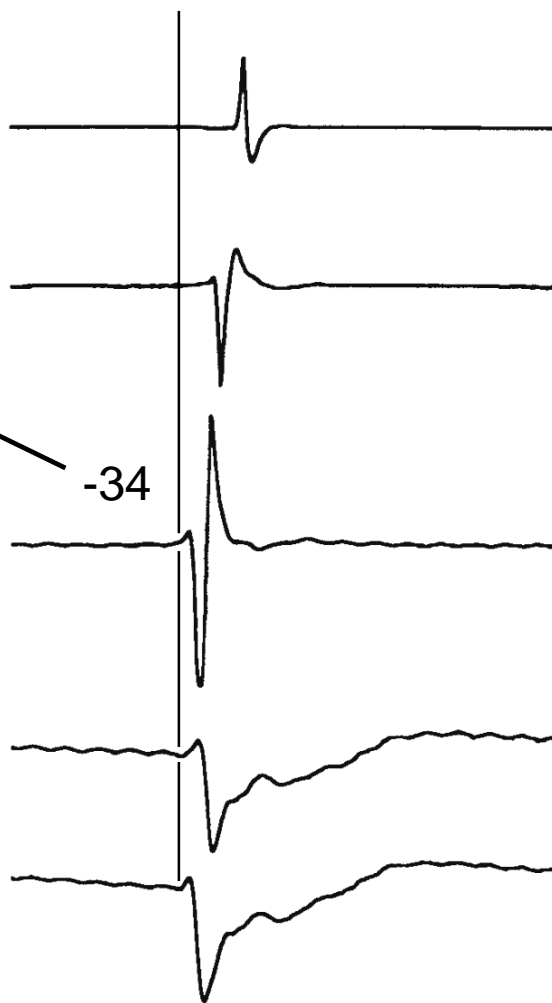Mapping Focal
RA Tachycardia

Site 1



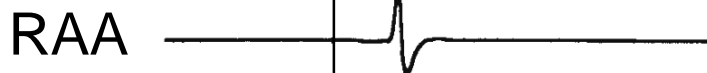
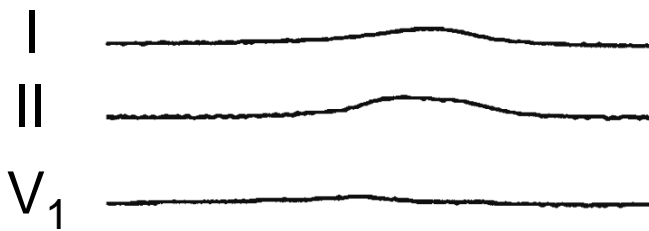
Earliest Far-Field
Activation

Bip 3-4
RA
Map
Bip 1-2
Uni 2
Uni 1



Mapping Focal
RA Tachycardia

Site 1

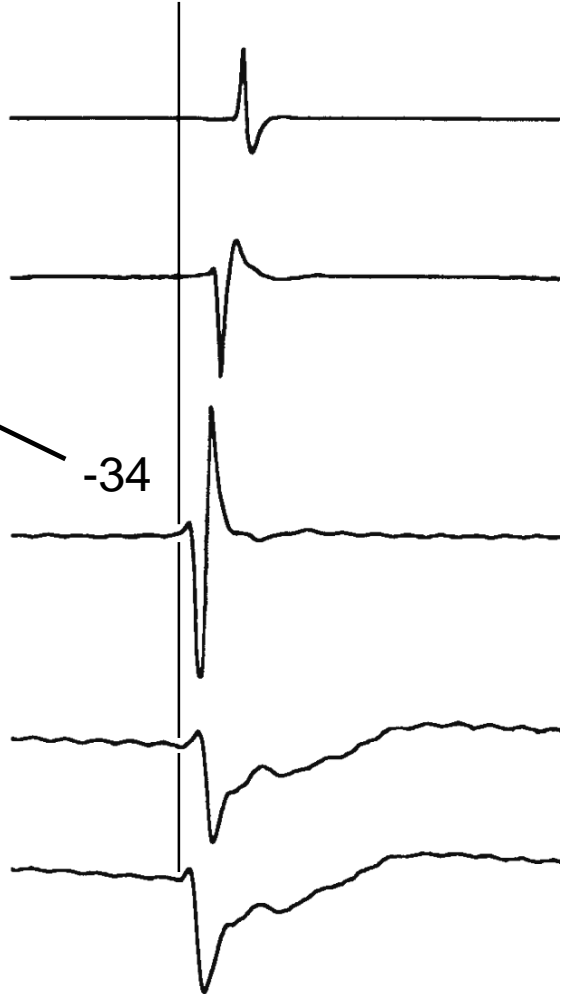


Earliest Far-Field
Activation

Bip 3-4
RA
Map
Bip 1-2
Uni 2
Uni 1

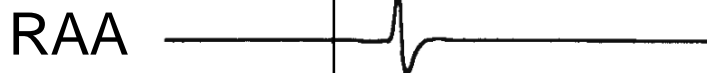
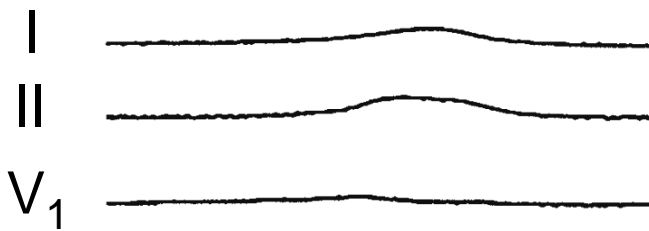
-34

Local Activation
Time



Mapping Focal
RA Tachycardia

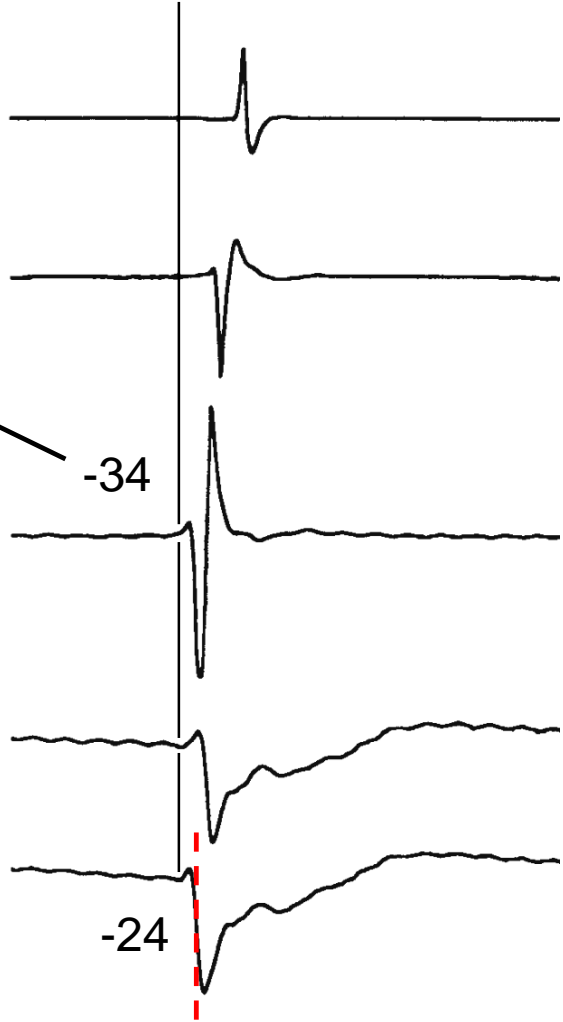
Site 1



Earliest Far-Field
Activation

Bip 3-4
RA
Map
Bip 1-2
Uni 2
Uni 1

Local Activation
Time


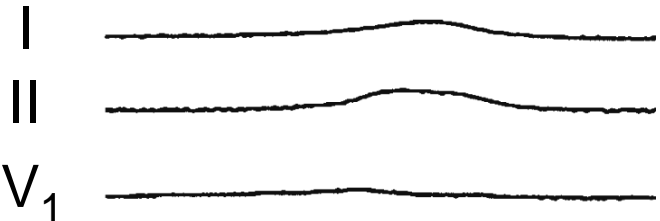


-34

-24

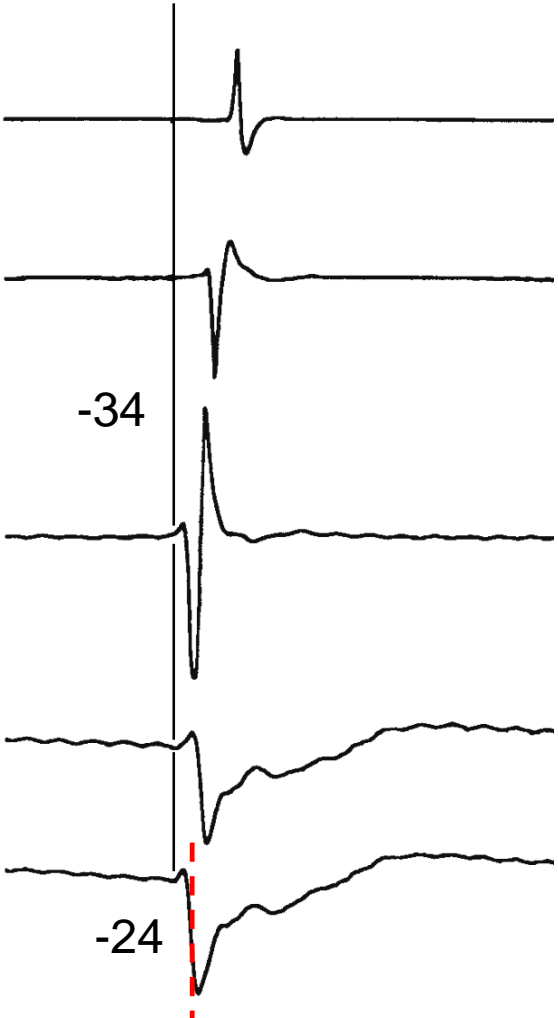
Mapping Focal
RA Tachycardia

Site 1

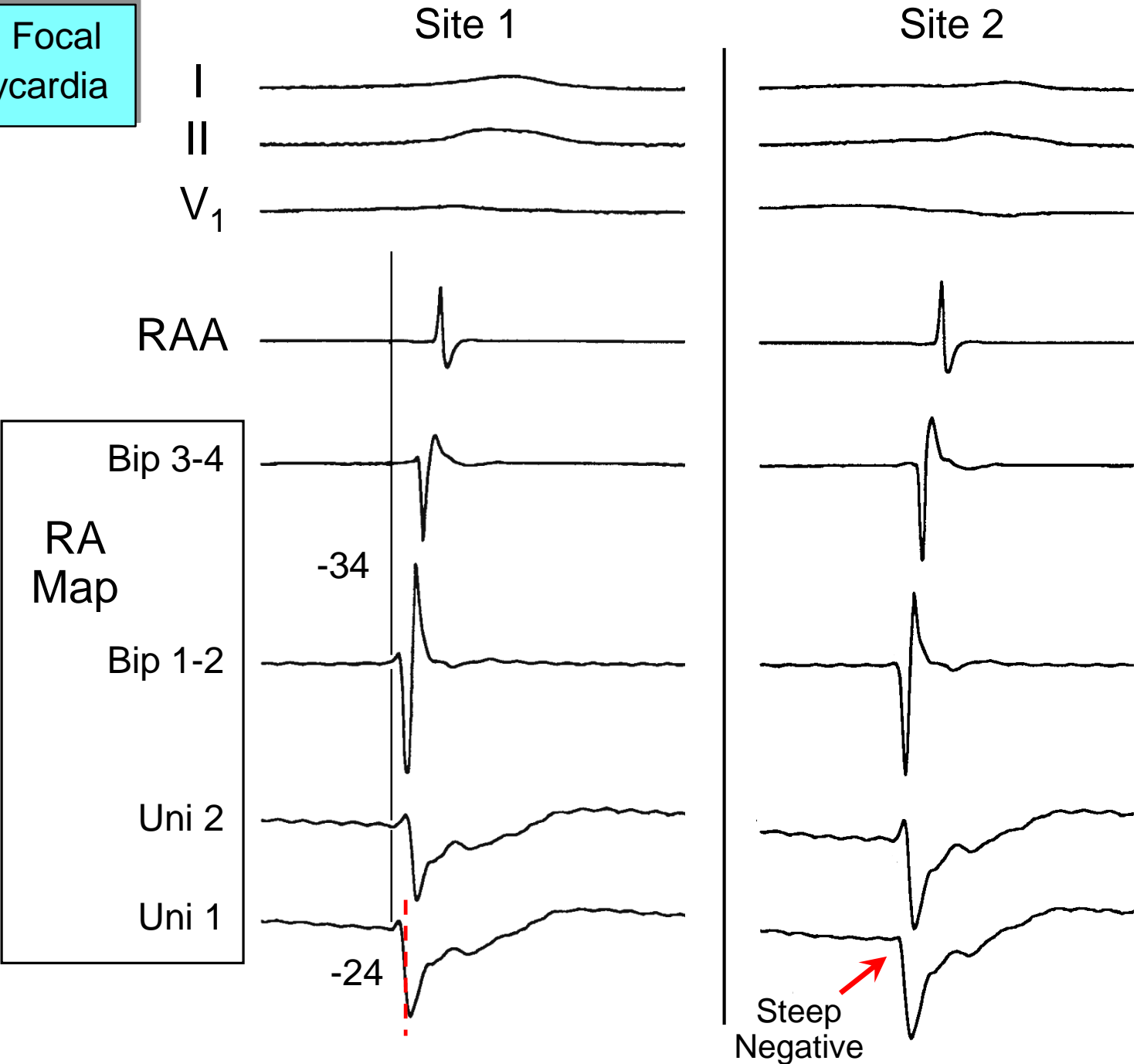


RA
Map

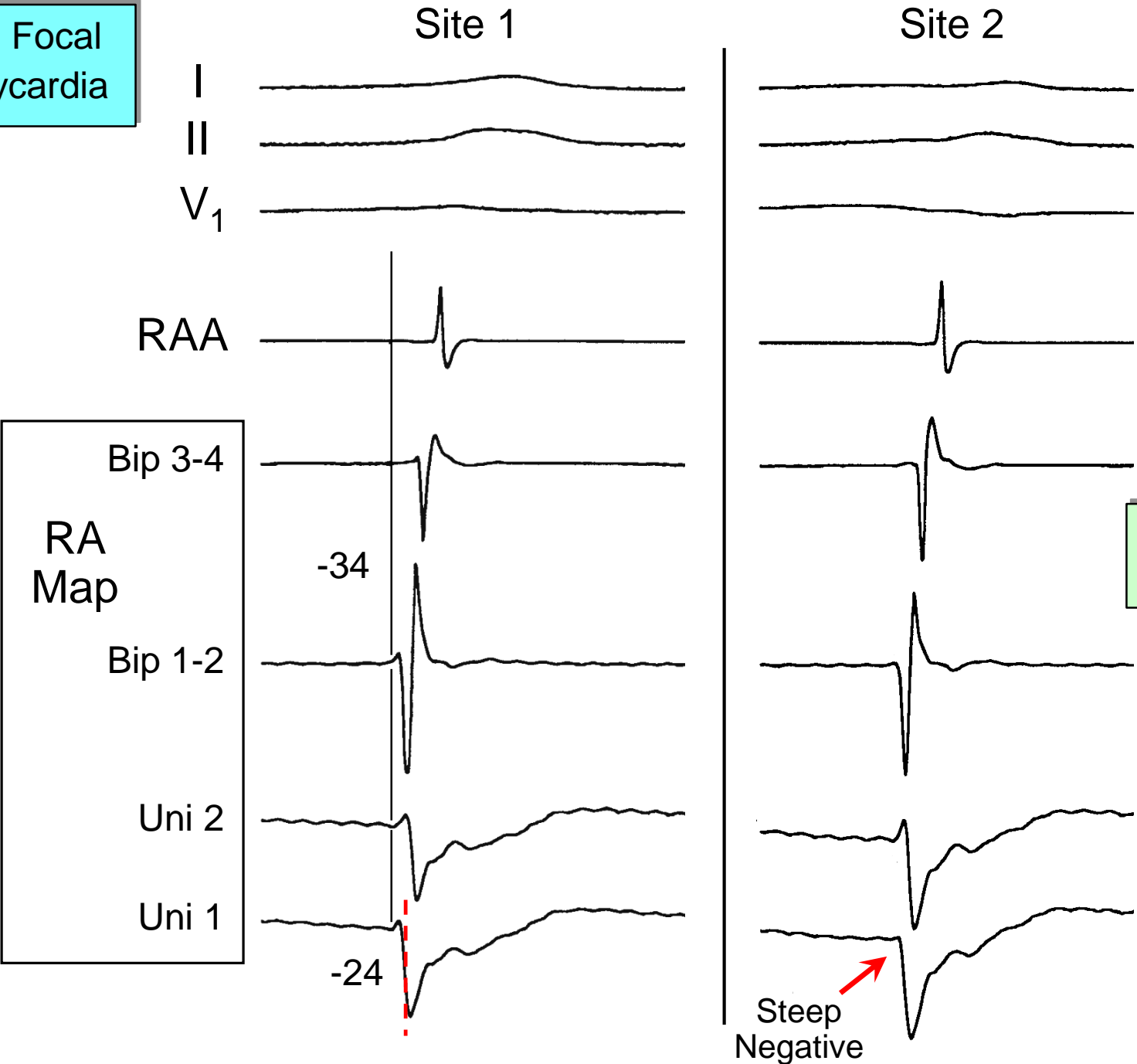
Bip 3-4
Bip 1-2
Uni 2
Uni 1



Mapping Focal RA Tachycardia



Mapping Focal RA Tachycardia




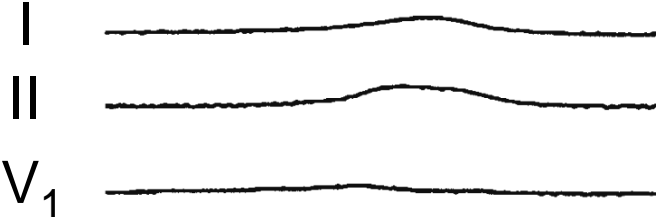
Ablate Here?

Steep Negative

Mapping Focal RA Tachycardia

Site 1

Site 2



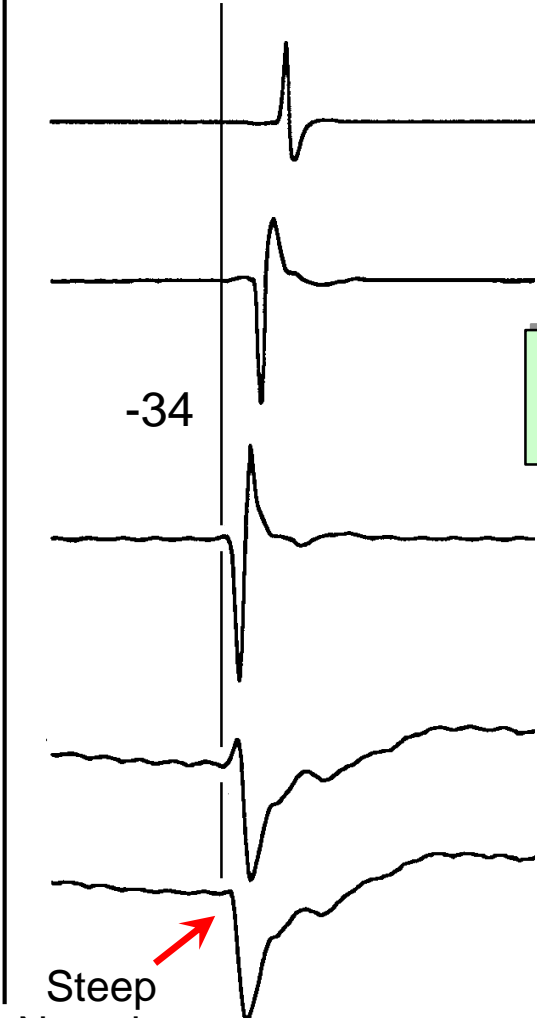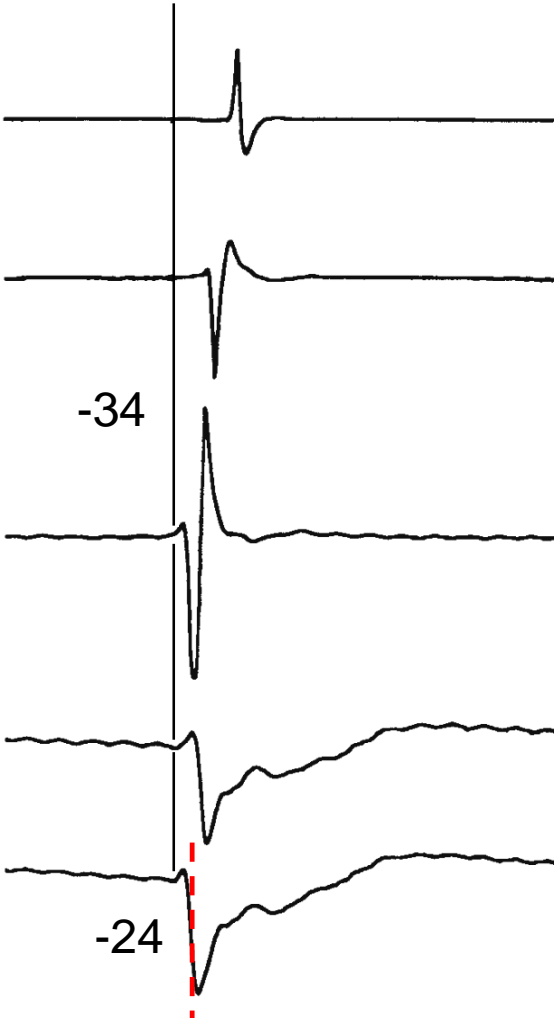
RA Map

Bip 3-4

Bip 1-2

Uni 2

Uni 1



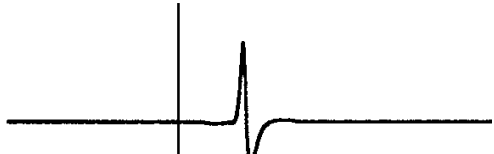

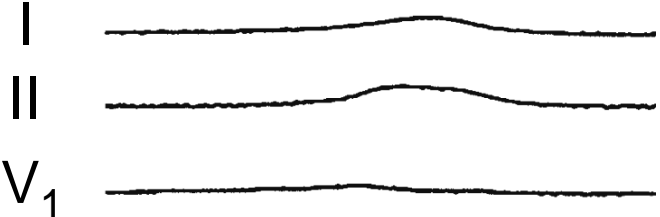
Ablate Here?

Steep Negative

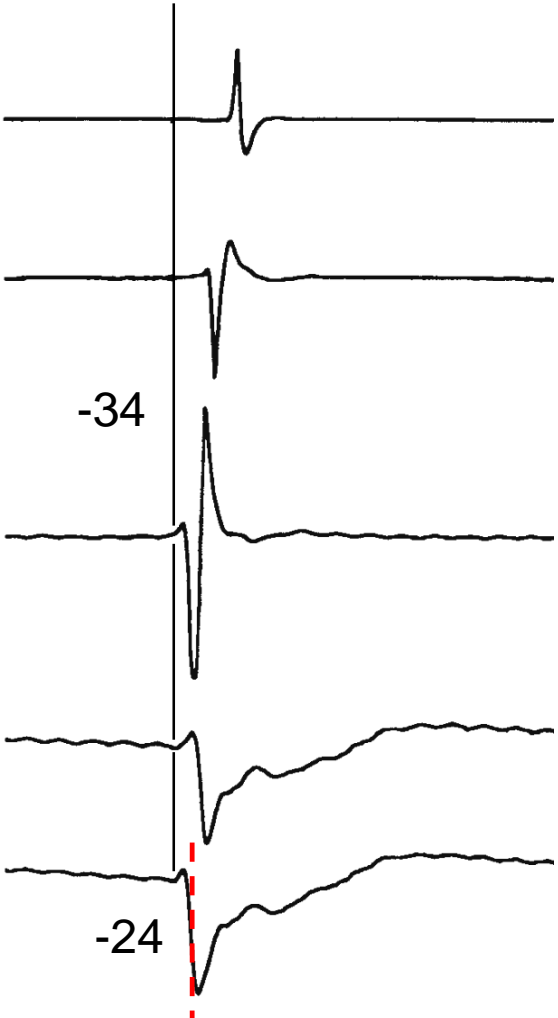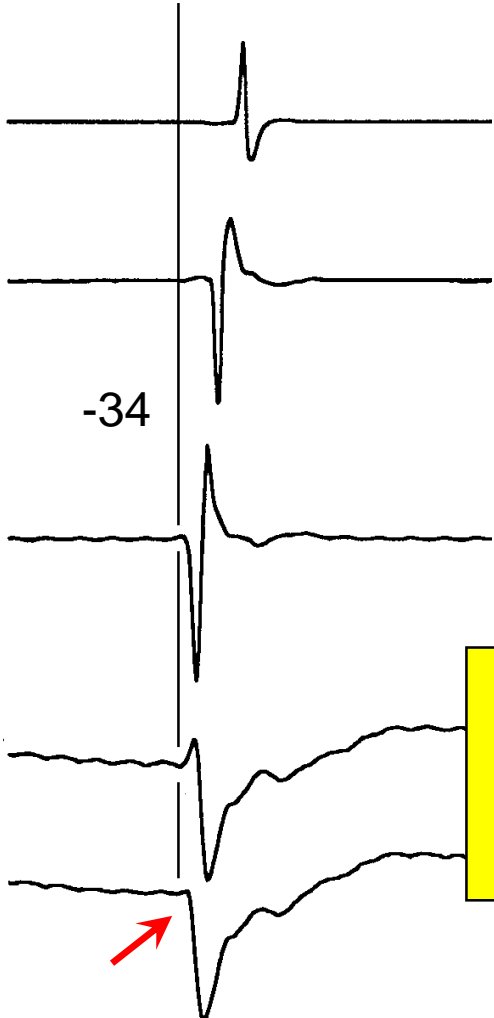
Mapping Focal RA Tachycardia

Site 1

Site 2

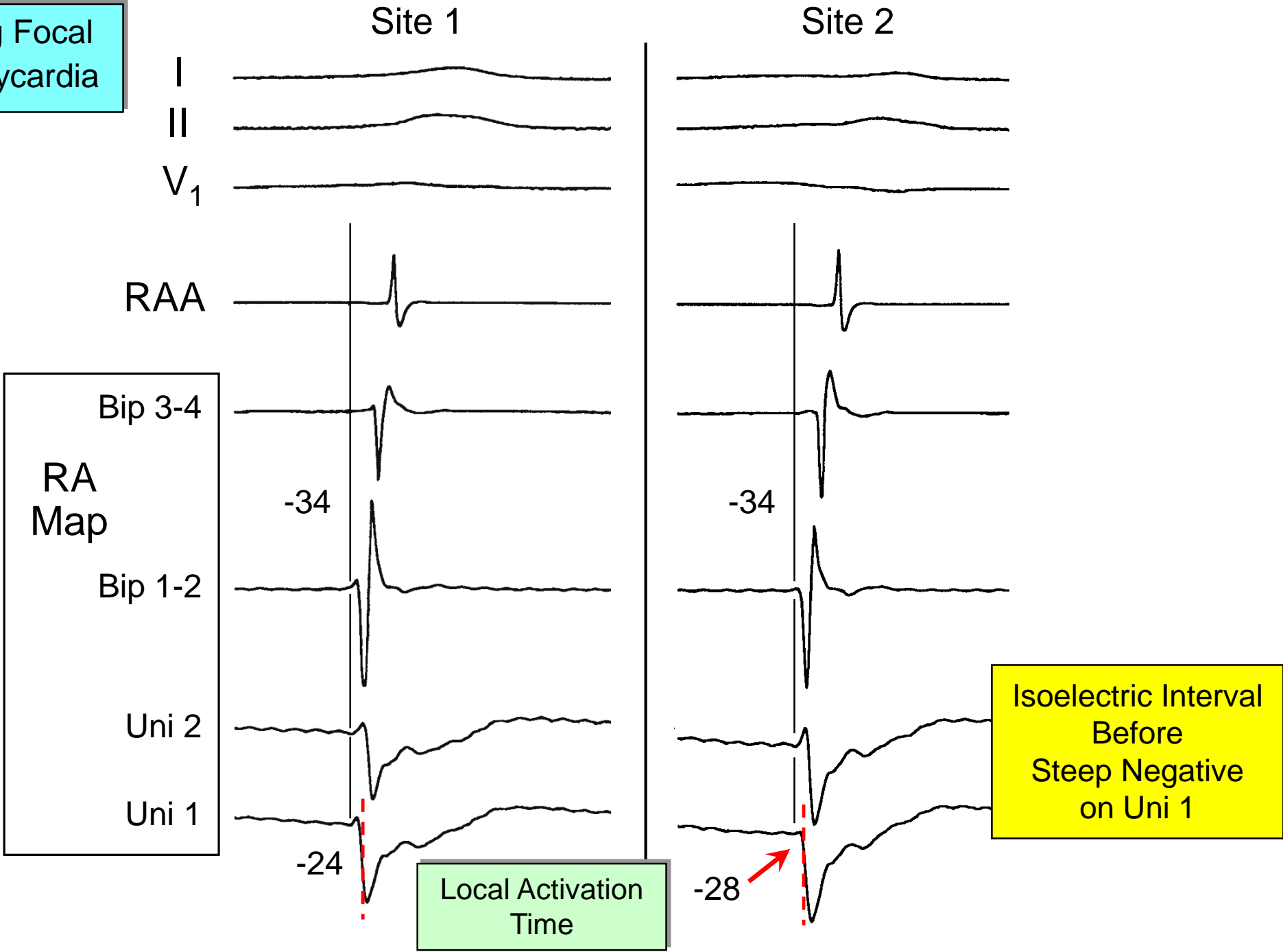


Bip 3-4
RA Map
Bip 1-2
Uni 2
Uni 1

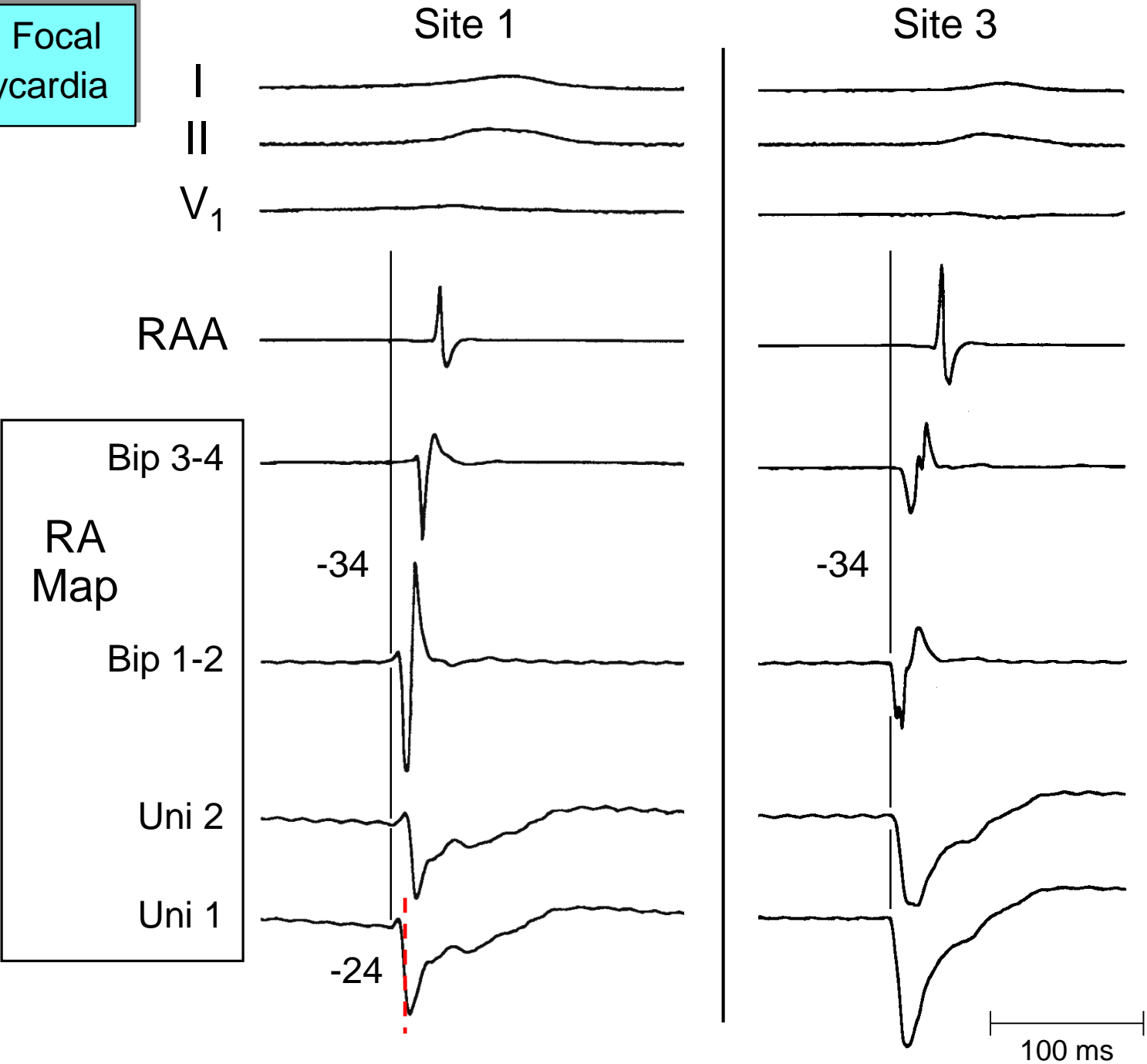


Isoelectric Interval Before Steep Negative on Uni 1

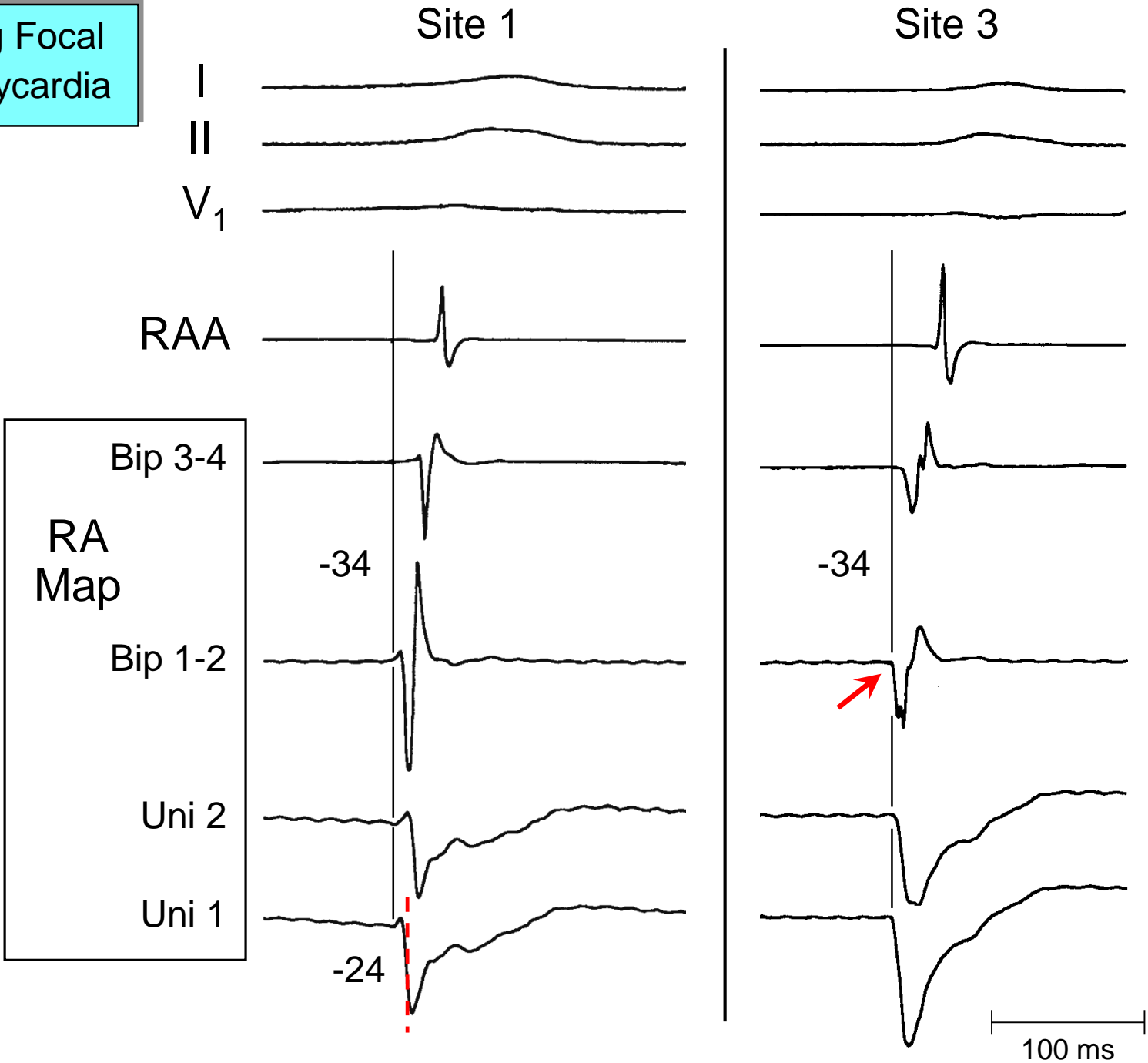
Mapping Focal RA Tachycardia



Mapping Focal RA Tachycardia




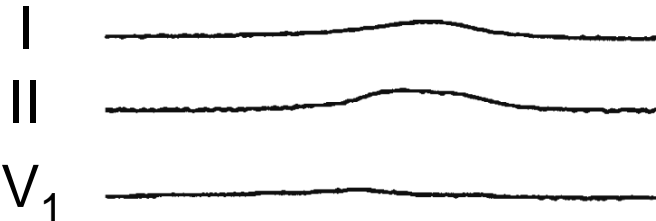
Mapping Focal
RA Tachycardia



Mapping Focal RA Tachycardia

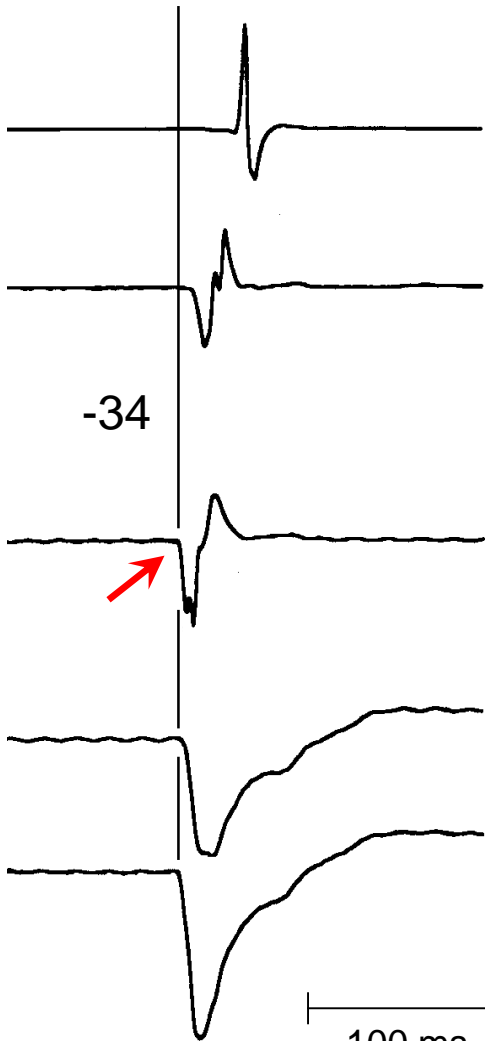
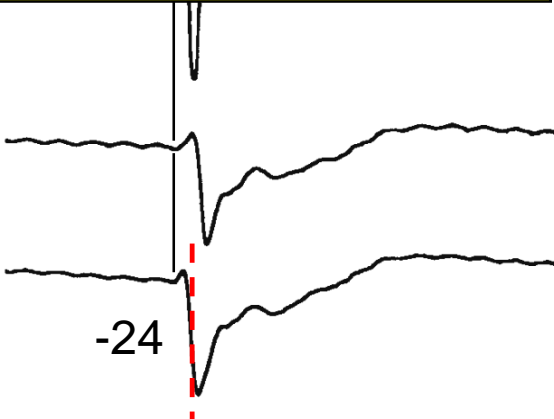
Site 1

Site 3



1. Activation Simultaneous with Earliest Far-Field Activation

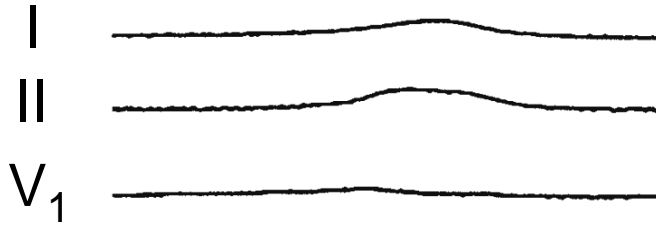
R
Ma
Uni 2
Uni 1




100 ms

Mapping Focal
RA Tachycardia

Site 1



Site 3



1. Activation Simultaneous with Earliest Far-Field Activation
2. Bipolar and Unipolar EGMs Begin Simultaneously (No Earlier Far-Field Activ)

R
Ma

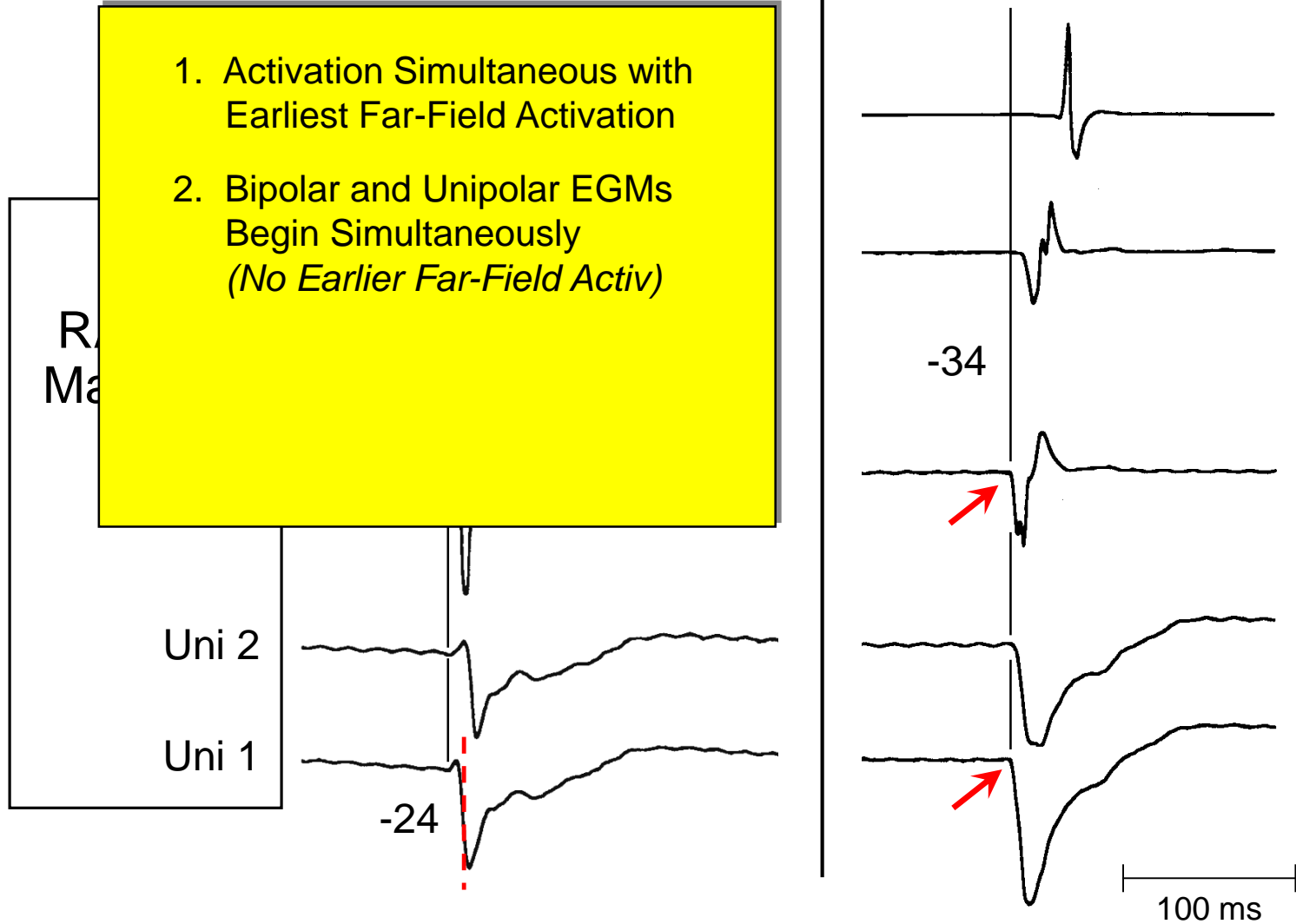
Uni 2

Uni 1

-24

-34


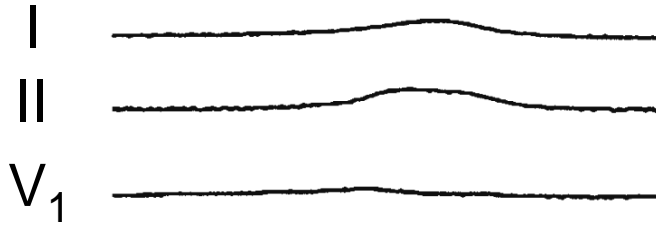
100 ms



Mapping Focal
RA Tachycardia

Site 1

Site 3



1. Activation Simultaneous with Earliest Far-Field Activation
2. Bipolar and Unipolar EGMs Begin Simultaneously (No Earlier Far-Field Activ)
3. Unipolar EGM Begins with a Steep Negative Component

R
Ma

Uni 2

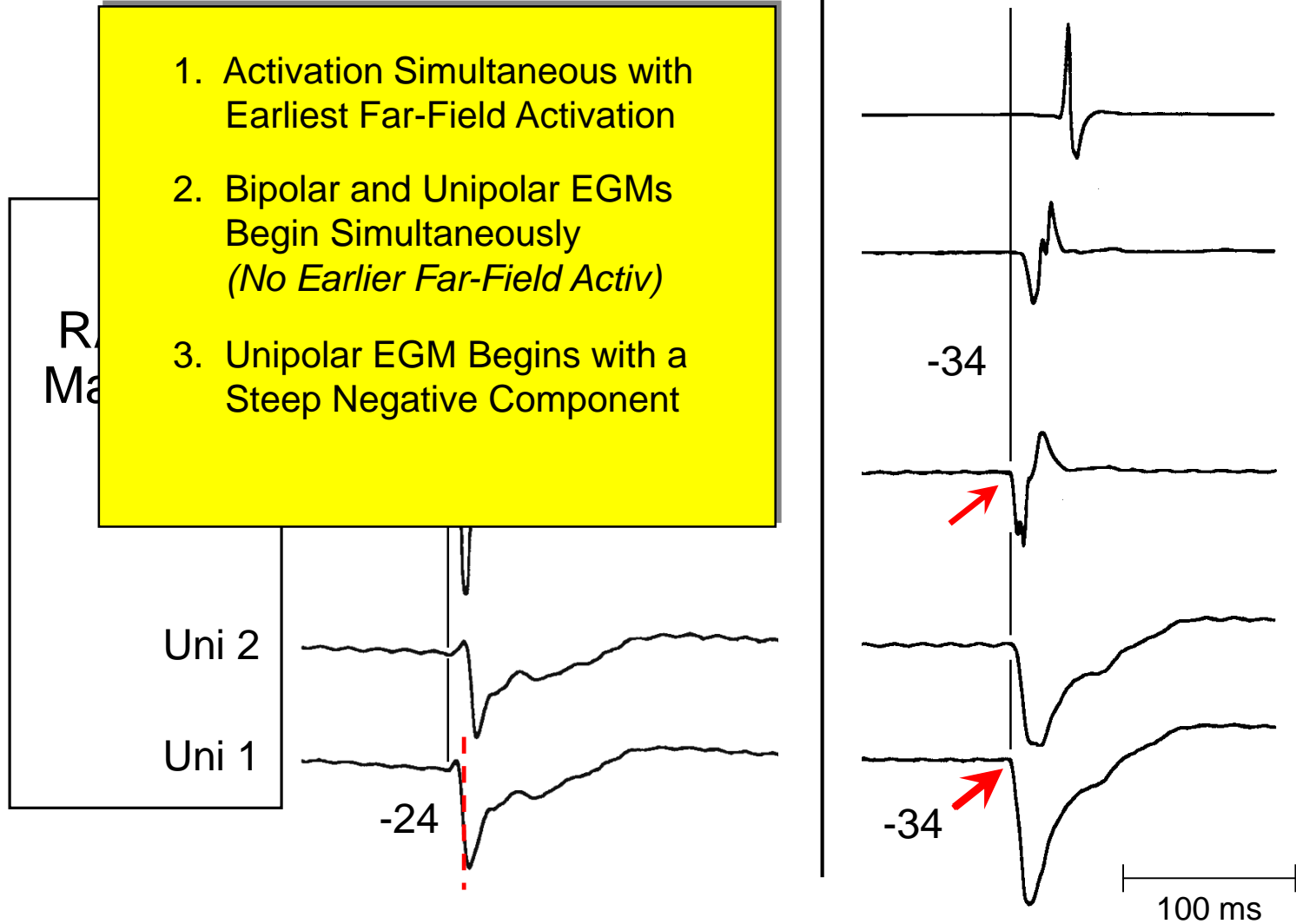
Uni 1

-24

-34

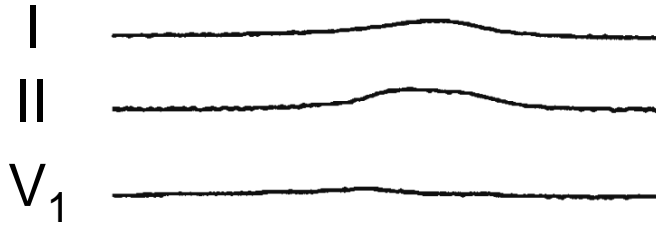
-34

100 ms




Mapping Focal
RA Tachycardia

Site 1



Site 3



1. Activation Simultaneous with Earliest Far-Field Activation
2. Bipolar and Unipolar EGMs Begin Simultaneously (No Earlier Far-Field Activ)
3. Unipolar EGM Begins with a Steep Negative Component

Site of Earliest Atrial Activation

R
Ma

Uni 2

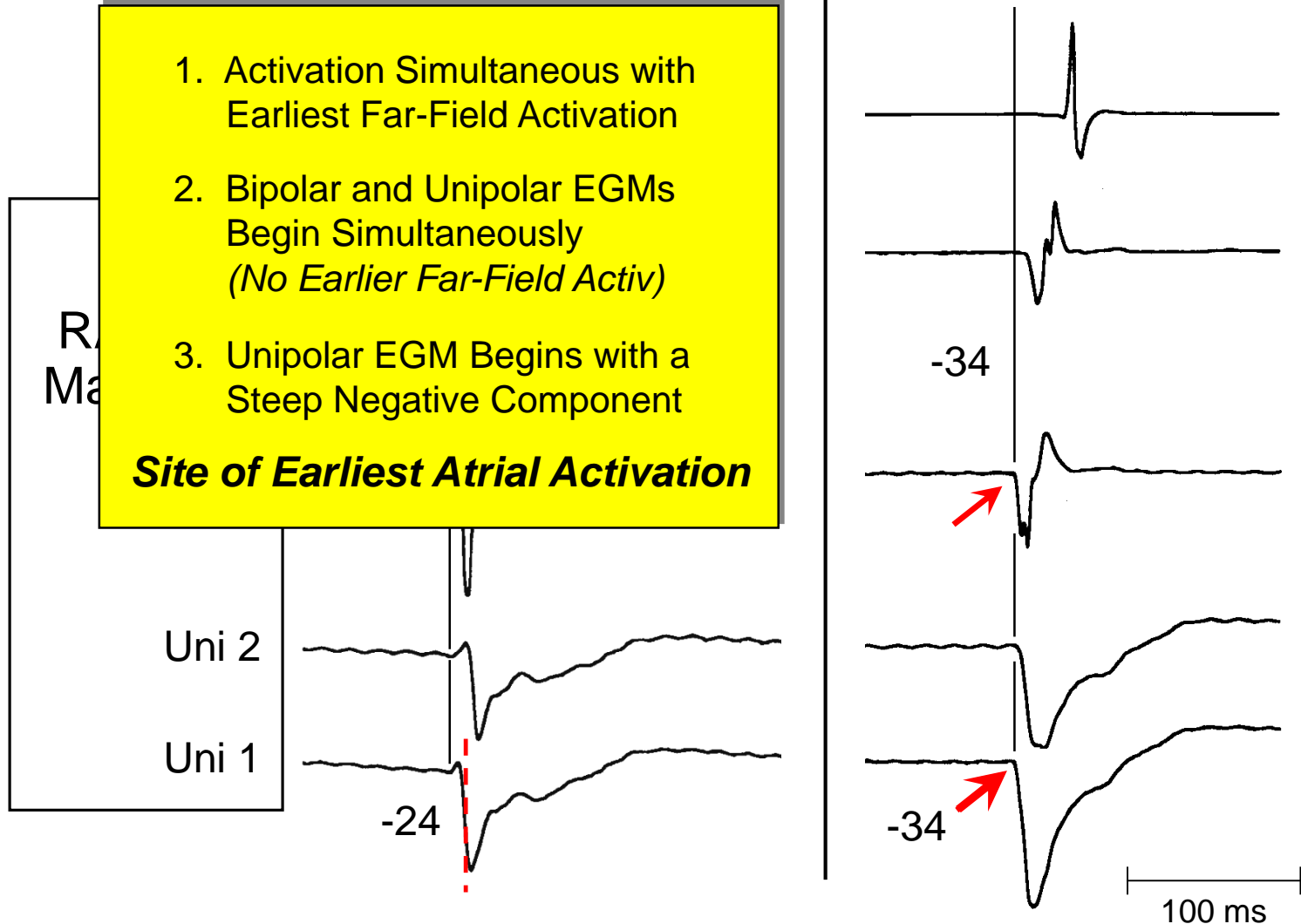
Uni 1

-24

-34

-34

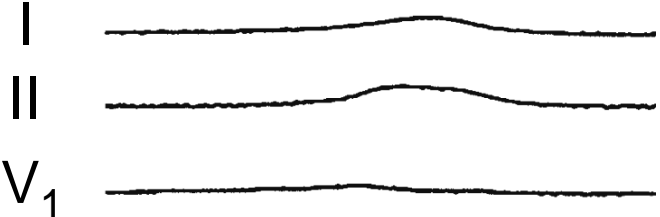
100 ms



Mapping Focal RA Tachycardia

Site 1

Site 3

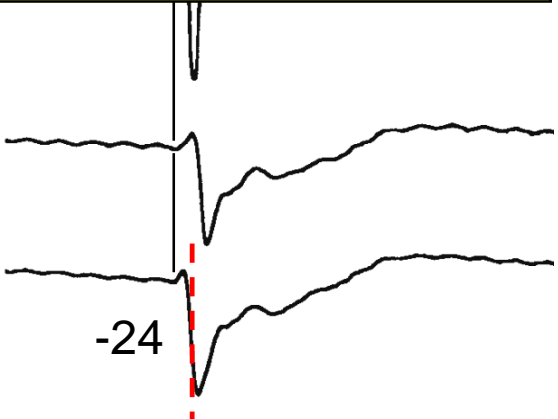


1. Activation Simultaneous with Earliest Far-Field Activation
 2. Bipolar and Unipolar EGMs Begin Simultaneously (No Earlier Far-Field Activ)
 3. Unipolar EGM Begins with a Steep Negative Component
- Site of Earliest Atrial Activation**

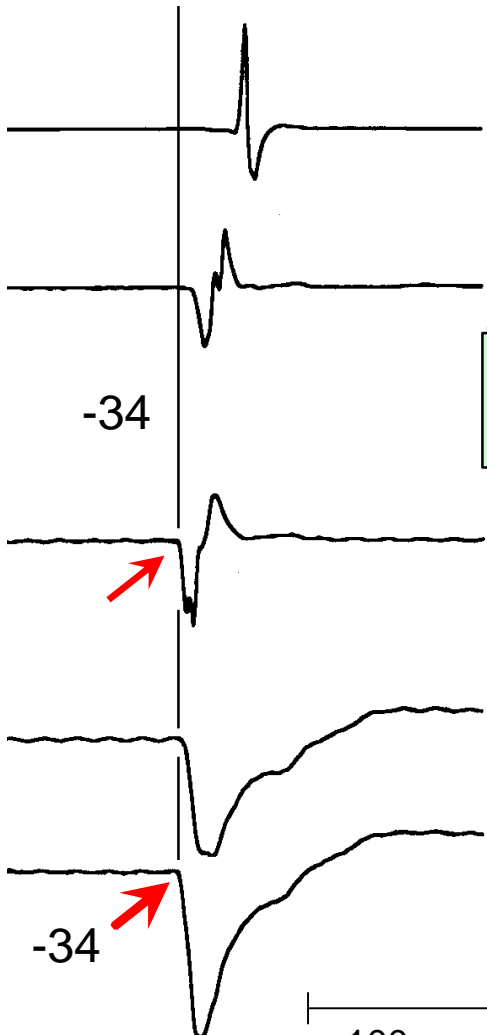R
Ma

Uni 2

Uni 1



-24



-34


-34

100 ms


Ablate Here?

Mapping Focal
RA Tachycardia

Site 1



Site 3



1. Activation Simultaneous with Earliest Far-Field Activation
2. Bipolar and Unipolar EGMs Begin Simultaneously (No Earlier Far-Field Activ)
3. Unipolar EGM Begins with a Steep Negative Component

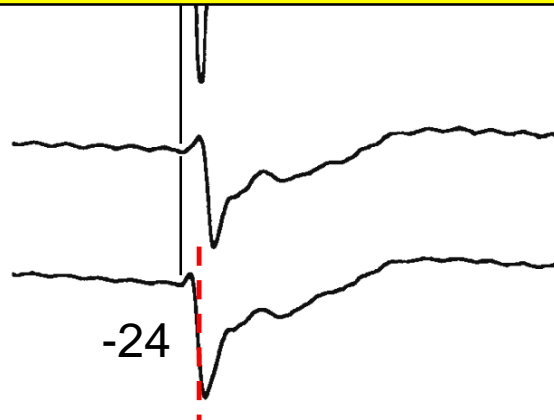
Site of Earliest Atrial Activation

R
Ma

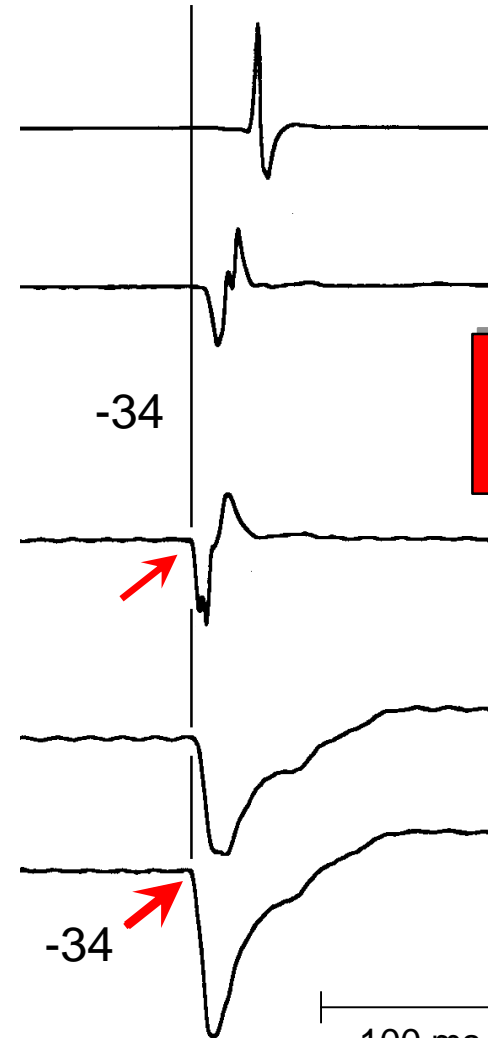
Uni 2

Uni 1

-24



-34



RF #1
Instant Success

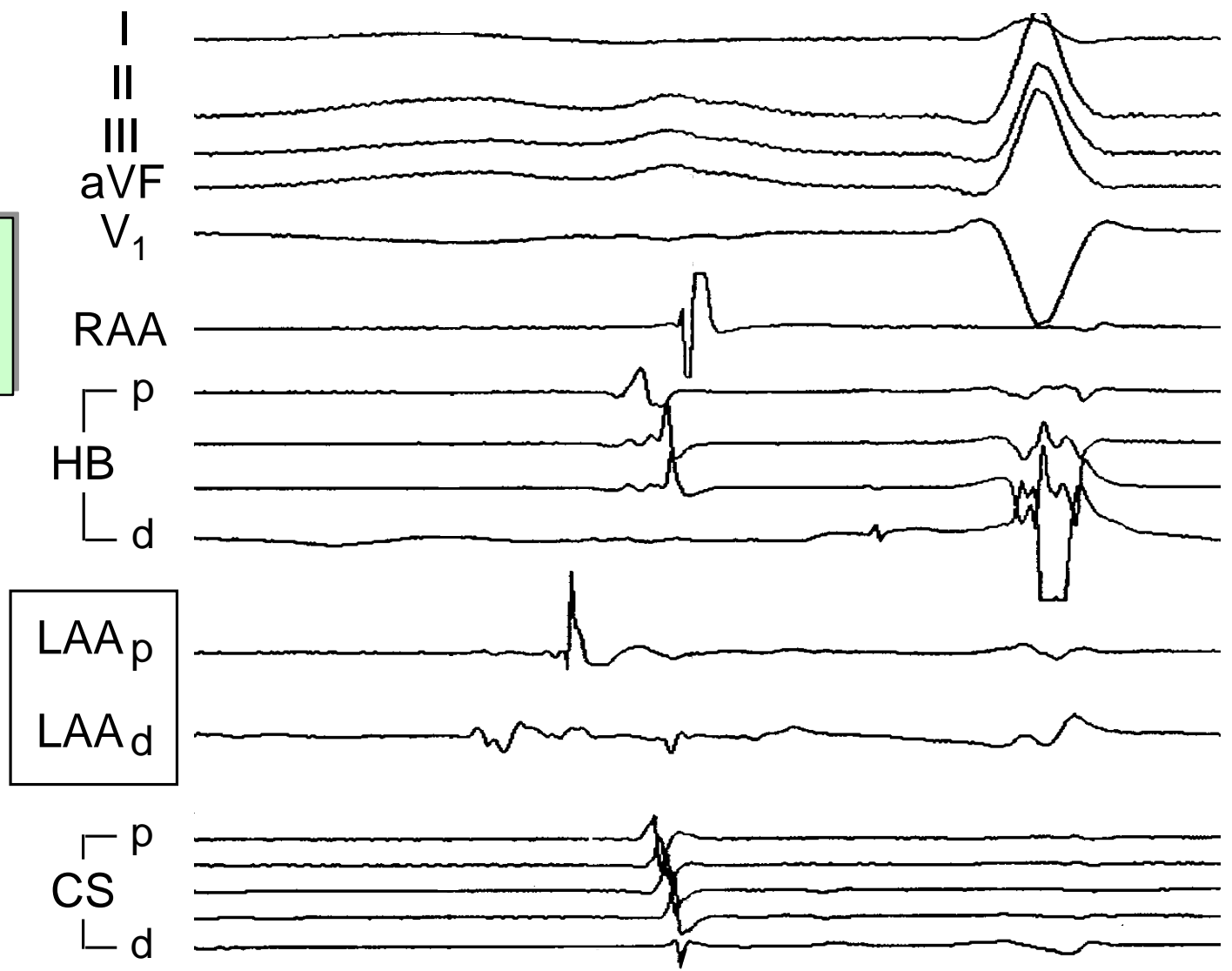
-34

100 ms

Mapping Left Atrial Tachycardia

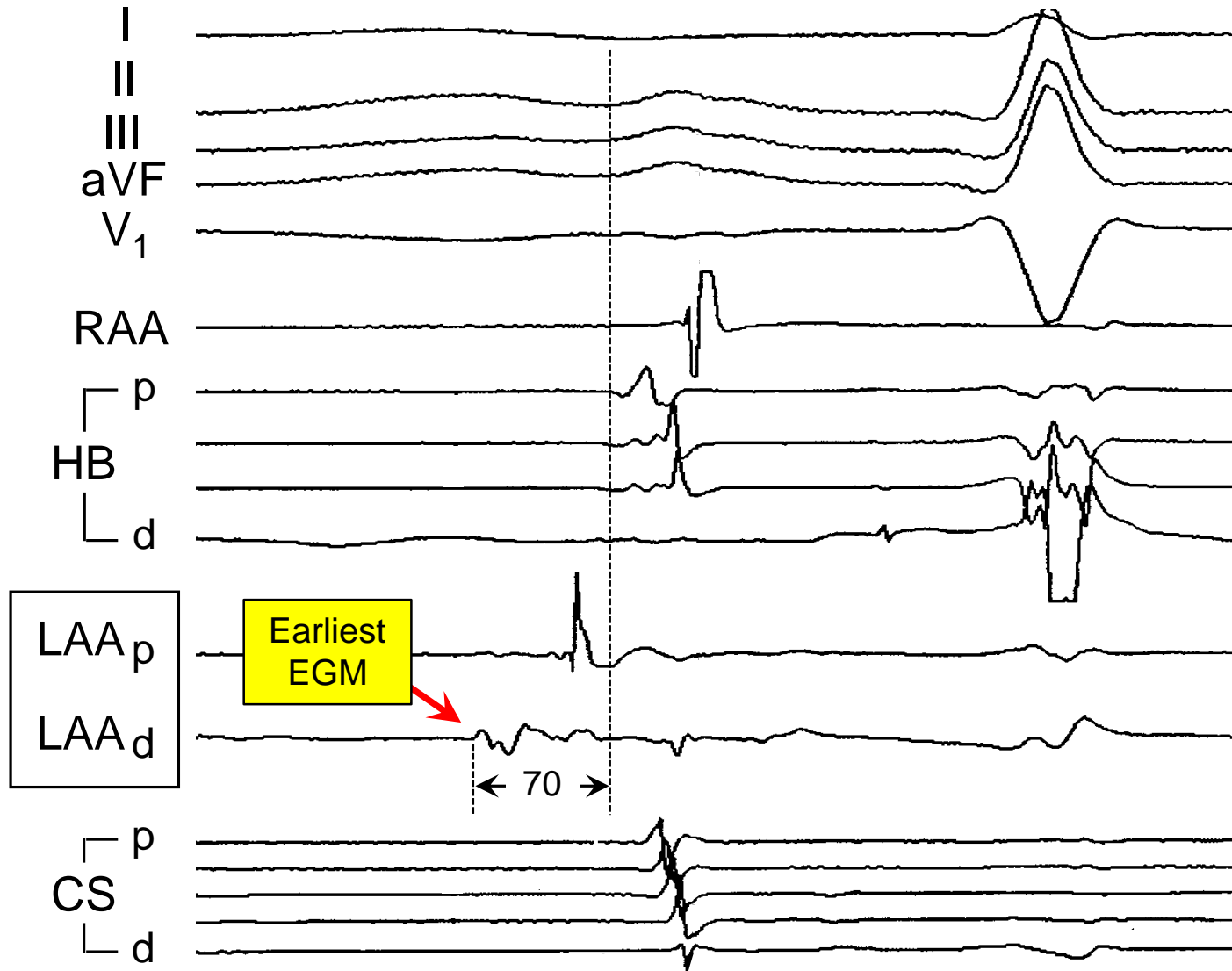
37 M, LAA Tach
2 Prior Failed Ablations

Electroanatomical
Map Using
Ablation Catheter



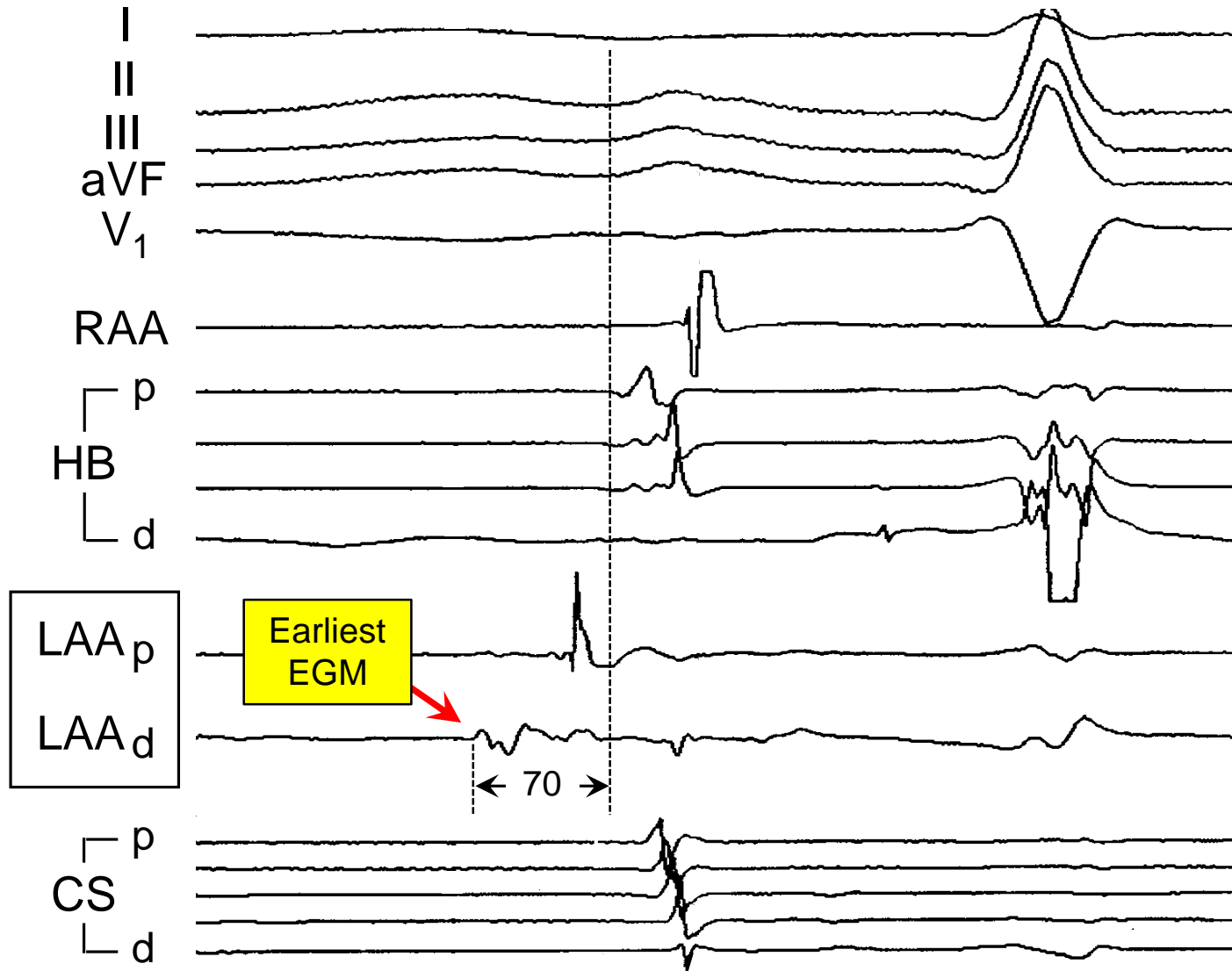
37 M, LAA Tach
2 Prior Failed
Ablations

Mapping Left Atrial Tachycardia



37 M, LAA Tach
2 Prior Failed
Ablations

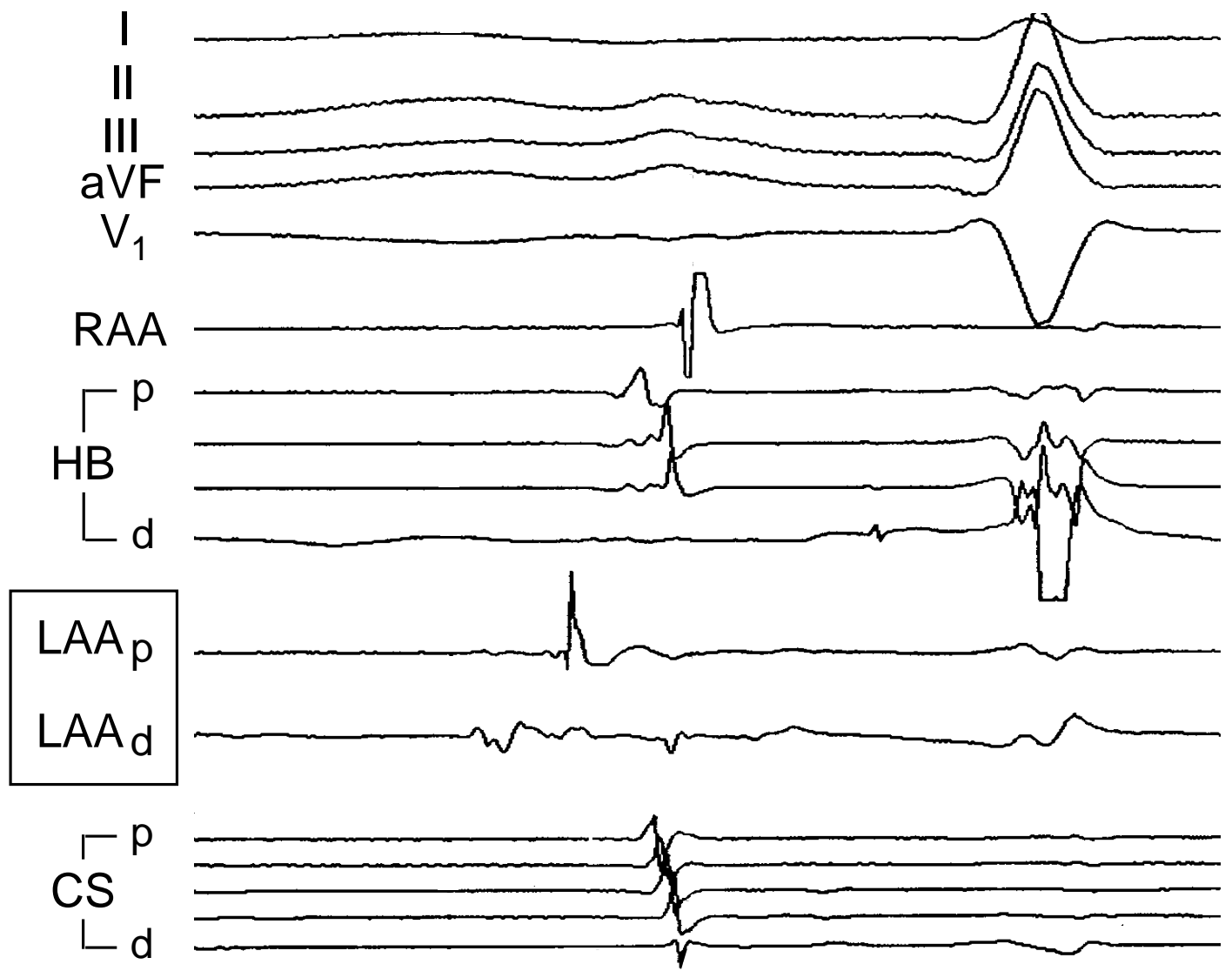
Mapping Left Atrial Tachycardia



Ablate
Here?

Mapping Left Atrial Tachycardia

37 M, LAA Tach
2 Prior Failed Ablations

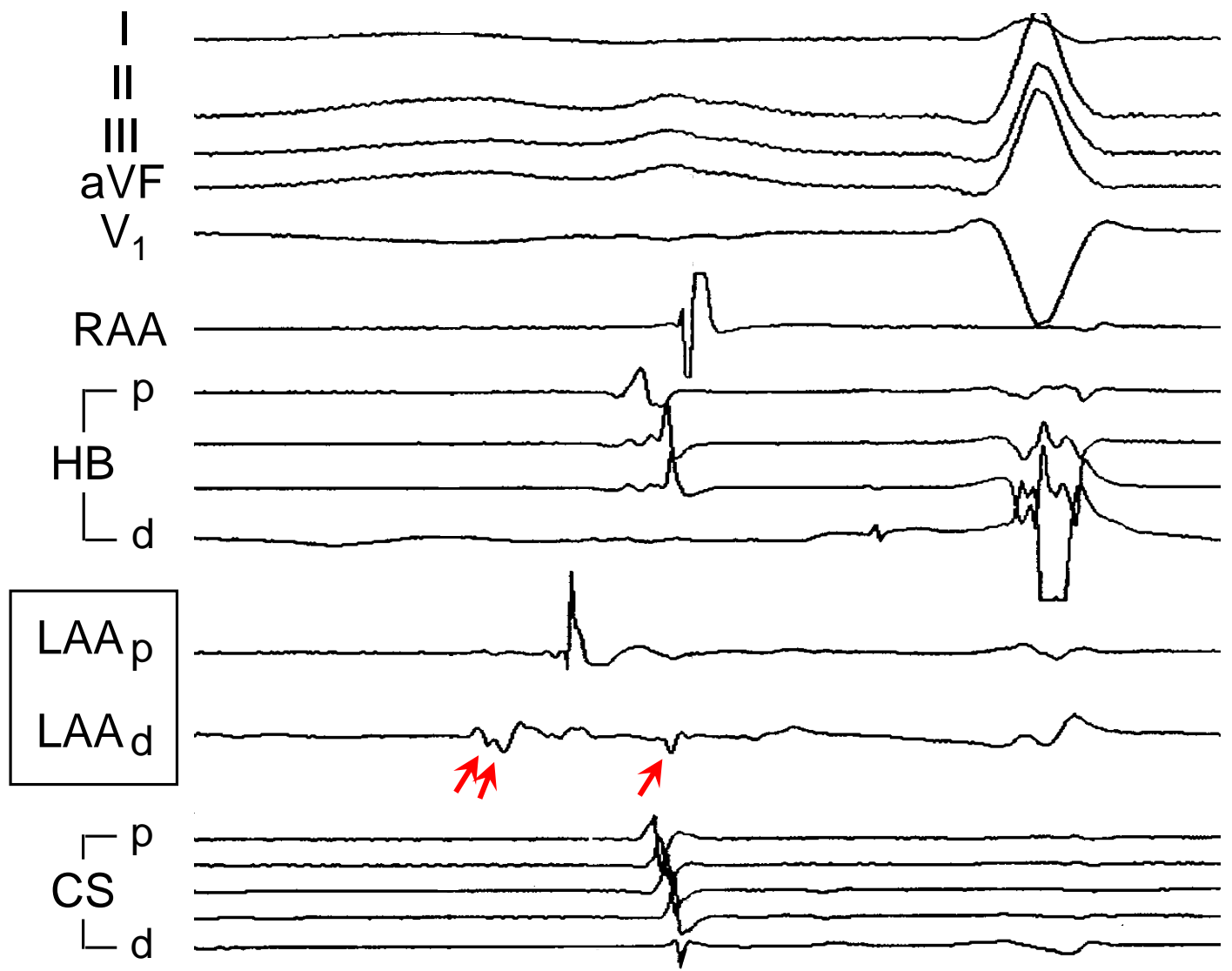


What is the timing of Local Atrial Activation?

Mapping Left Atrial Tachycardia

37 M, LAA Tach
2 Prior Failed Ablations

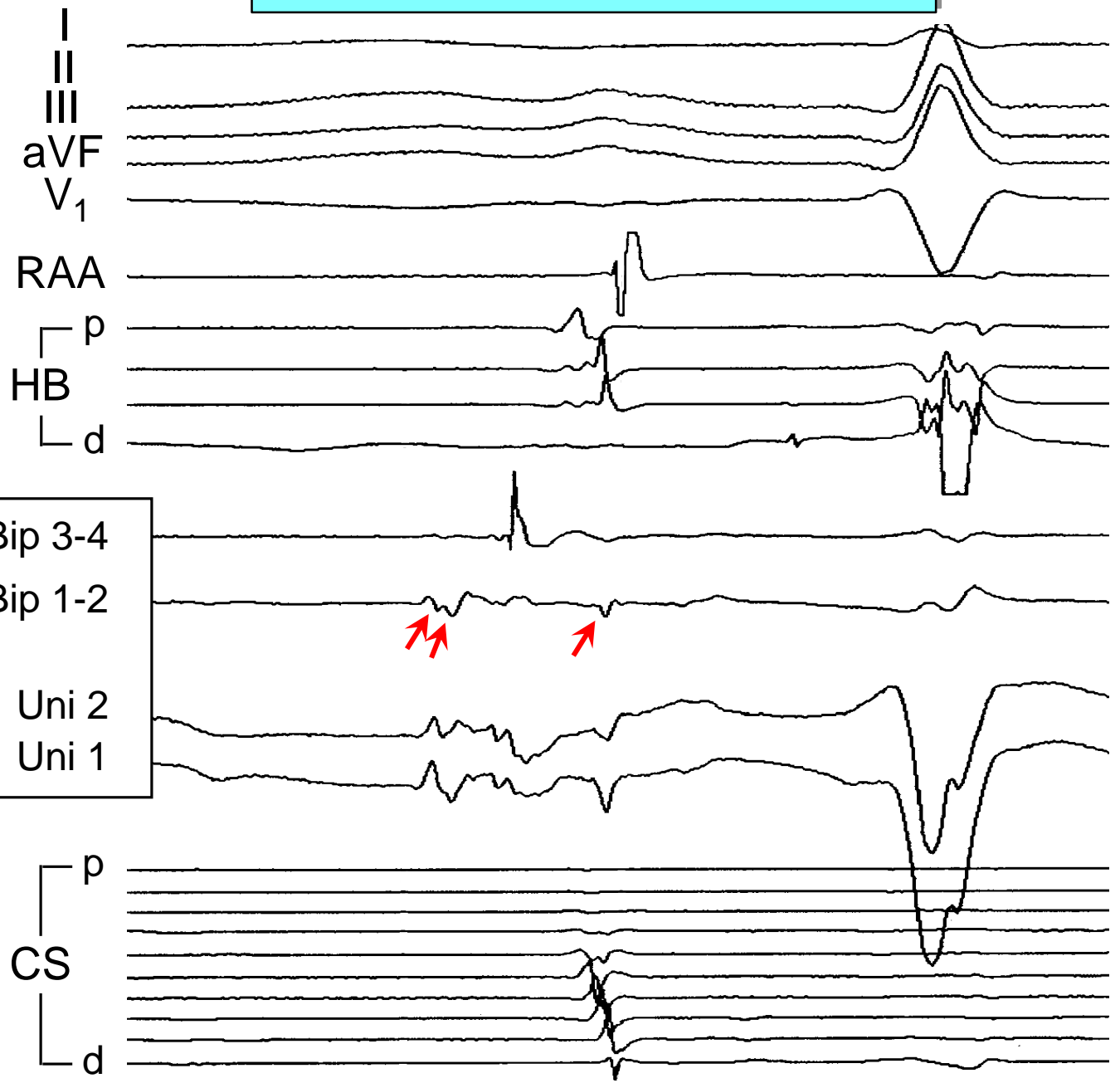
3 Possible Local Activation Times (LAT)



Mapping Left Atrial Tachycardia

37 M, LAA Tach
2 Prior Failed Ablations

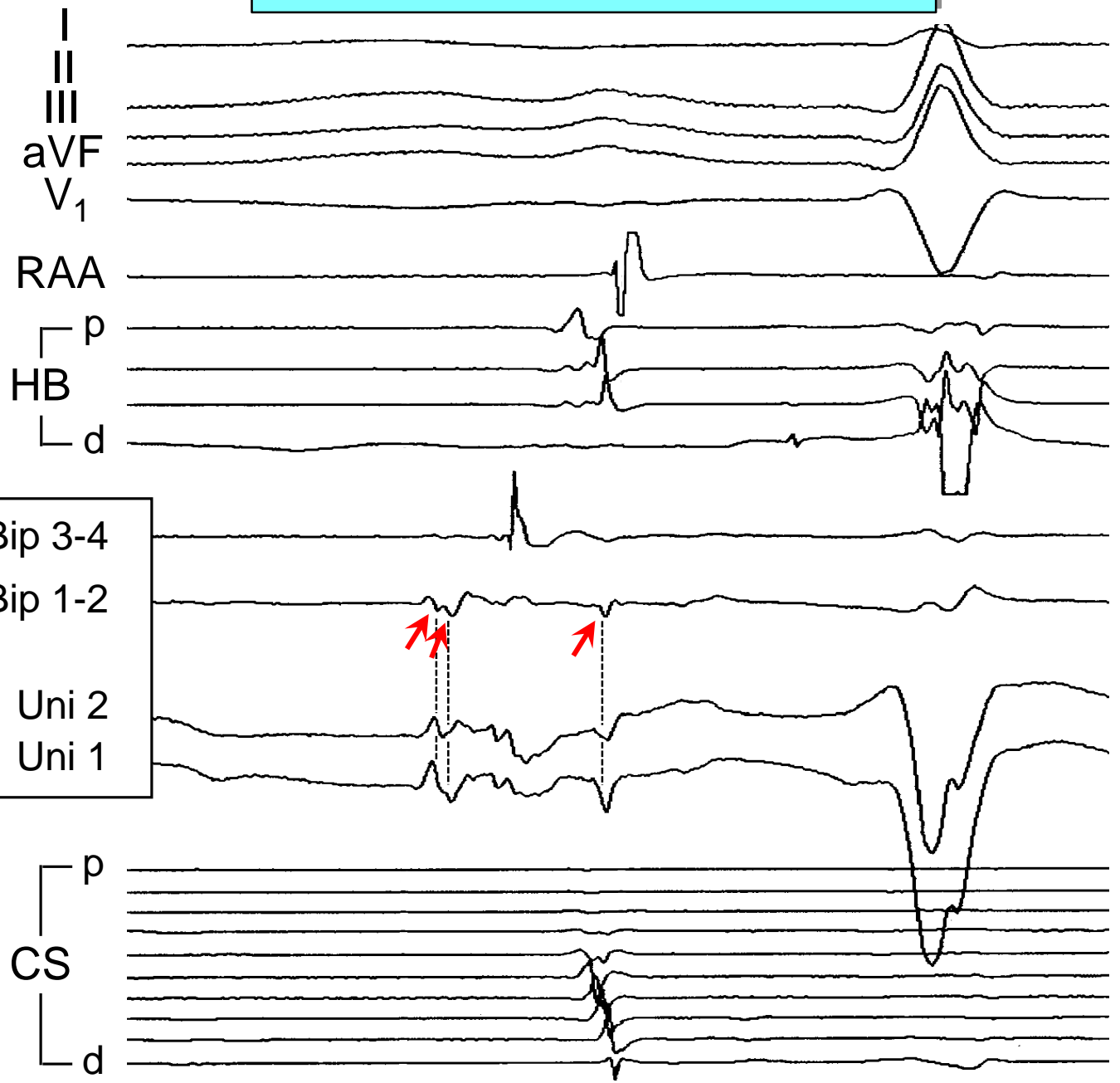
3 Possible Local Activation Times (LAT)



Mapping Left Atrial Tachycardia

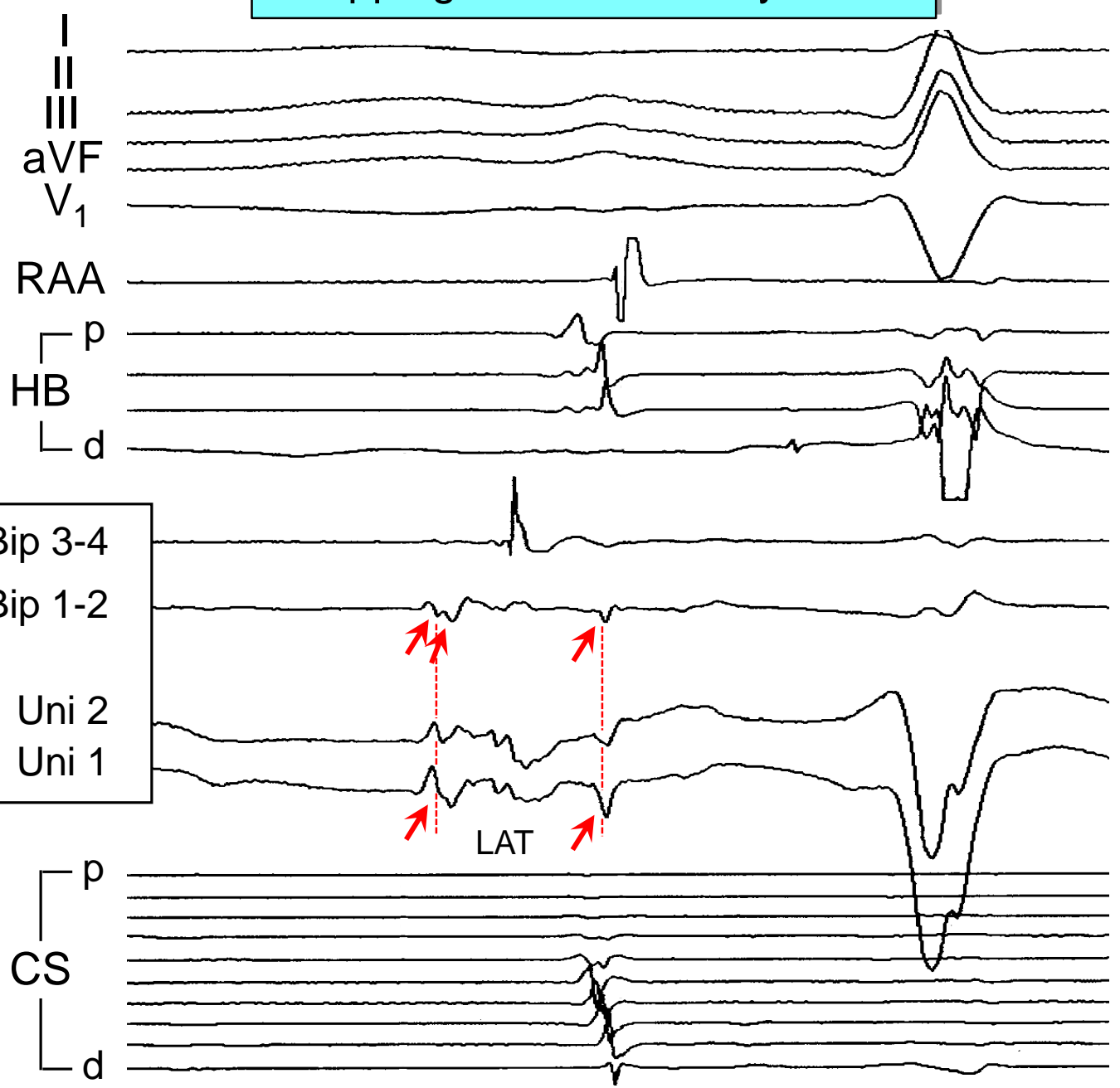
37 M, LAA Tach
2 Prior Failed Ablations

3 Possible Local Activation Times (LAT)



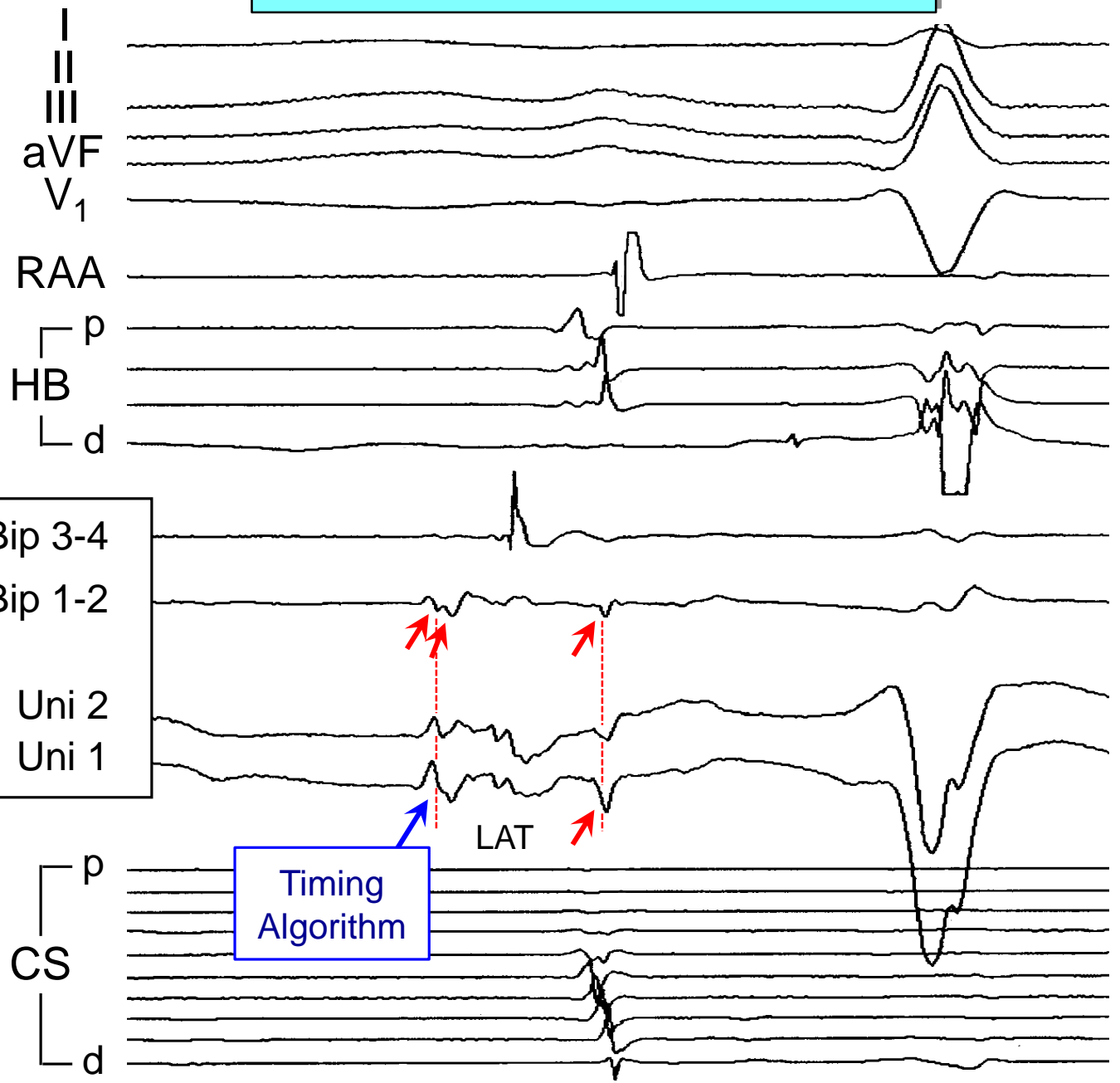
Mapping Left Atrial Tachycardia

37 M, LAA Tach
2 Prior Failed Ablations



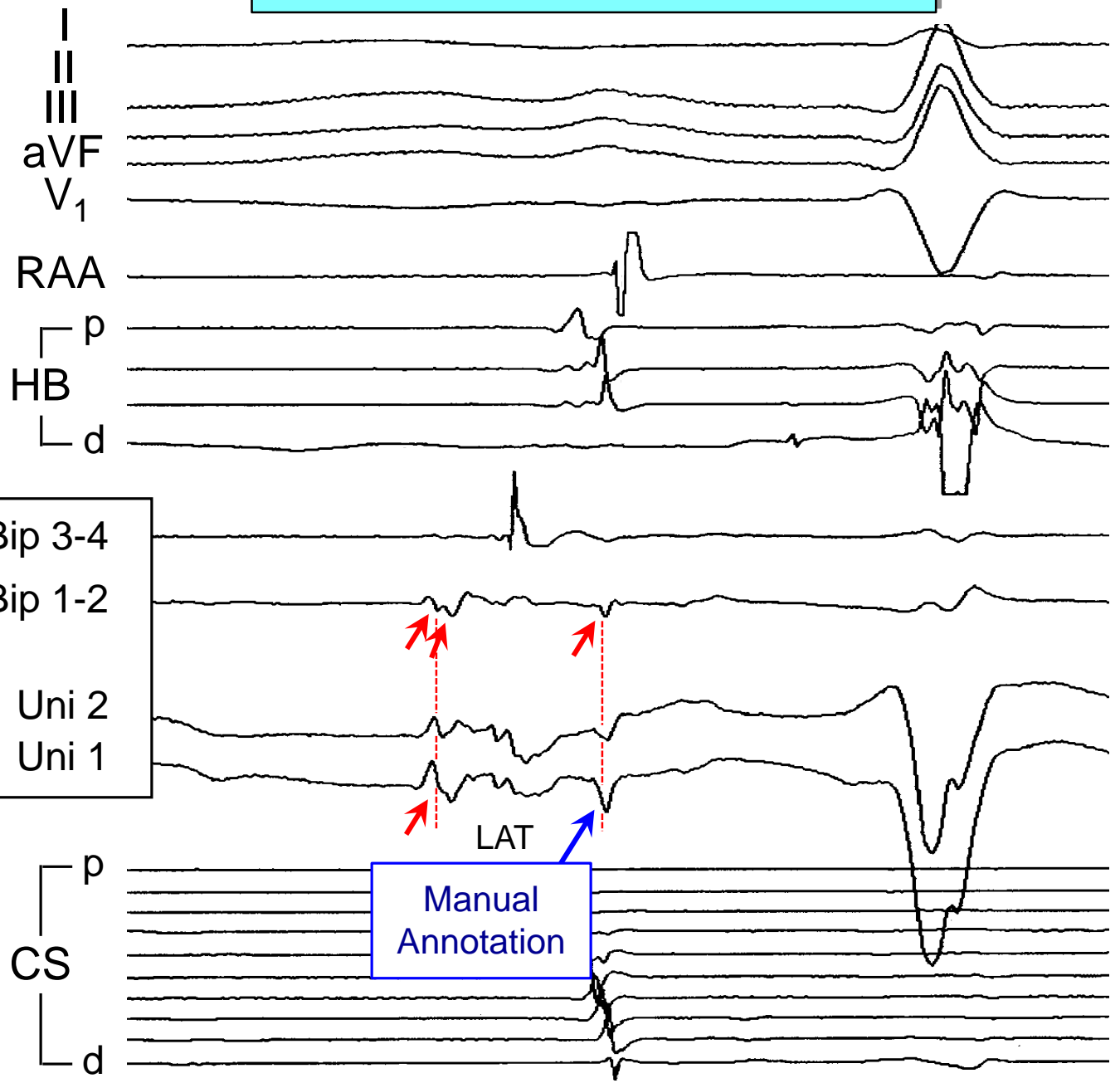
Mapping Left Atrial Tachycardia

37 M, LAA Tach
2 Prior Failed Ablations



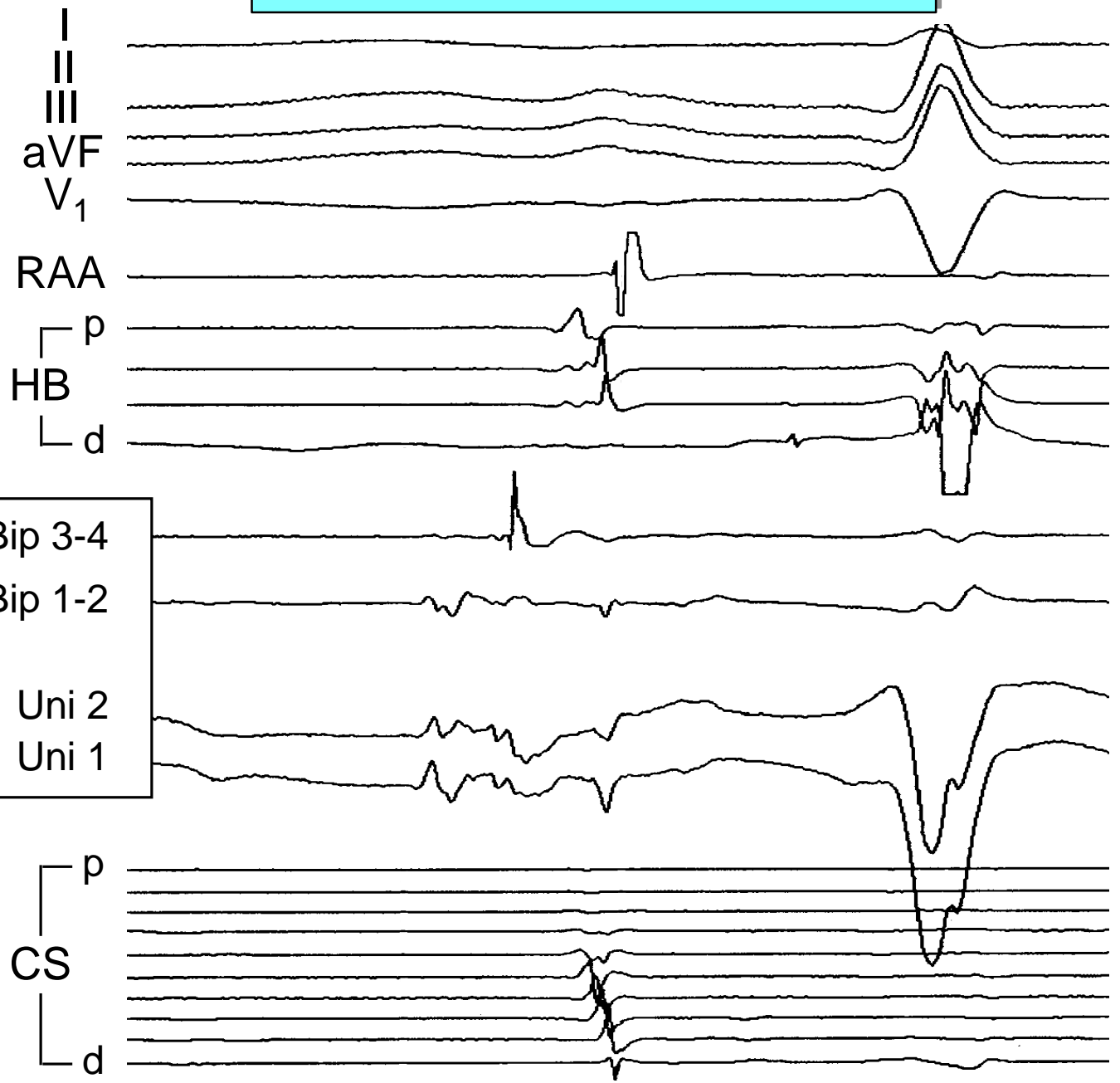
Mapping Left Atrial Tachycardia

37 M, LAA Tach
2 Prior Failed Ablations



Mapping Left Atrial Tachycardia

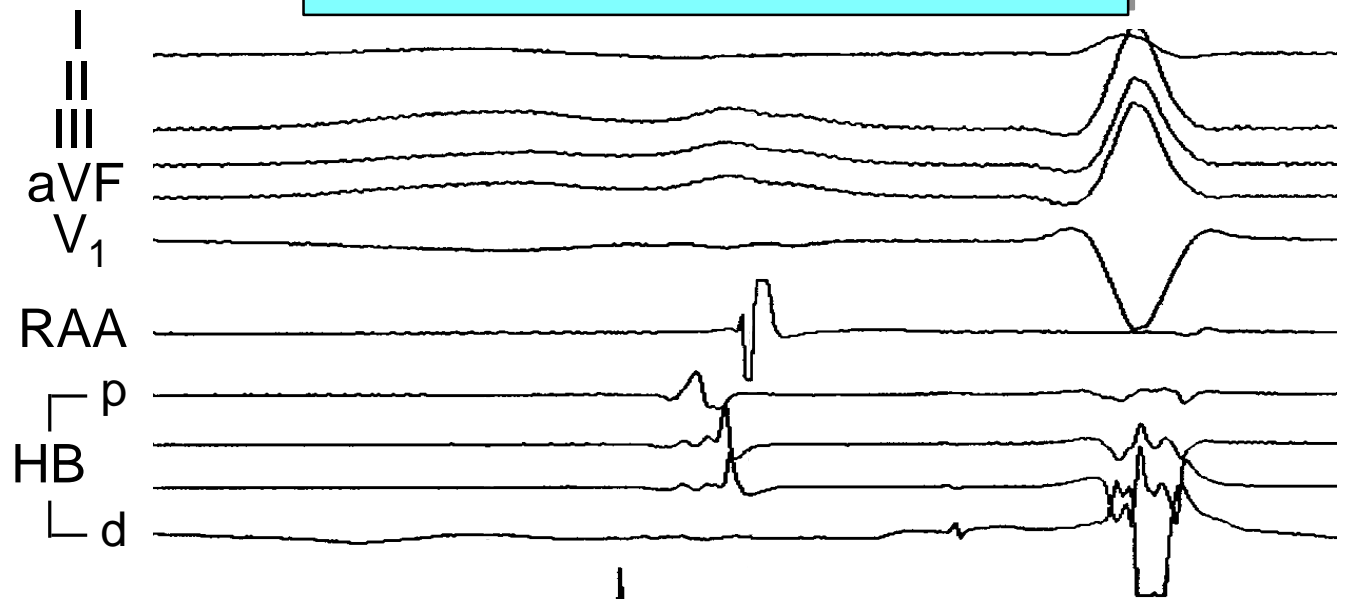
37 M, LAA Tach
2 Prior Failed Ablations



What is LAT for Uni 2?

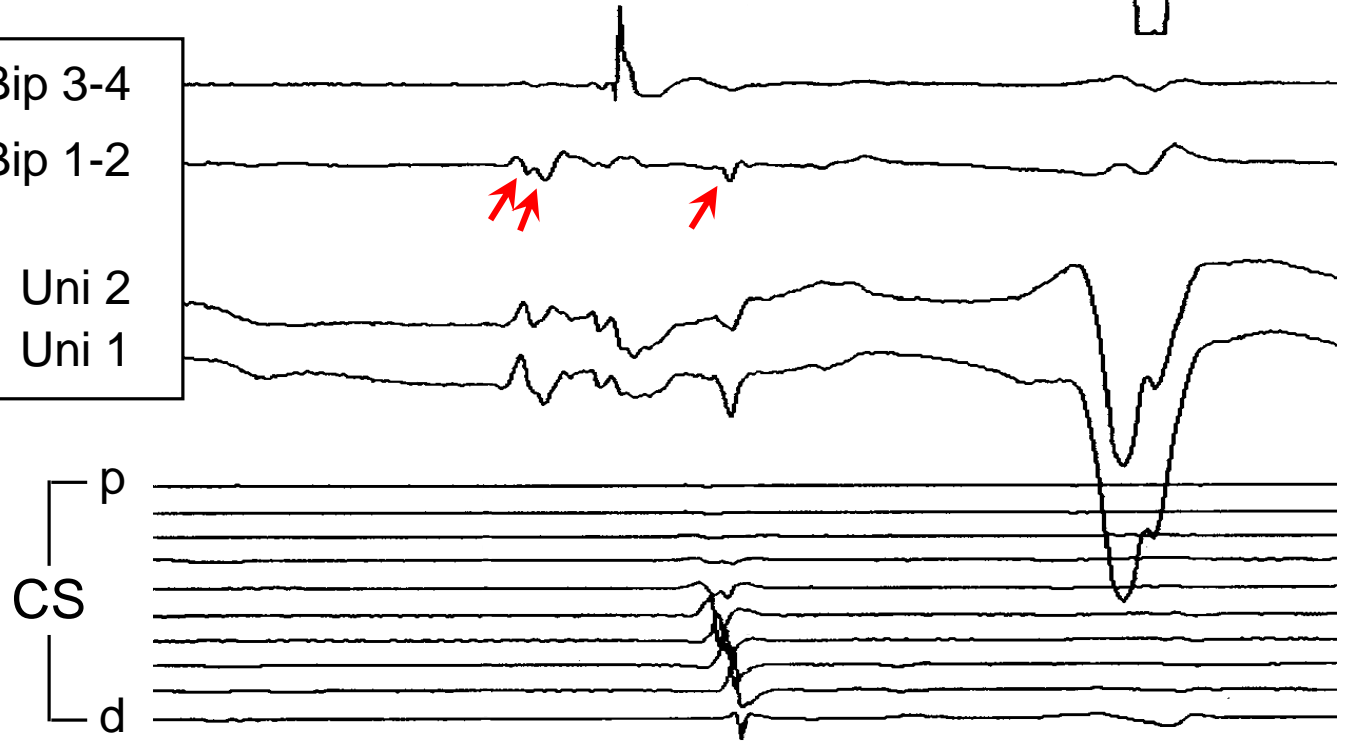
Mapping Left Atrial Tachycardia

37 M, LAA Tach
2 Prior Failed Ablations



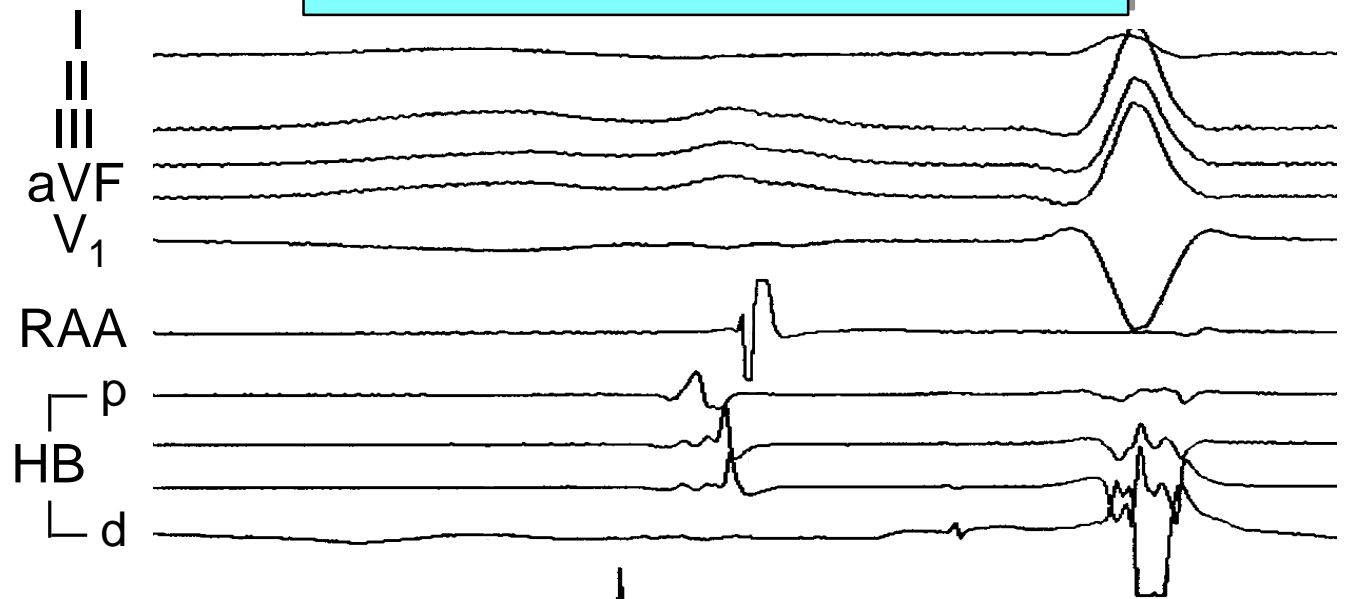
What is LAT for Uni 2?

Bip 3-4
Bip 1-2
LAA
Uni 2
Uni 1



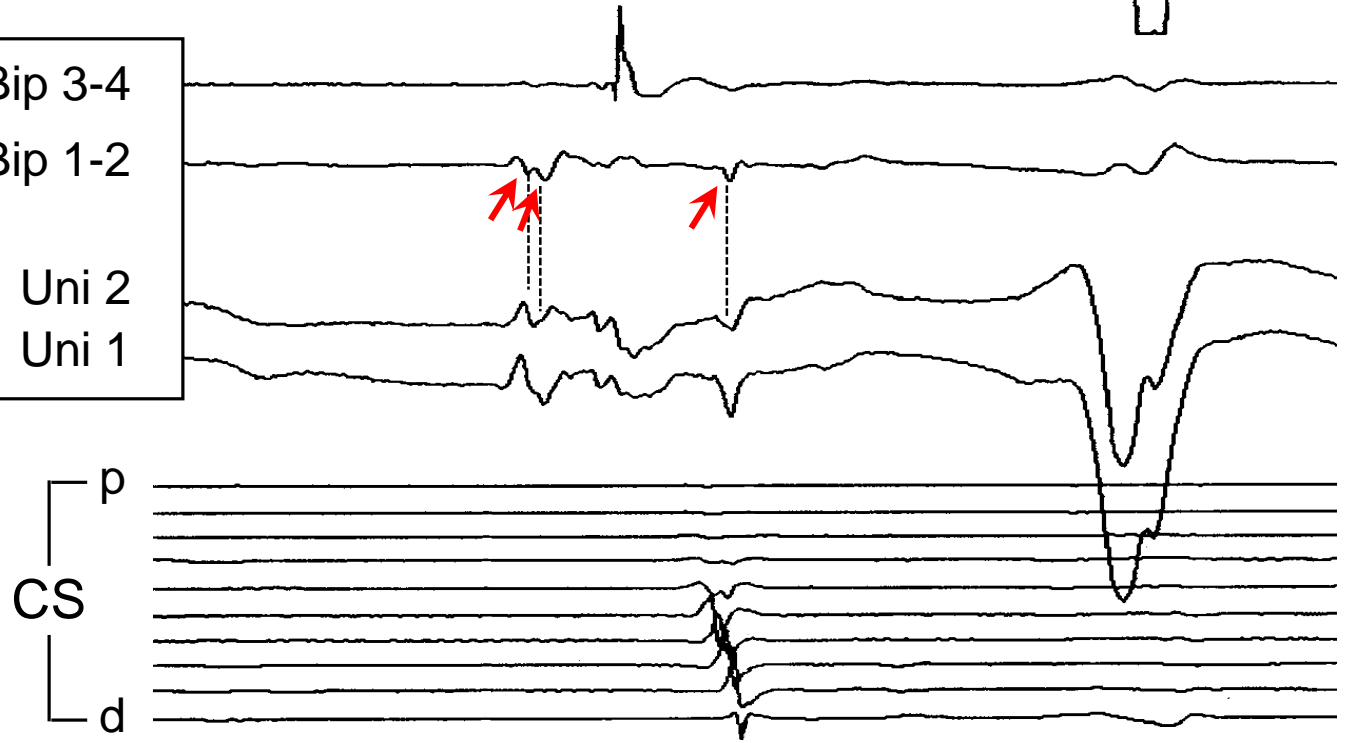
Mapping Left Atrial Tachycardia

37 M, LAA Tach
2 Prior Failed Ablations



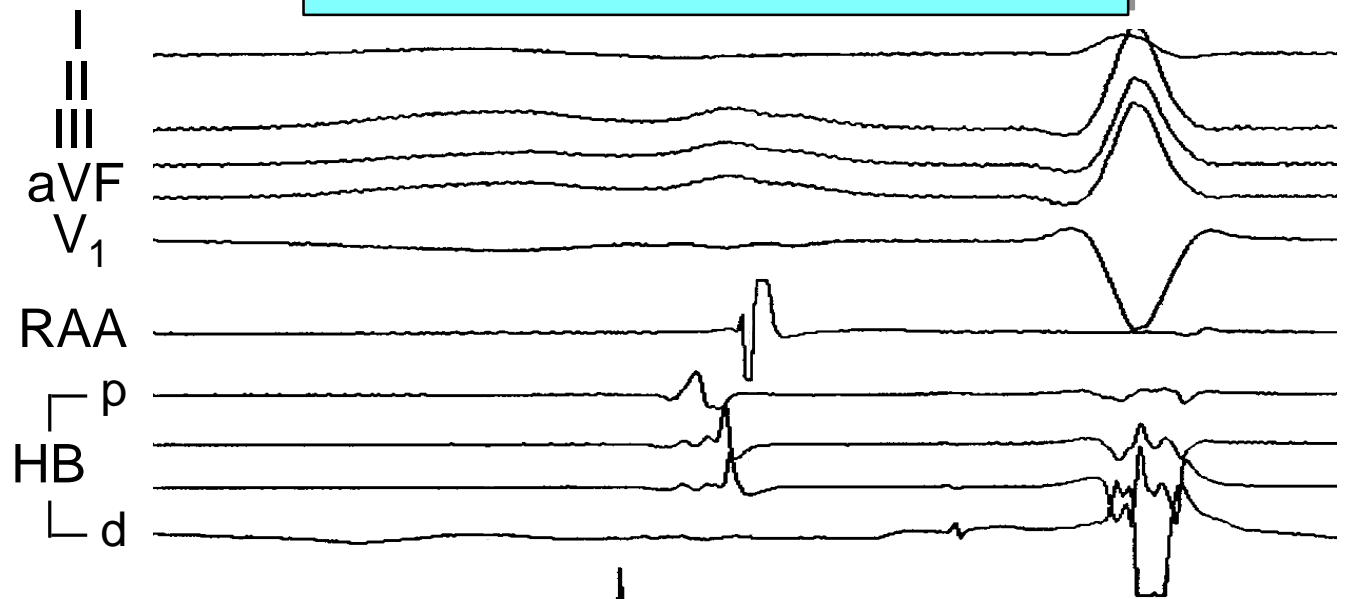
What is LAT for Uni 2?

Bip 3-4
Bip 1-2
LAA
Uni 2
Uni 1



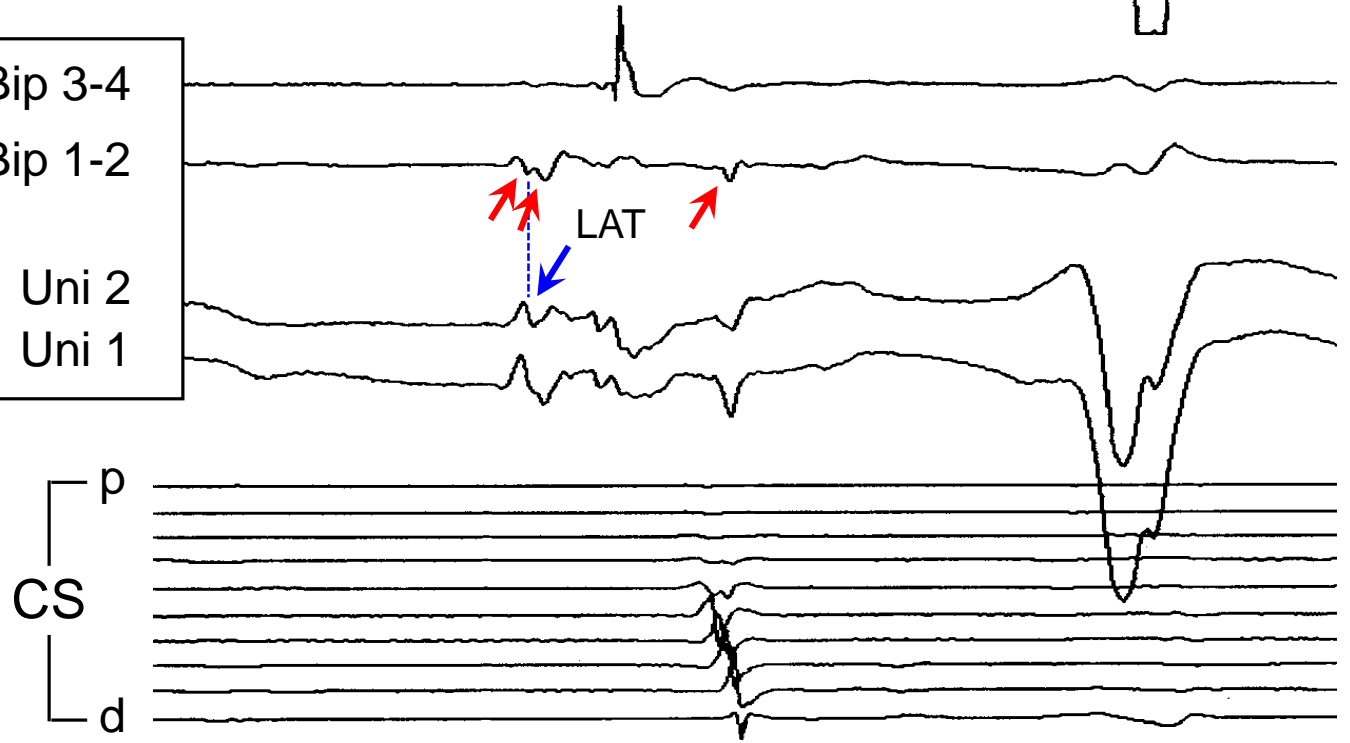
Mapping Left Atrial Tachycardia

37 M, LAA Tach
2 Prior Failed Ablations



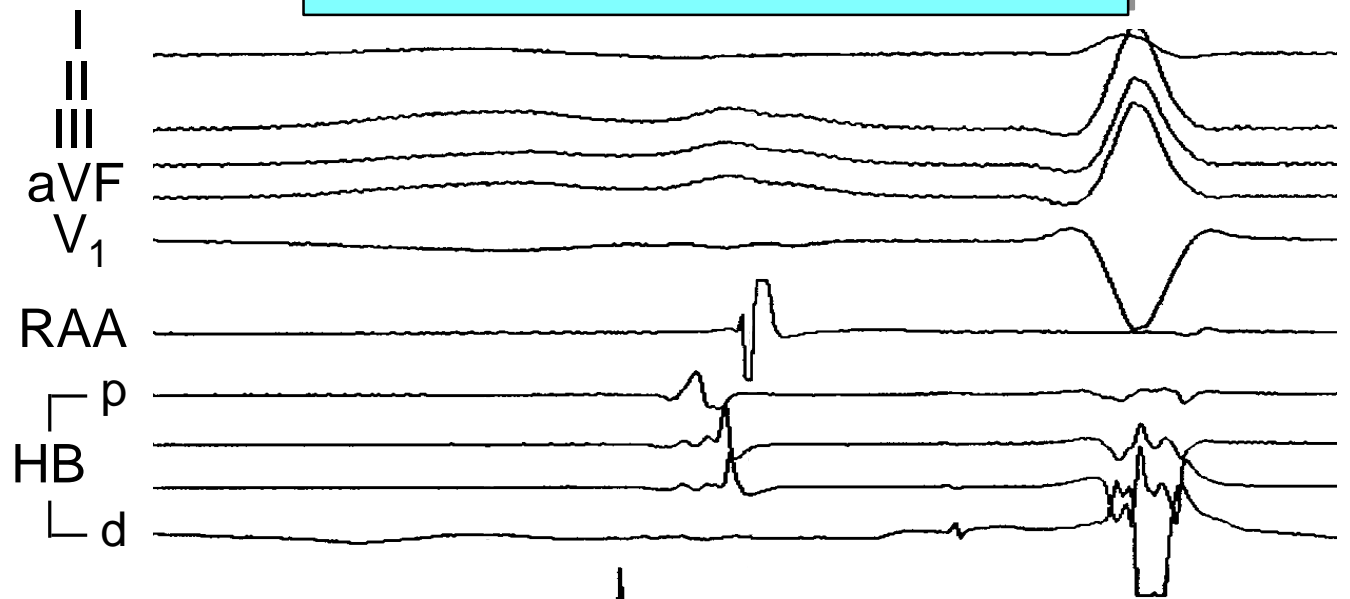
What is LAT for Uni 2?

Bip 3-4
Bip 1-2
LAA
Uni 2
Uni 1



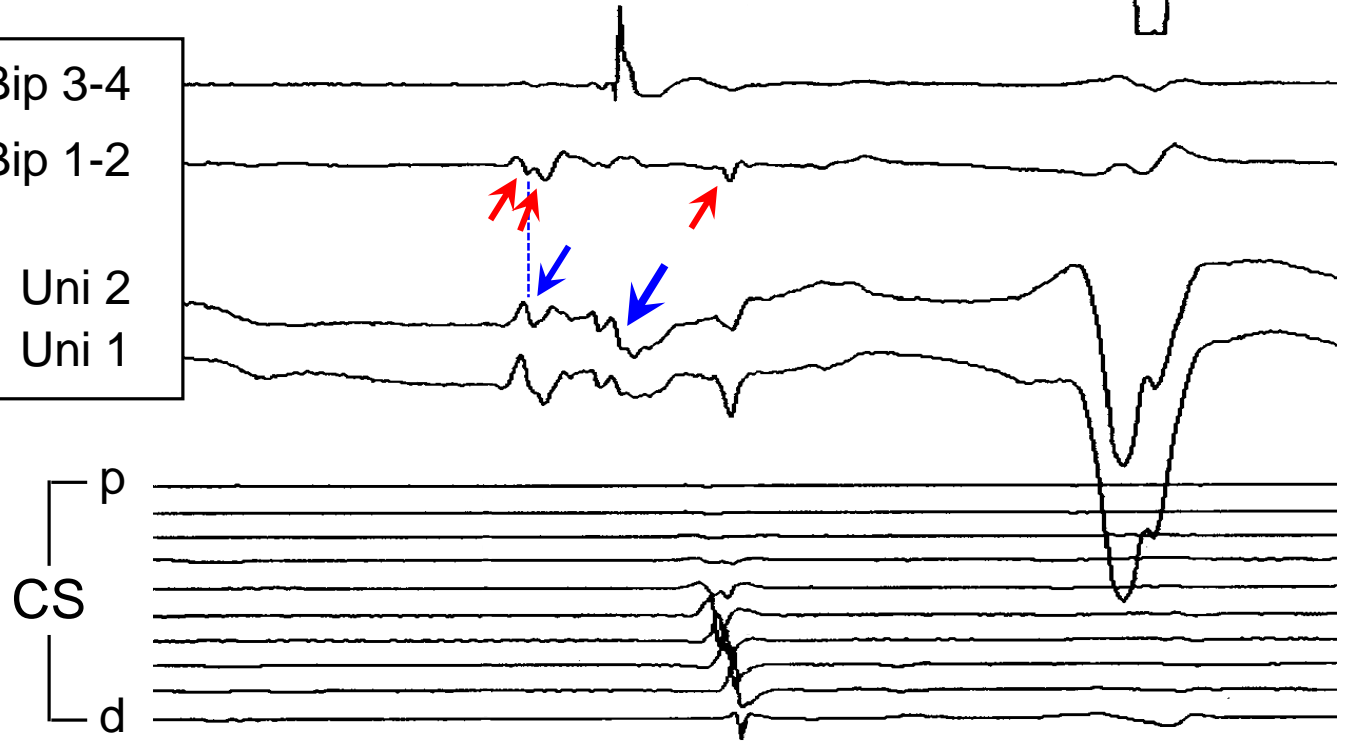
Mapping Left Atrial Tachycardia

37 M, LAA Tach
2 Prior Failed Ablations



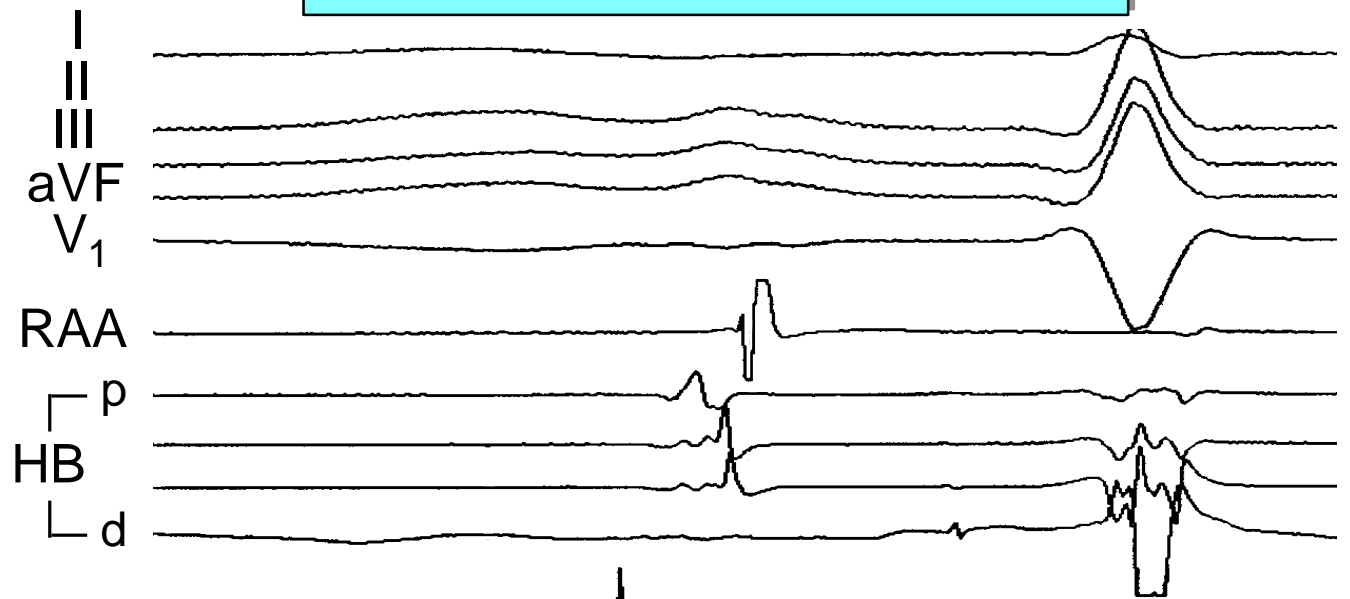
What is LAT for Uni 2?

Bip 3-4
Bip 1-2
LAA
Uni 2
Uni 1



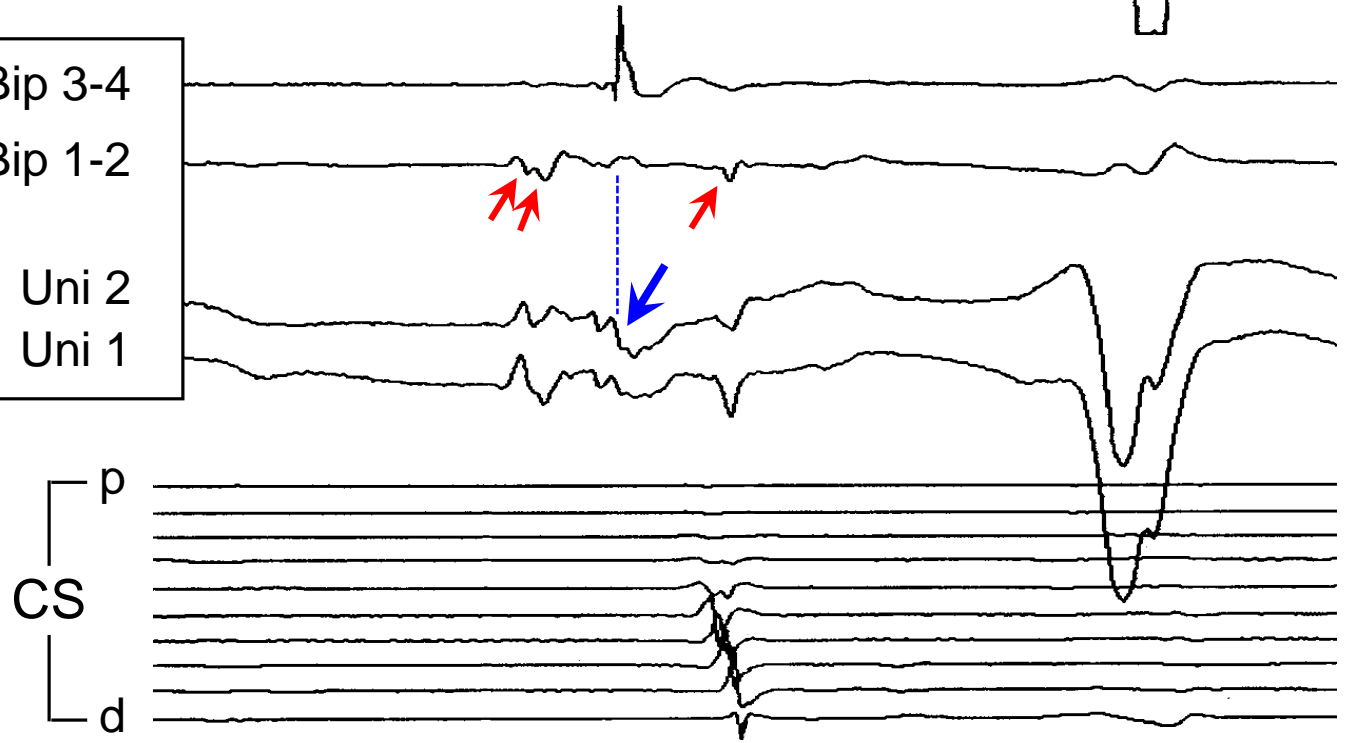
Mapping Left Atrial Tachycardia

37 M, LAA Tach
2 Prior Failed Ablations



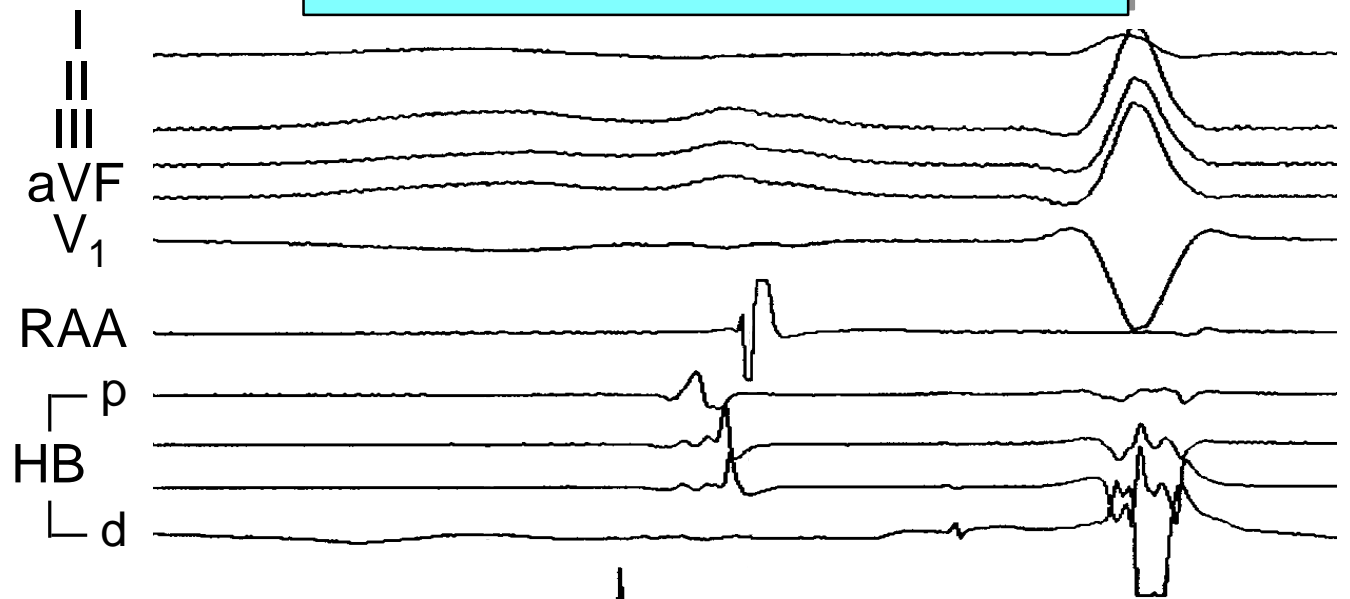
What is LAT for Uni 2?

Bip 3-4
Bip 1-2
LAA
Uni 2
Uni 1



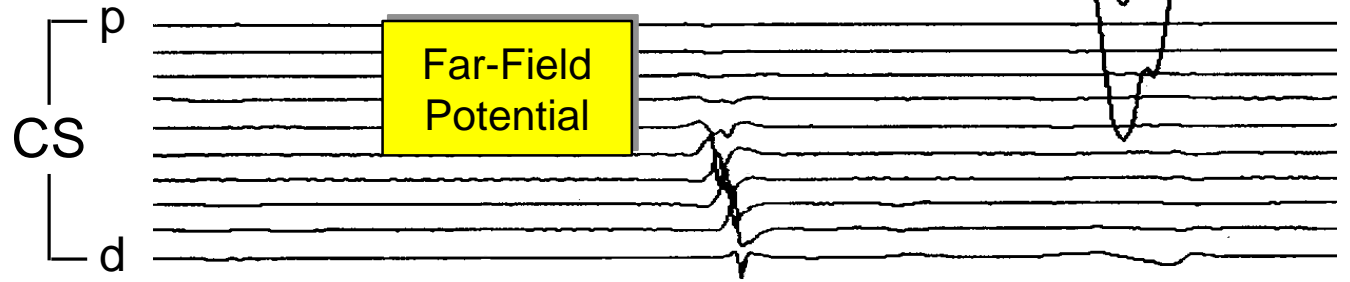

Mapping Left Atrial Tachycardia

37 M, LAA Tach
2 Prior Failed Ablations




What is LAT for Uni 2?

Bip 3-4
Bip 1-2
LAA
Uni 2
Uni 1



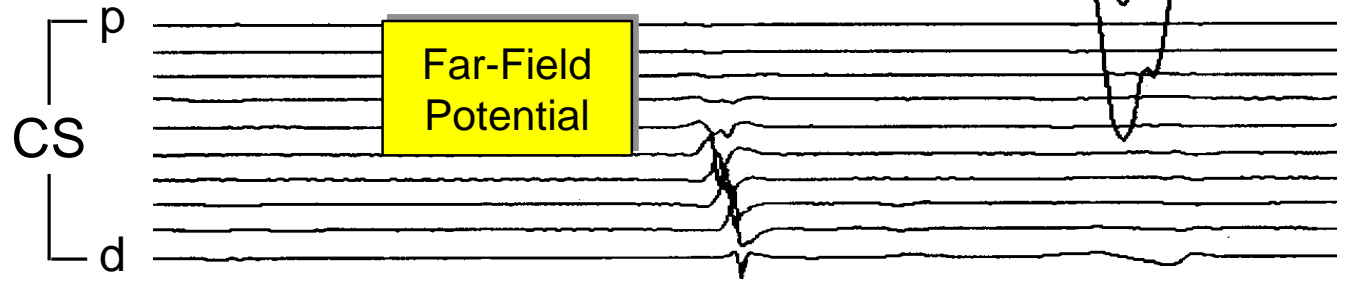

Mapping Left Atrial Tachycardia

37 M, LAA Tach
2 Prior Failed Ablations



What is LAT for Uni 2?

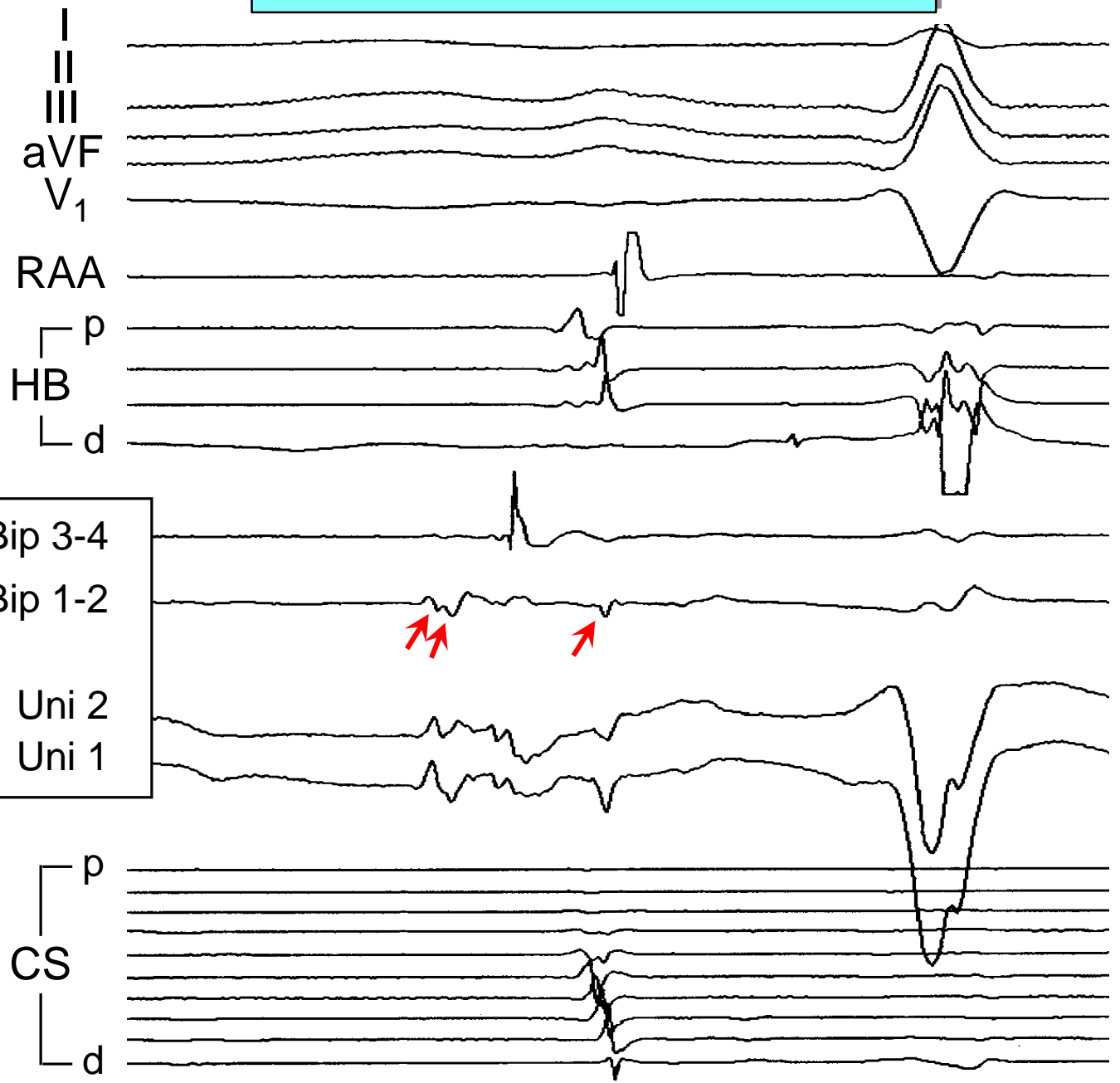
Bip 3-4
Bip 1-2
LAA
Uni 2
Uni 1



Mapping Left Atrial Tachycardia

37 M, LAA Tach
2 Prior Failed Ablations

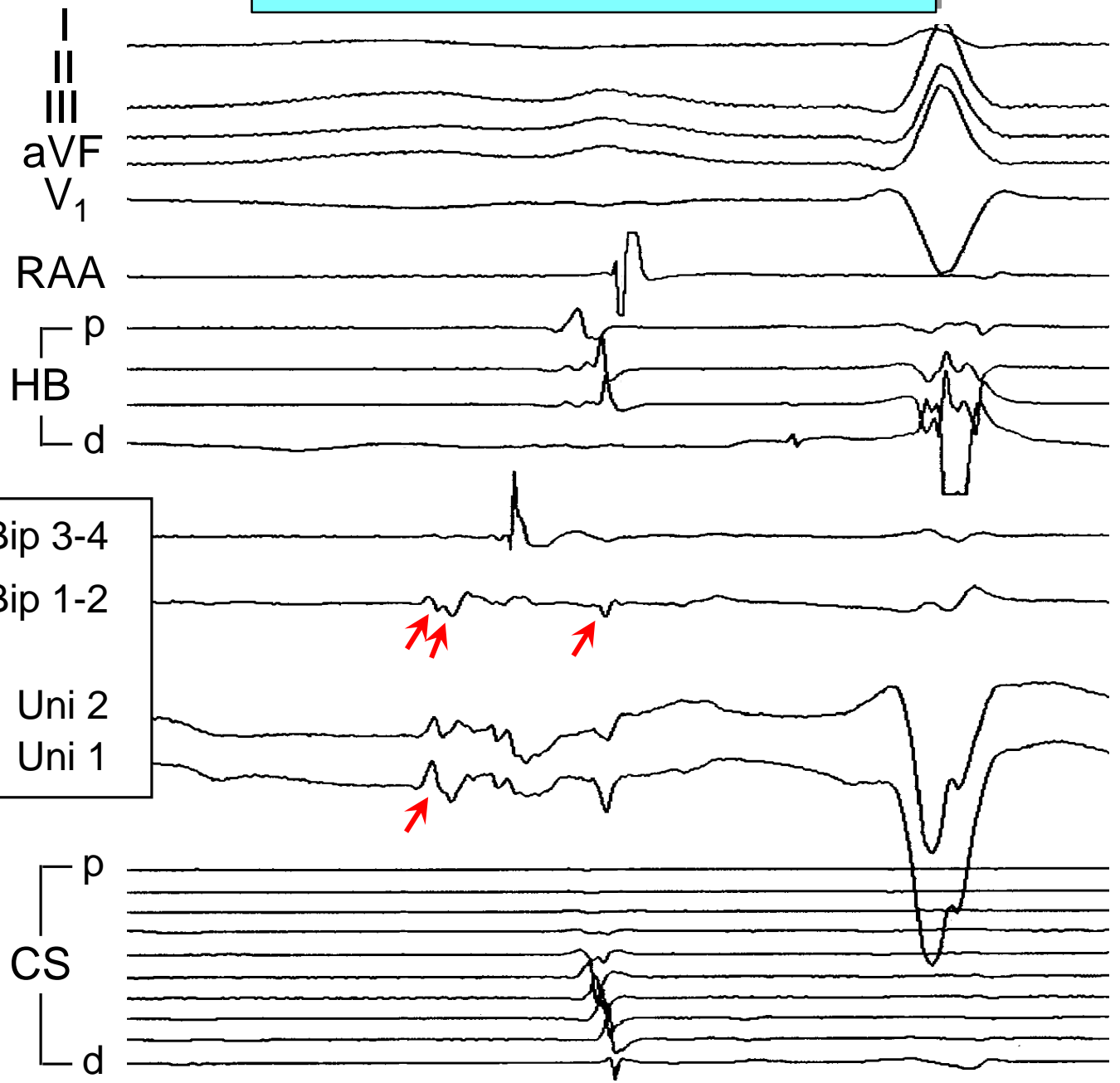
First Look
at Bipolar EGM
(Exclude Far-Field Potentials)



Mapping Left Atrial Tachycardia

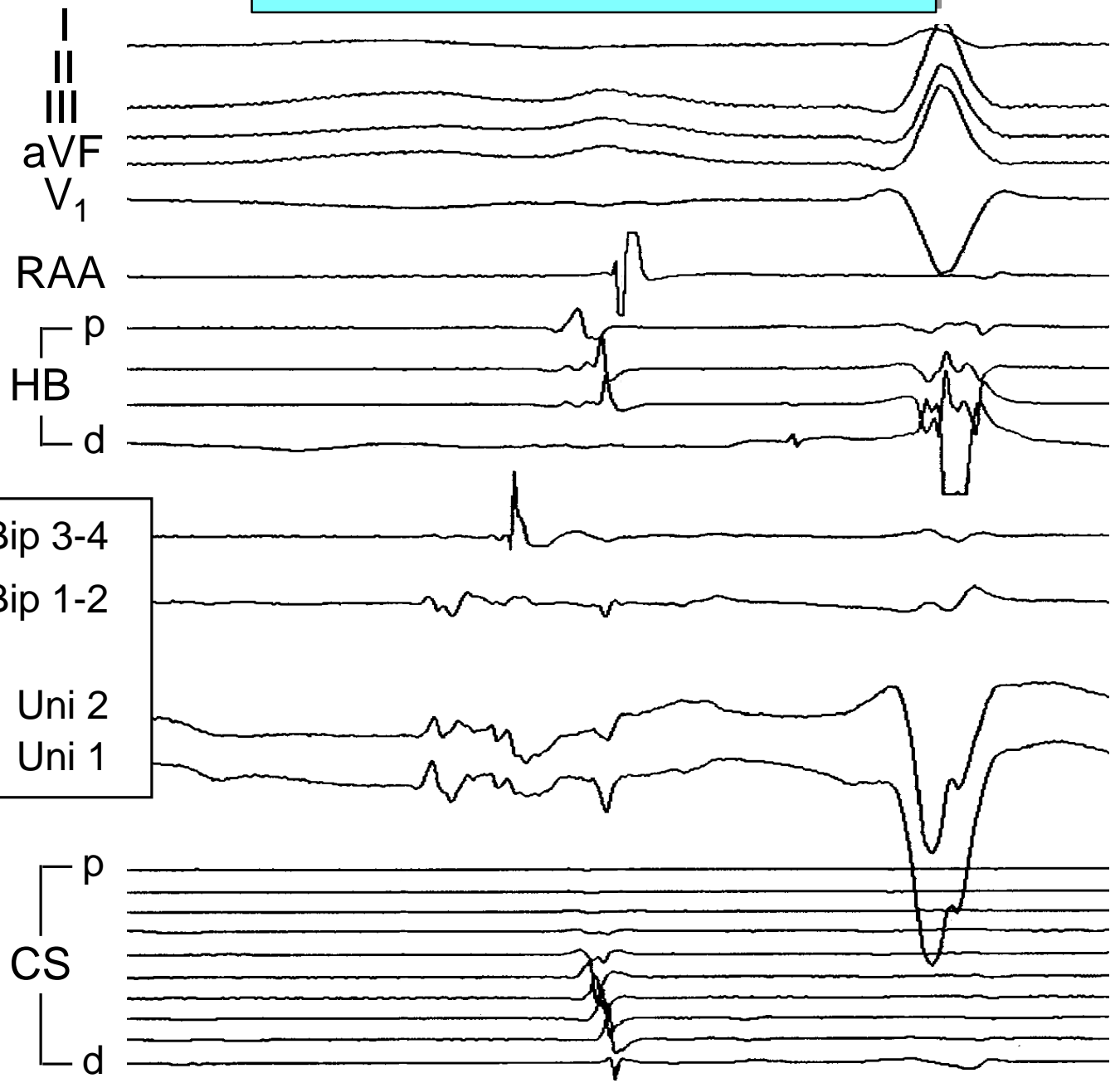
37 M, LAA Tach
2 Prior Failed Ablations

First Look
at Bipolar EGM
(Exclude Far-Field Potentials)



Mapping Left Atrial Tachycardia

37 M, LAA Tach
2 Prior Failed Ablations



Earliest EGM

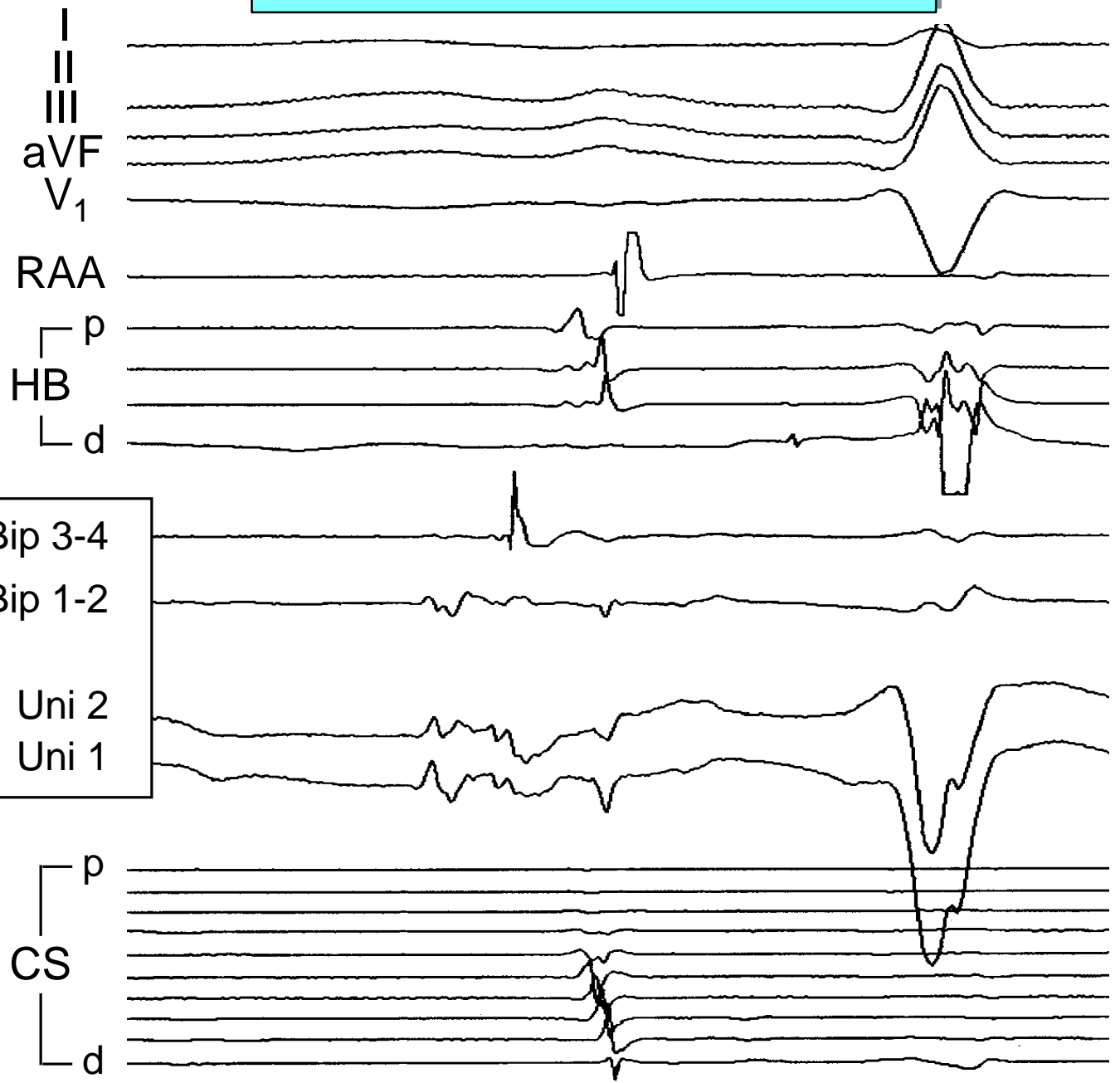
Bip 3-4
Bip 1-2
LAA
Uni 2
Uni 1

Mapping Left Atrial Tachycardia

37 M, LAA Tach
2 Prior Failed Ablations

Timing of
Earliest Far-Field
Activation

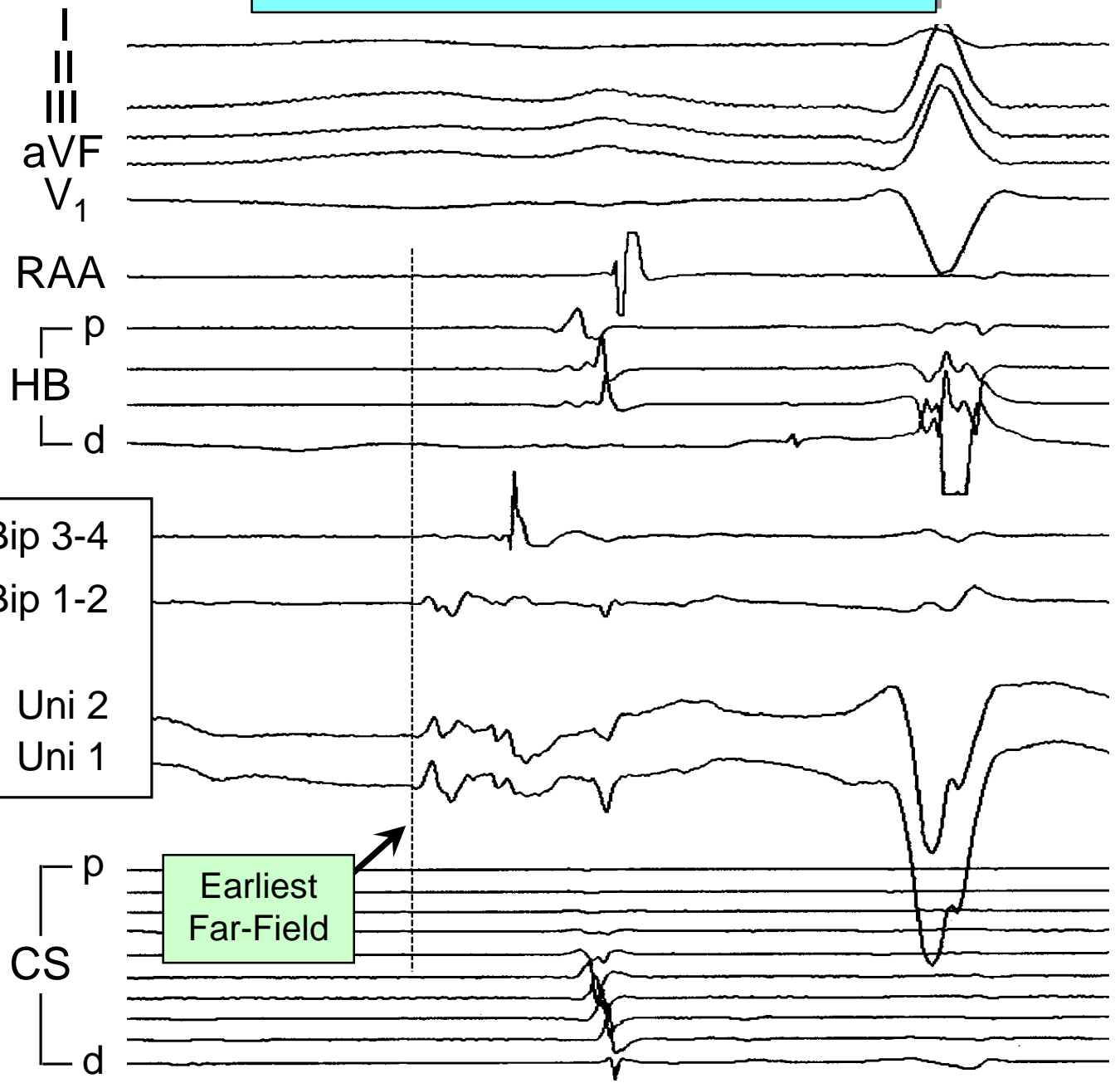
Earliest
EGM



Mapping Left Atrial Tachycardia

37 M, LAA Tach
2 Prior Failed Ablations

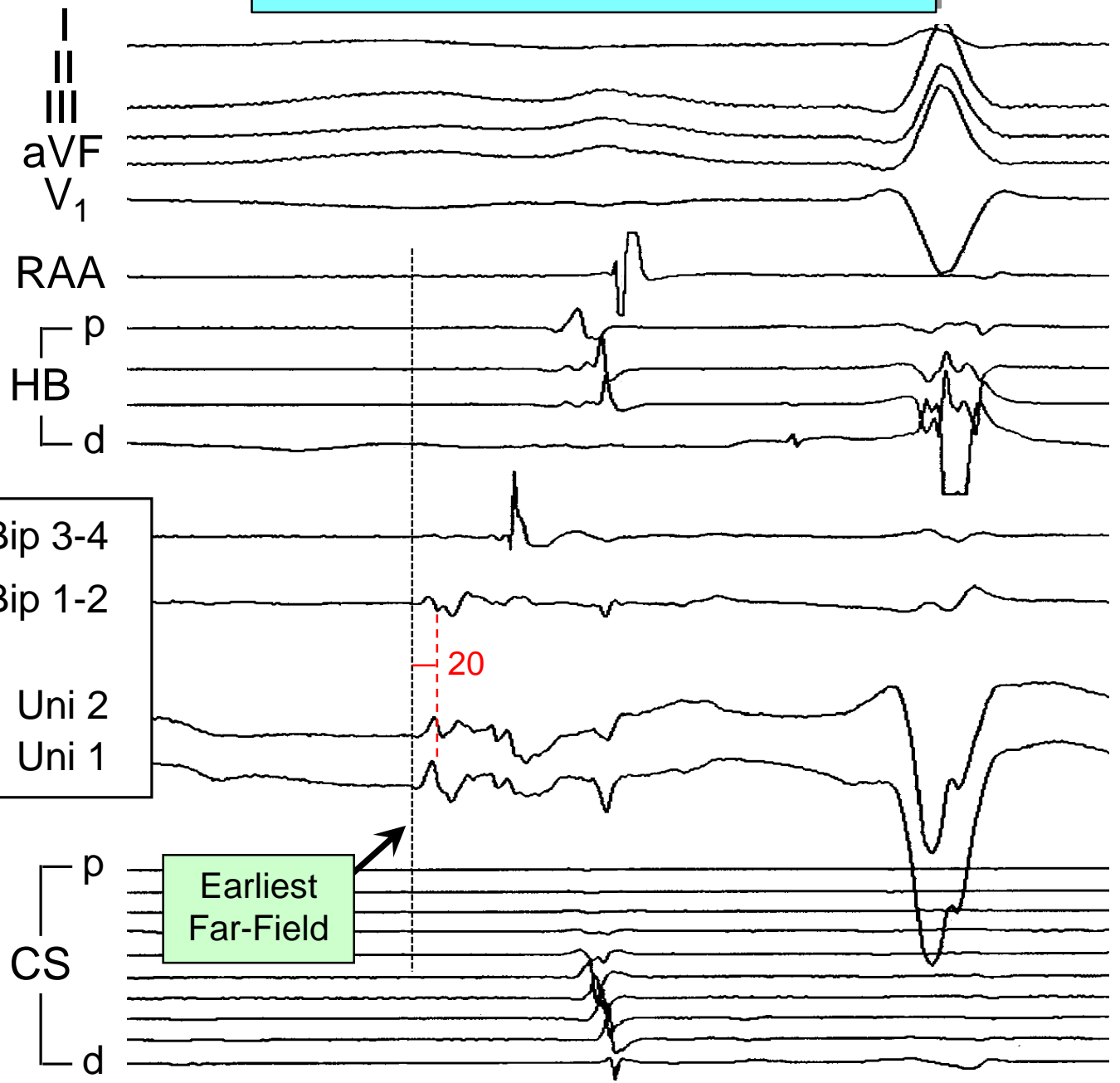
Timing of
Earliest Far-Field
Activation



Mapping Left Atrial Tachycardia

37 M, LAA Tach
2 Prior Failed Ablations

Earliest Possible Local Activation Time
20 ms

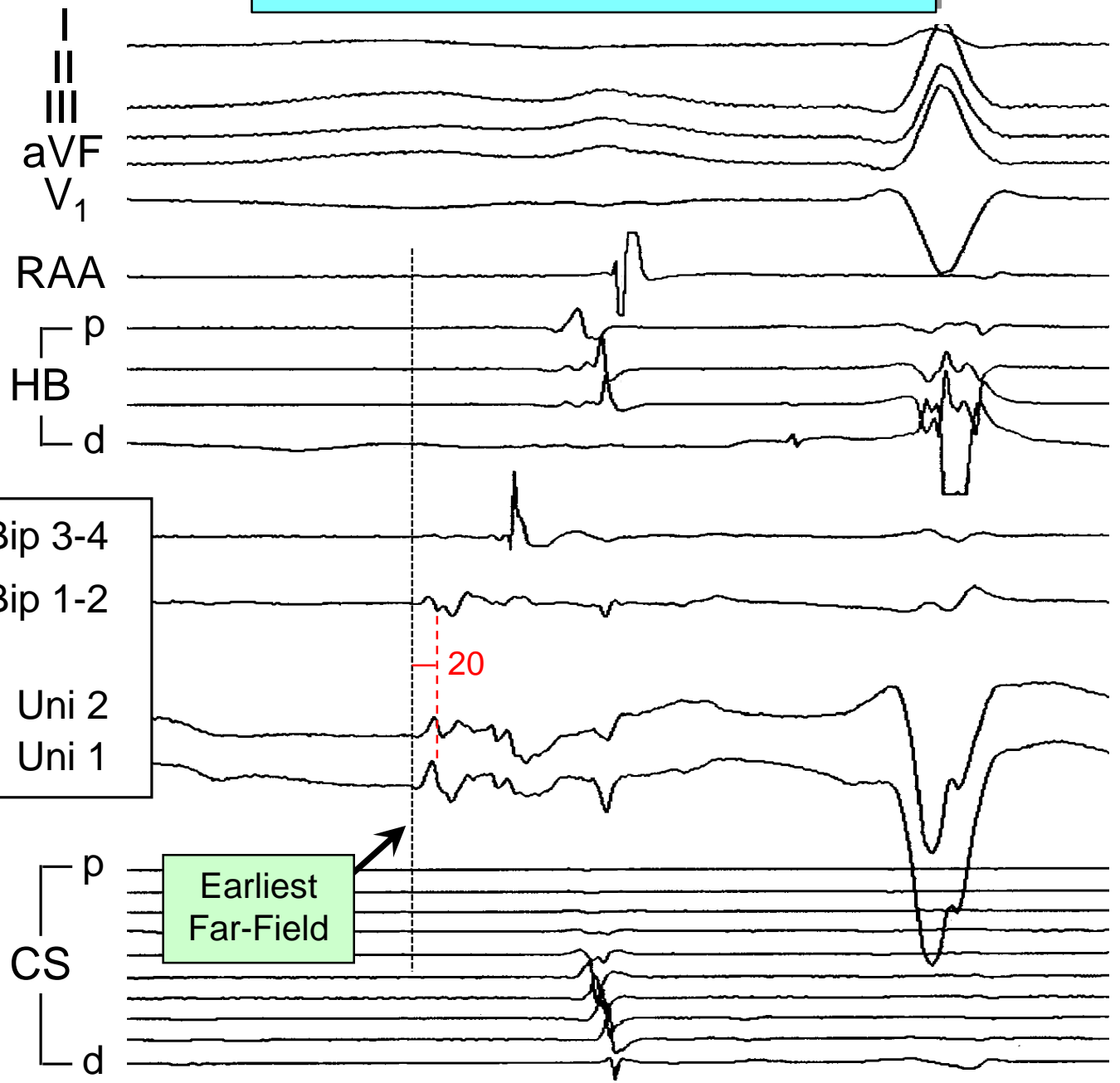


Mapping Left Atrial Tachycardia

37 M, LAA Tach
2 Prior Failed Ablations

Earliest Possible Local Activation Time
20 ms

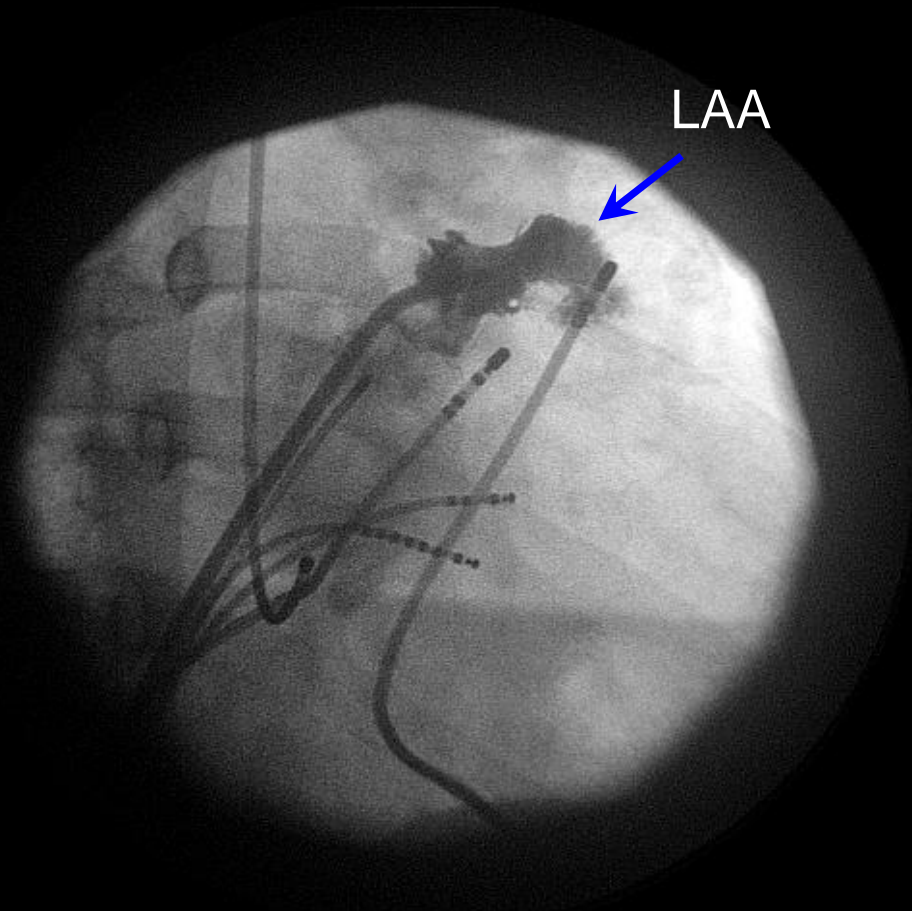
Where is Earliest Activation?



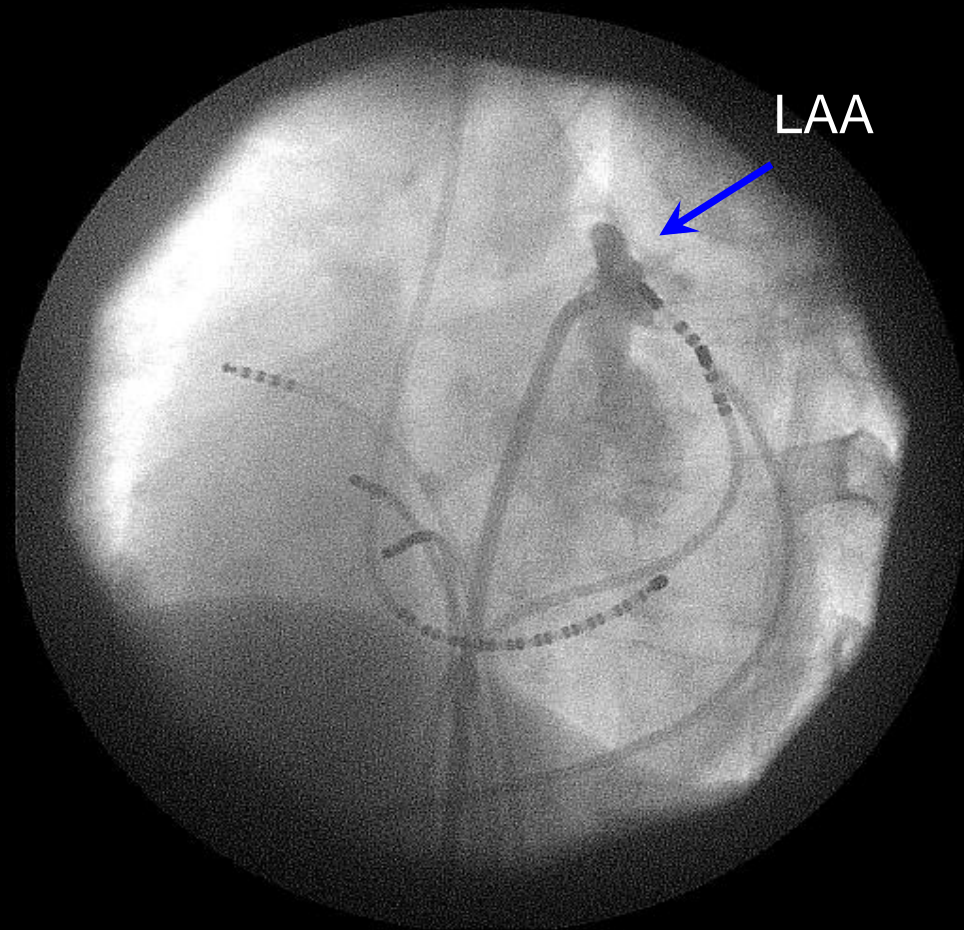
Earliest Far-Field

20

LAA Angiogram

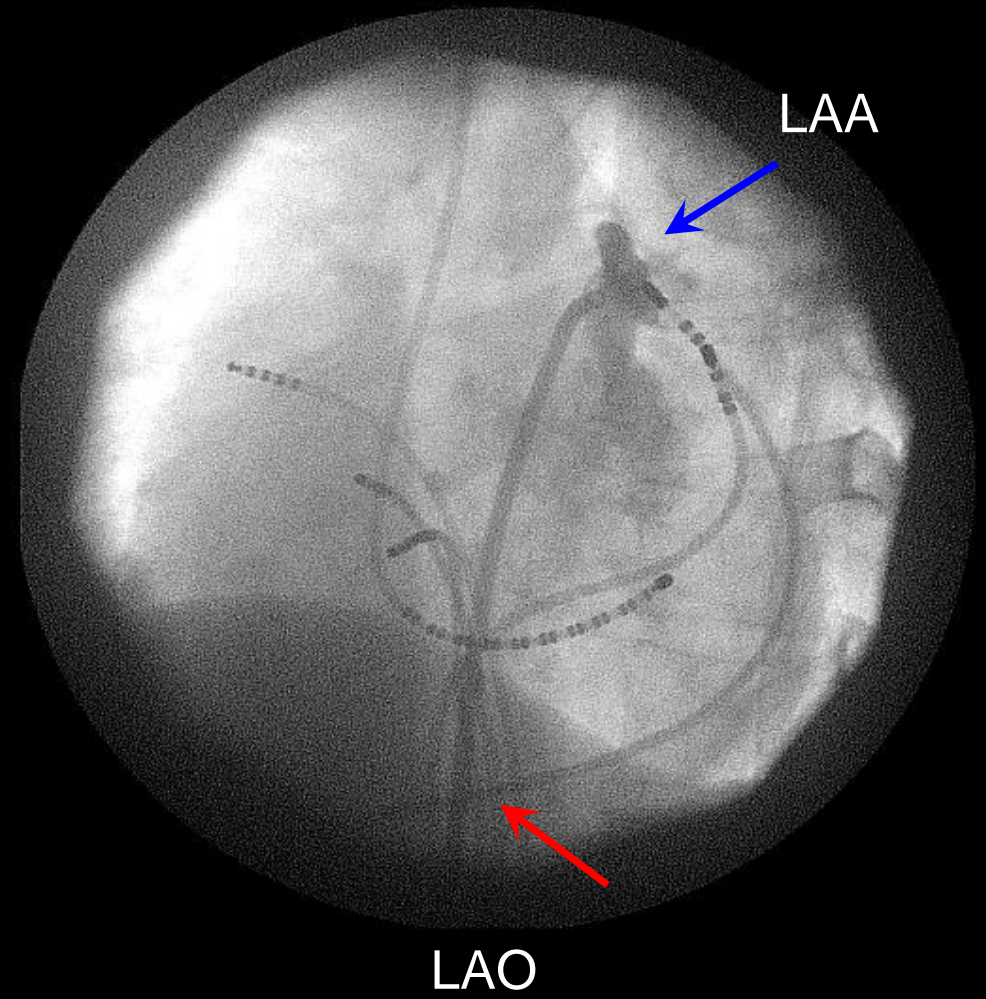
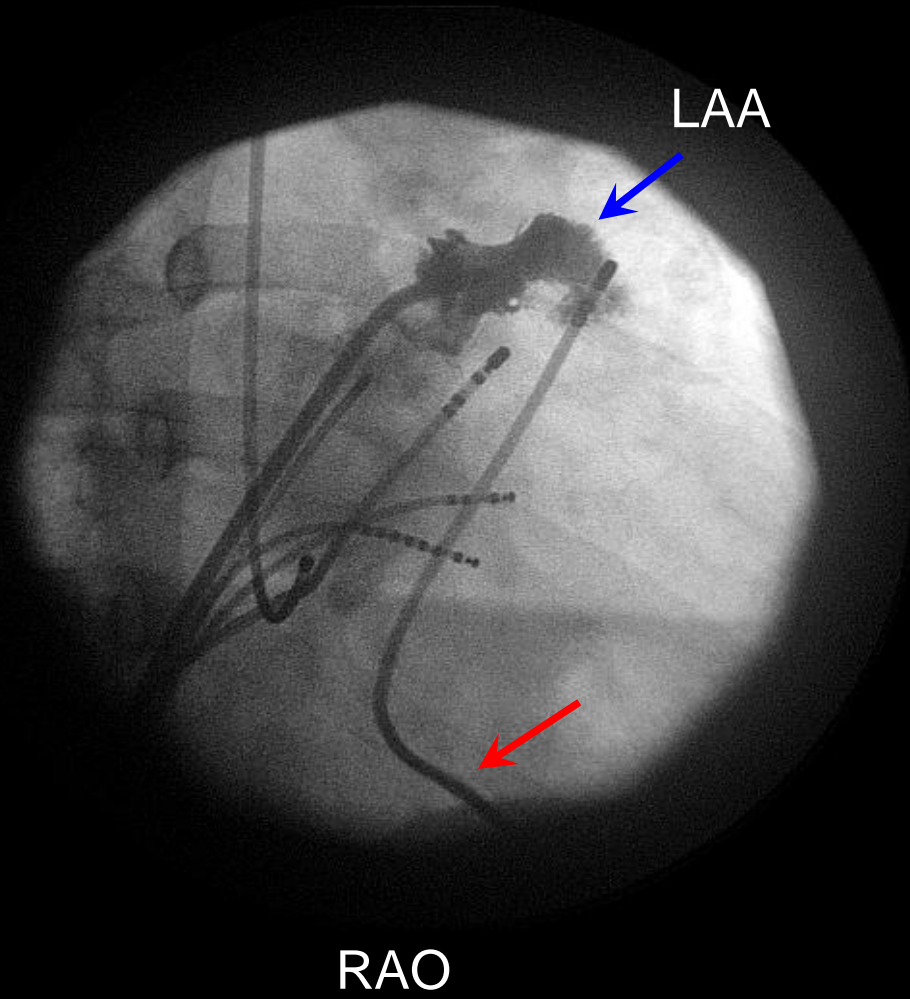


RAO

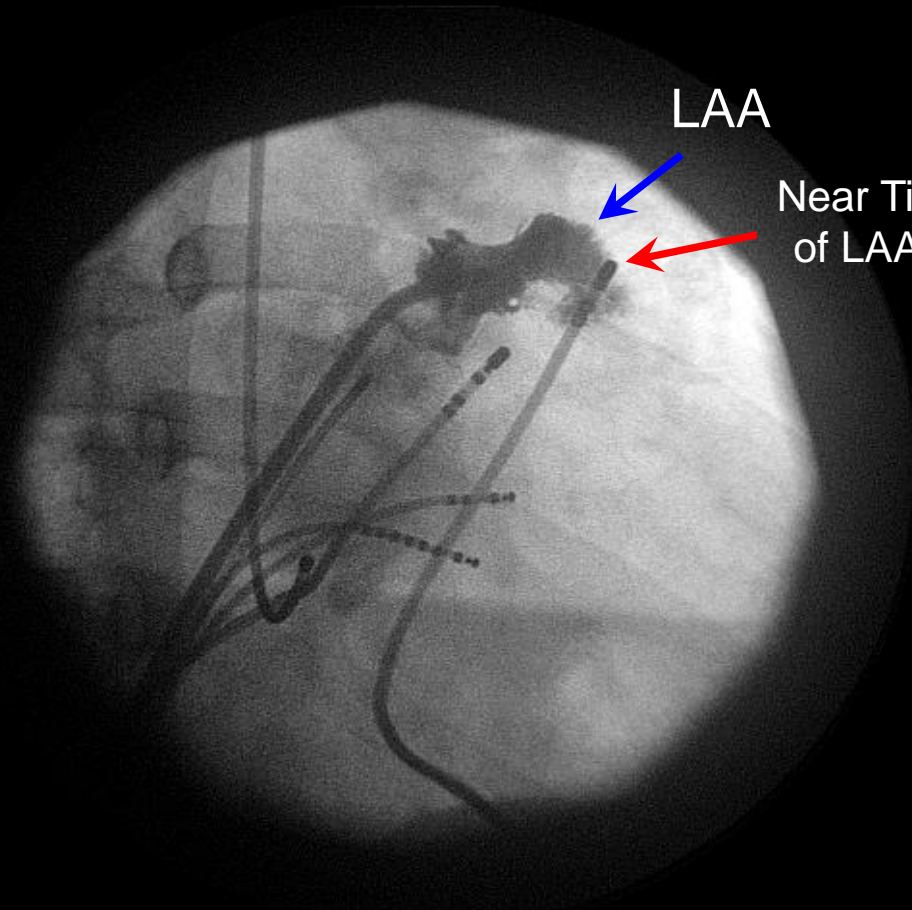


LAO

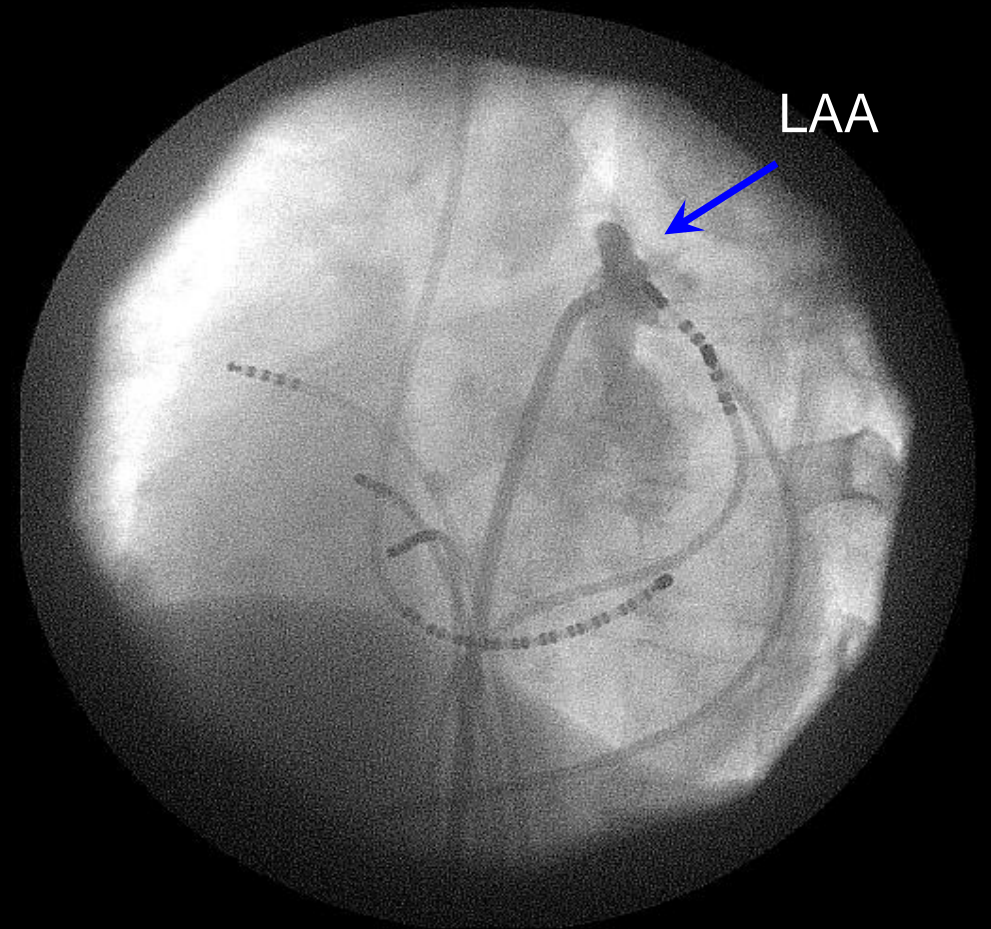
Epicardial Catheter



Epicardial Catheter

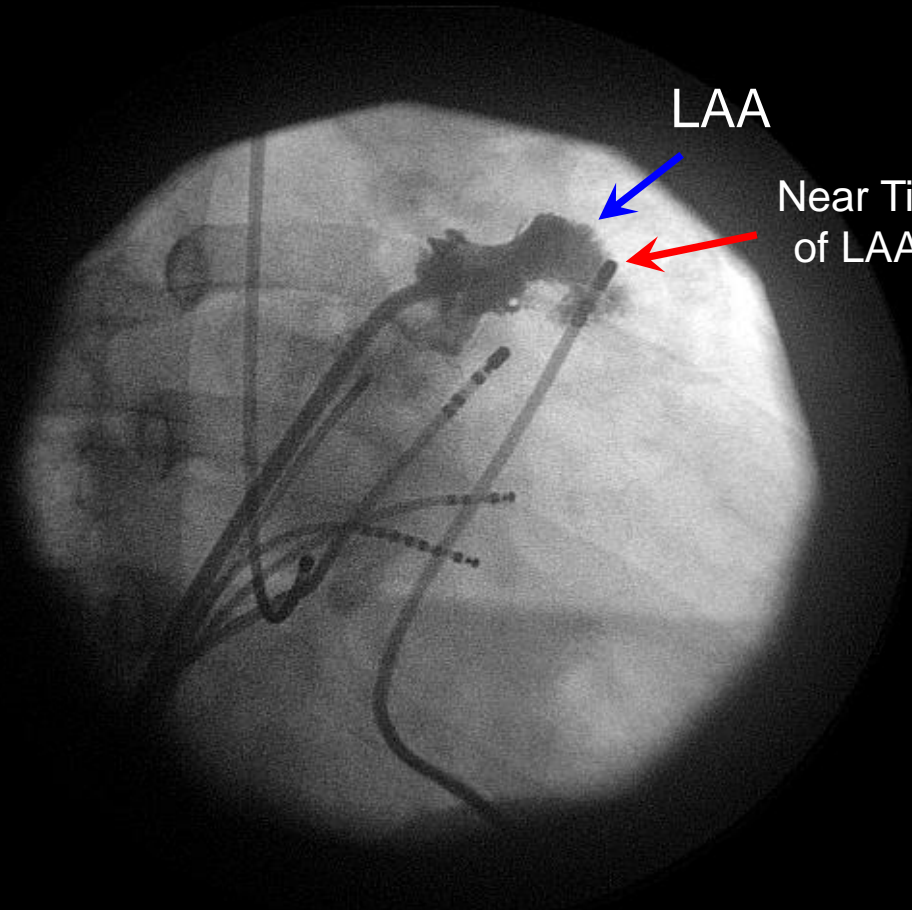


RAO



LAO

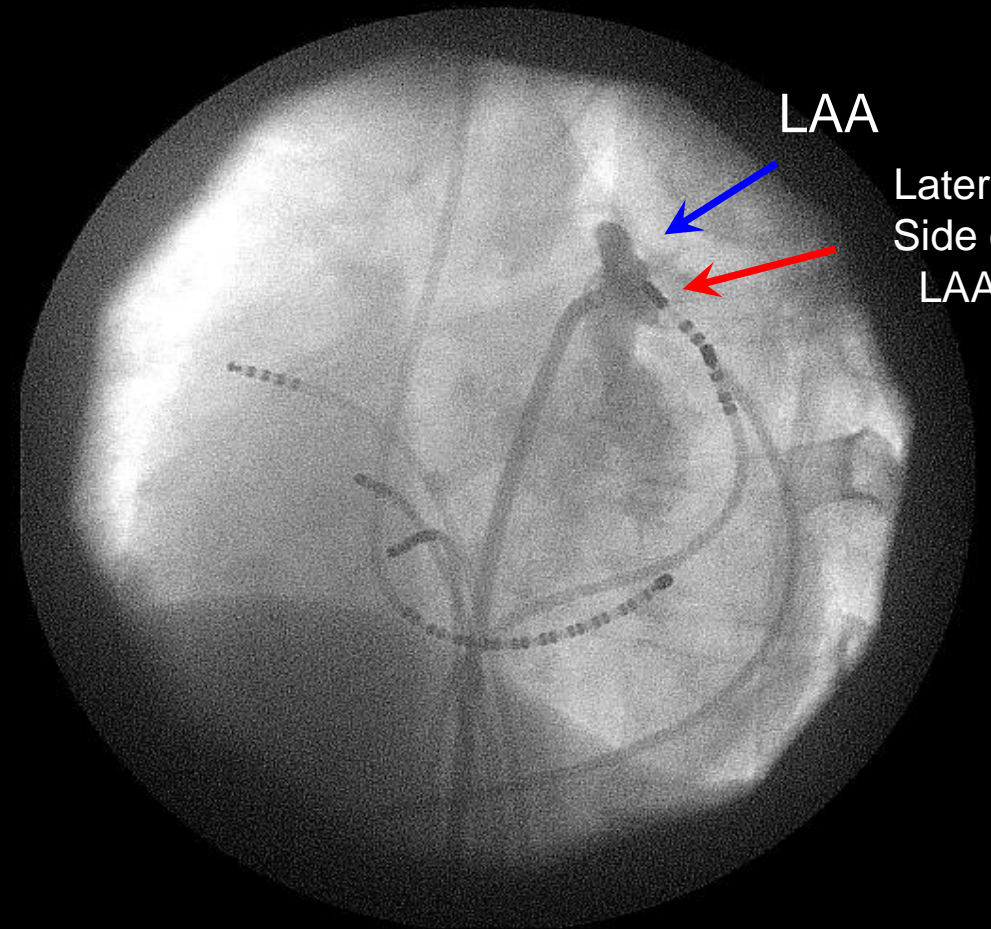
Epicardial Catheter



LAA

Near Tip
of LAA

RAO

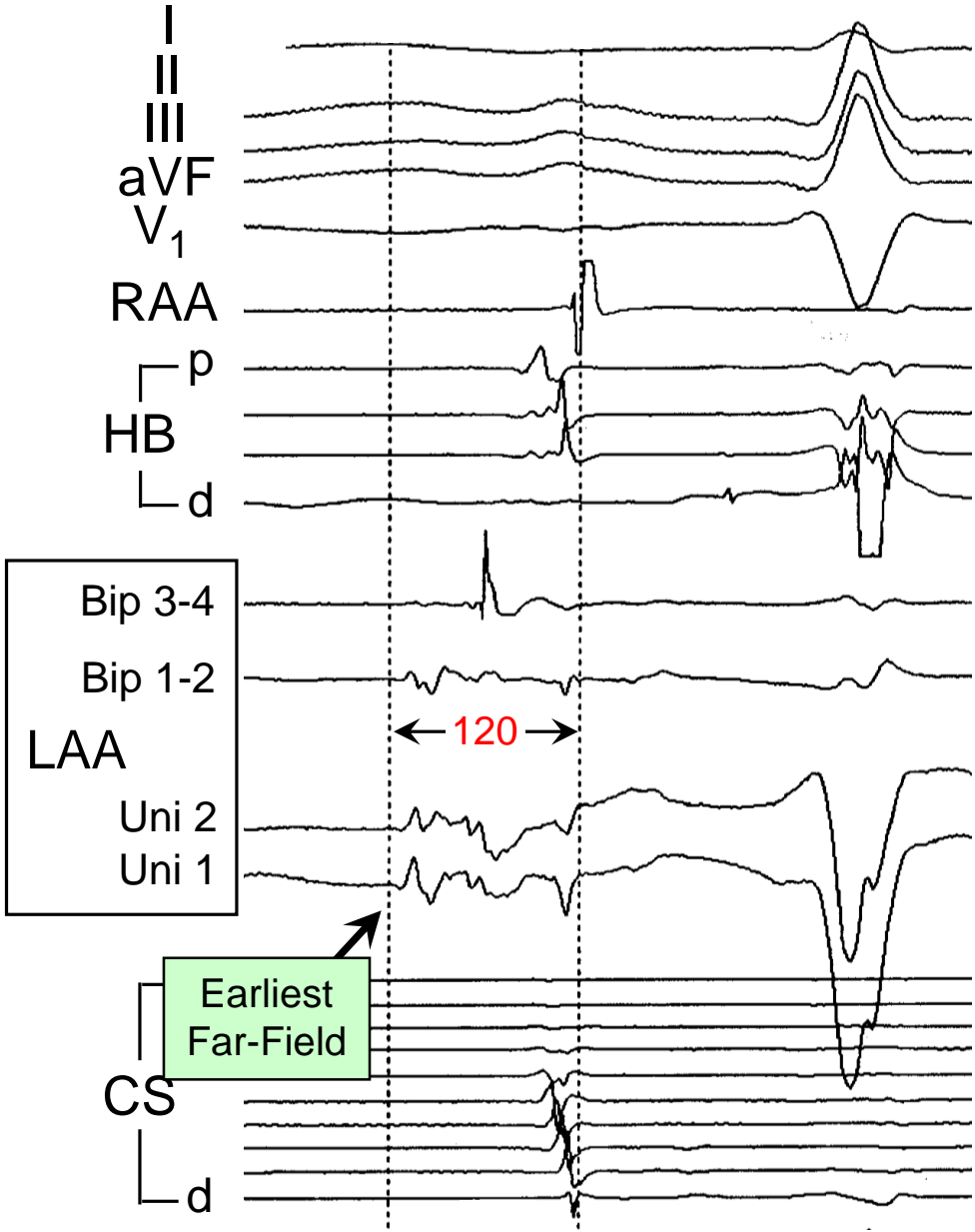


LAA

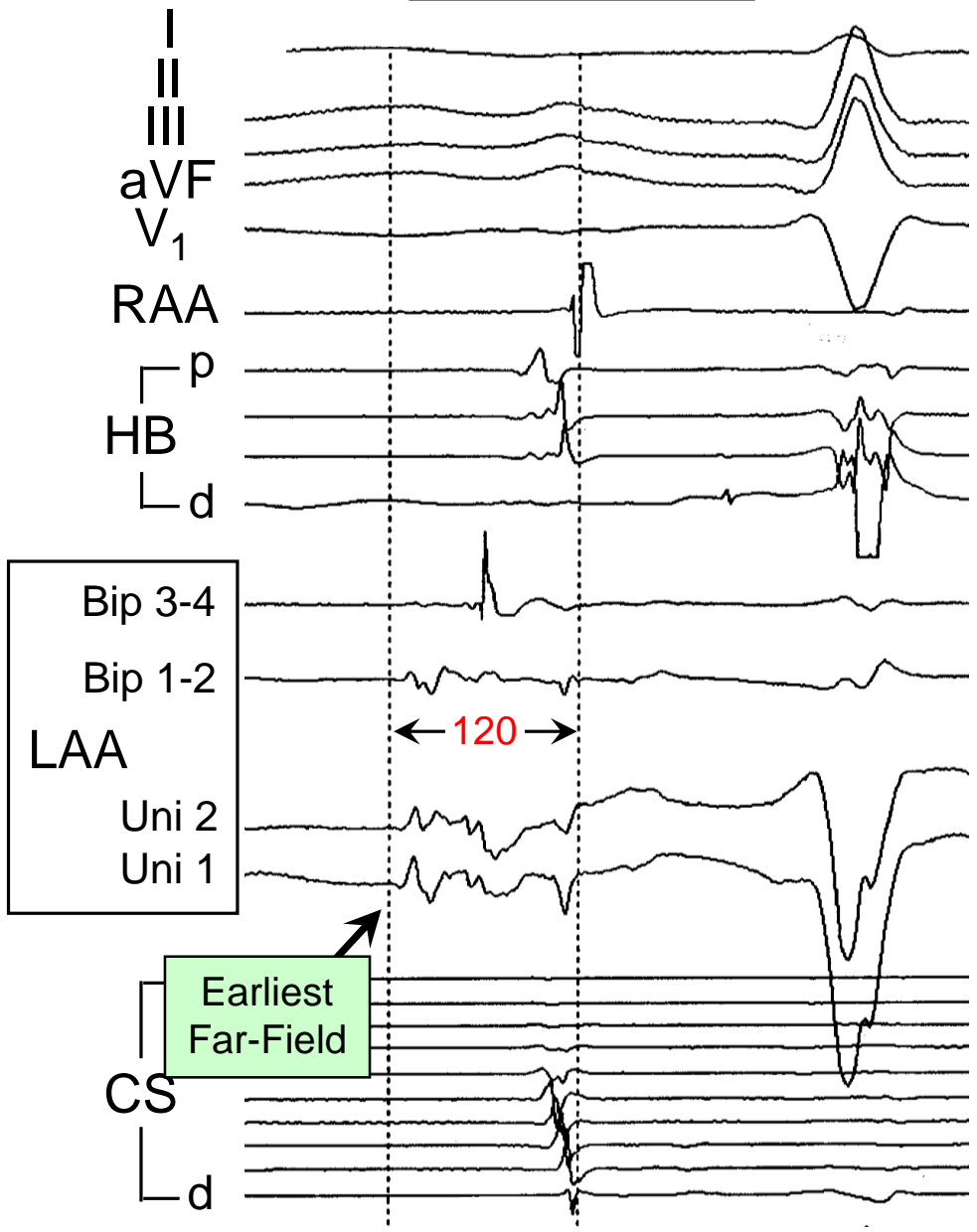
Lateral
Side of
LAA

LAO

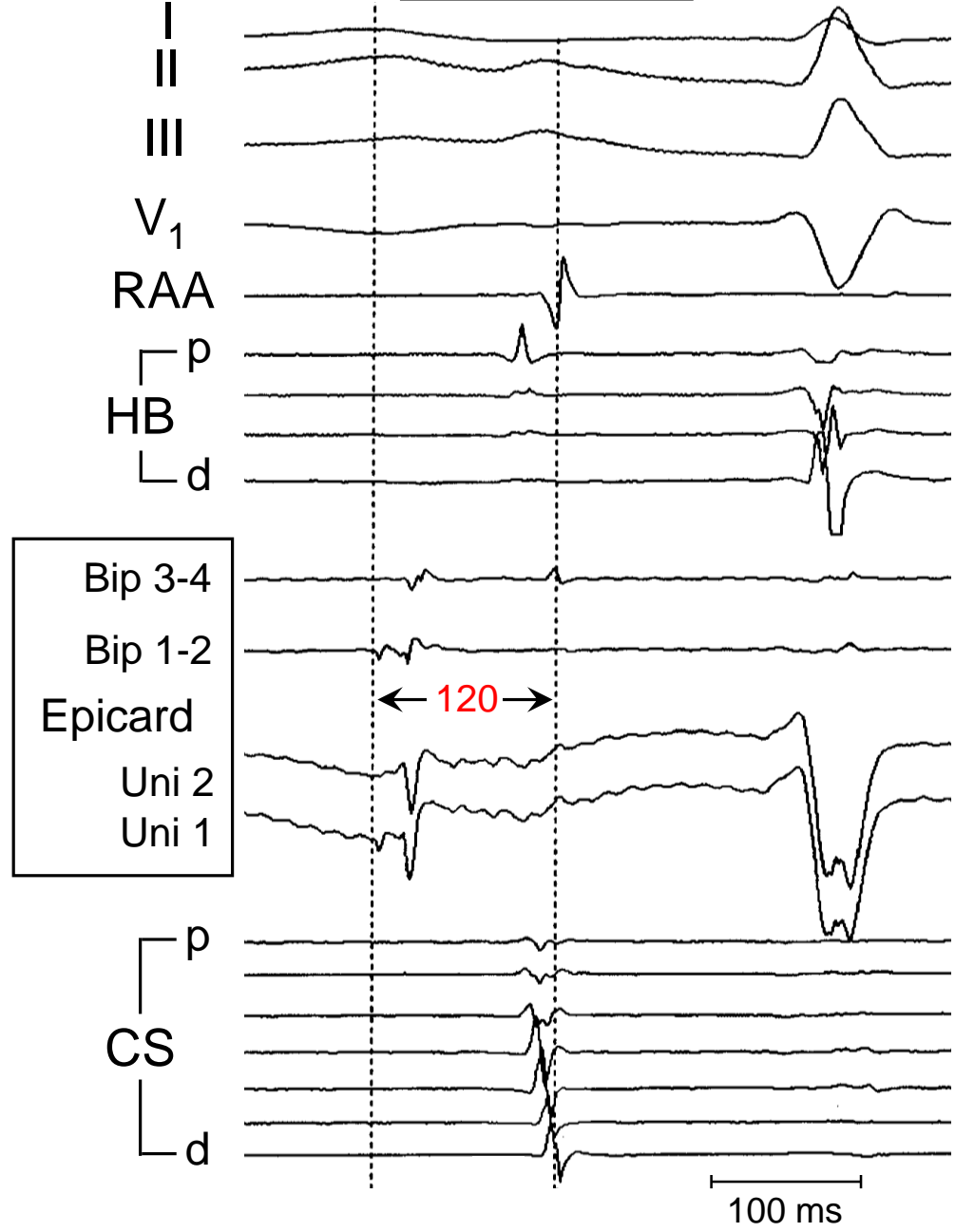
Endocardium



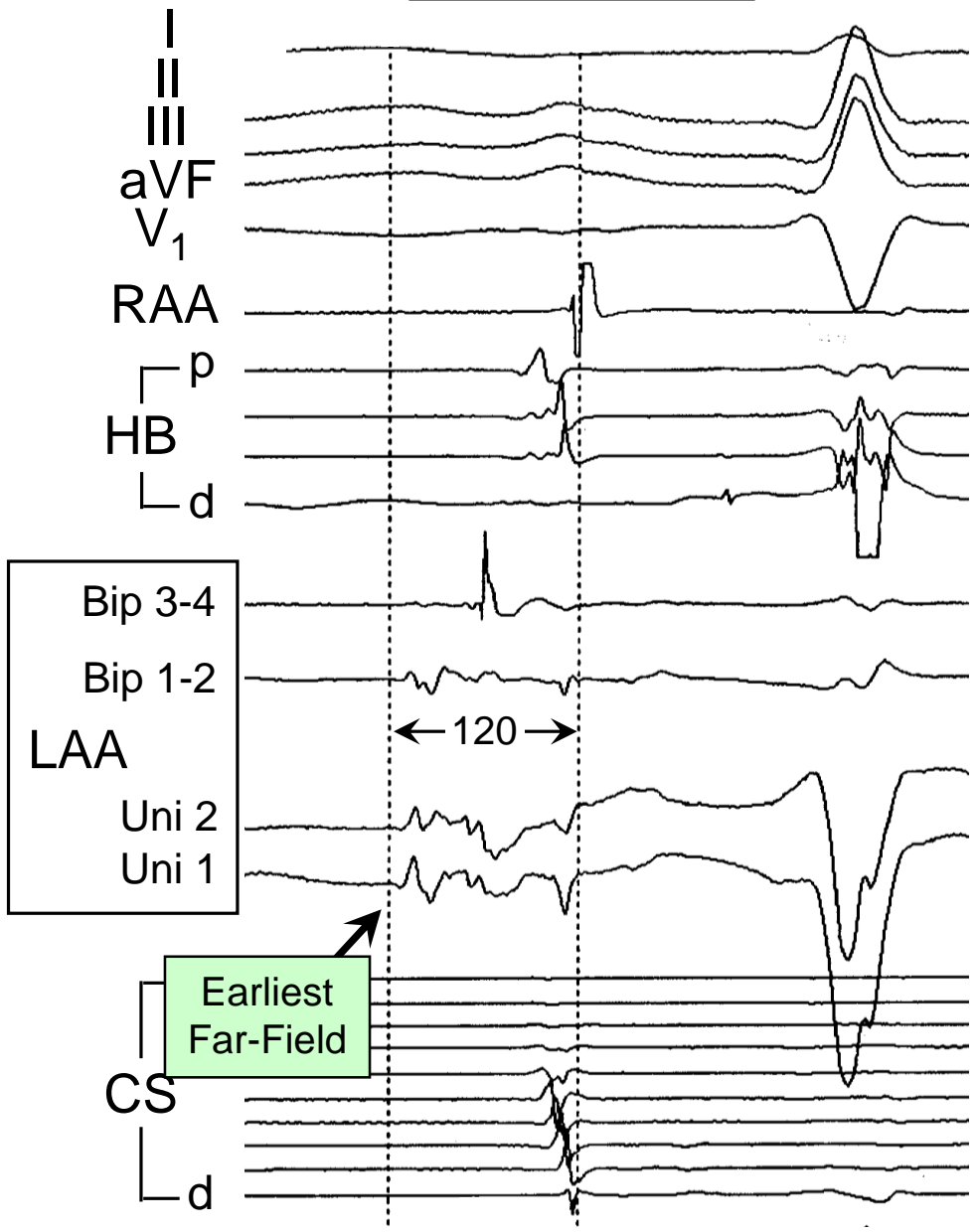
Endocardium



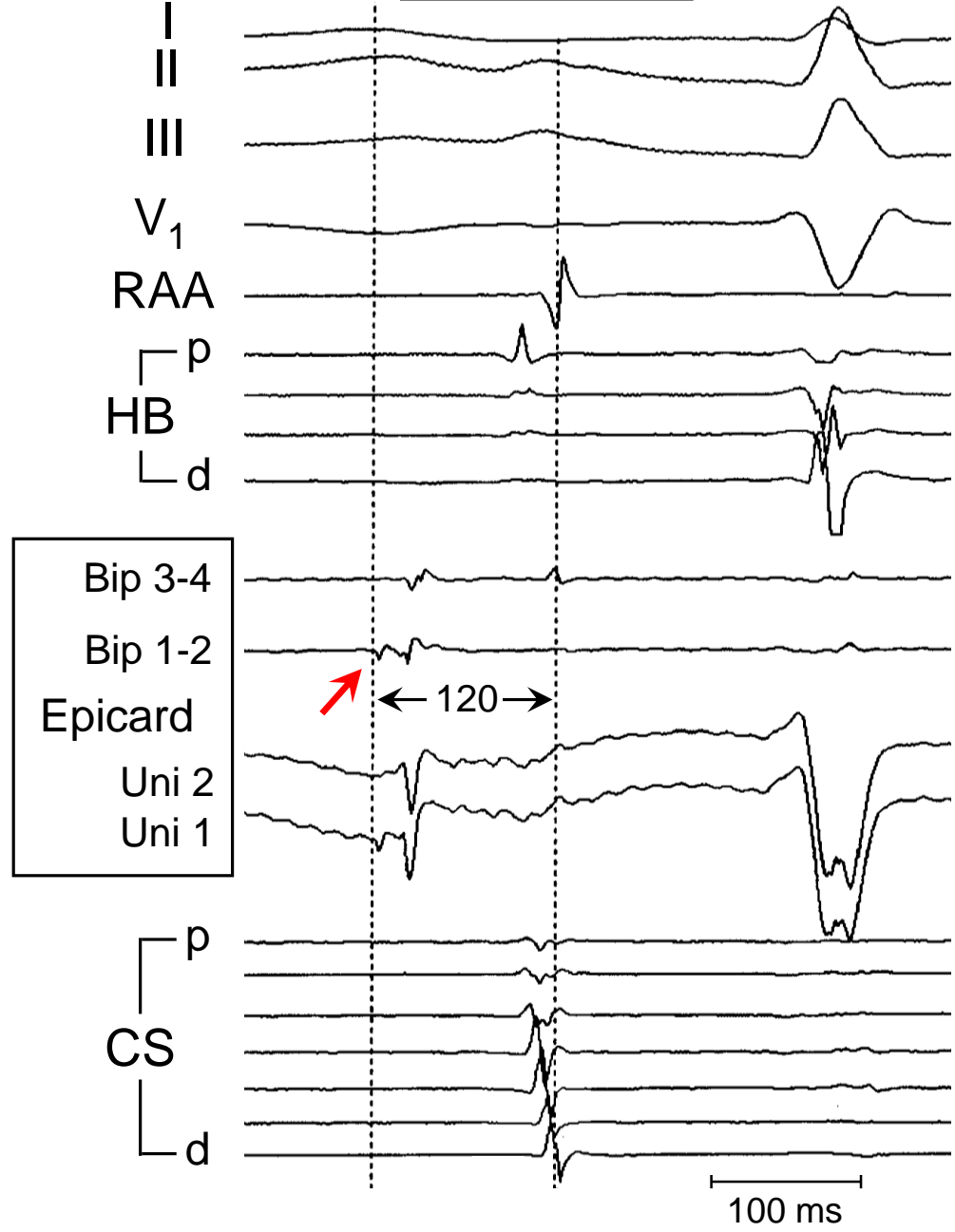
Epicardium



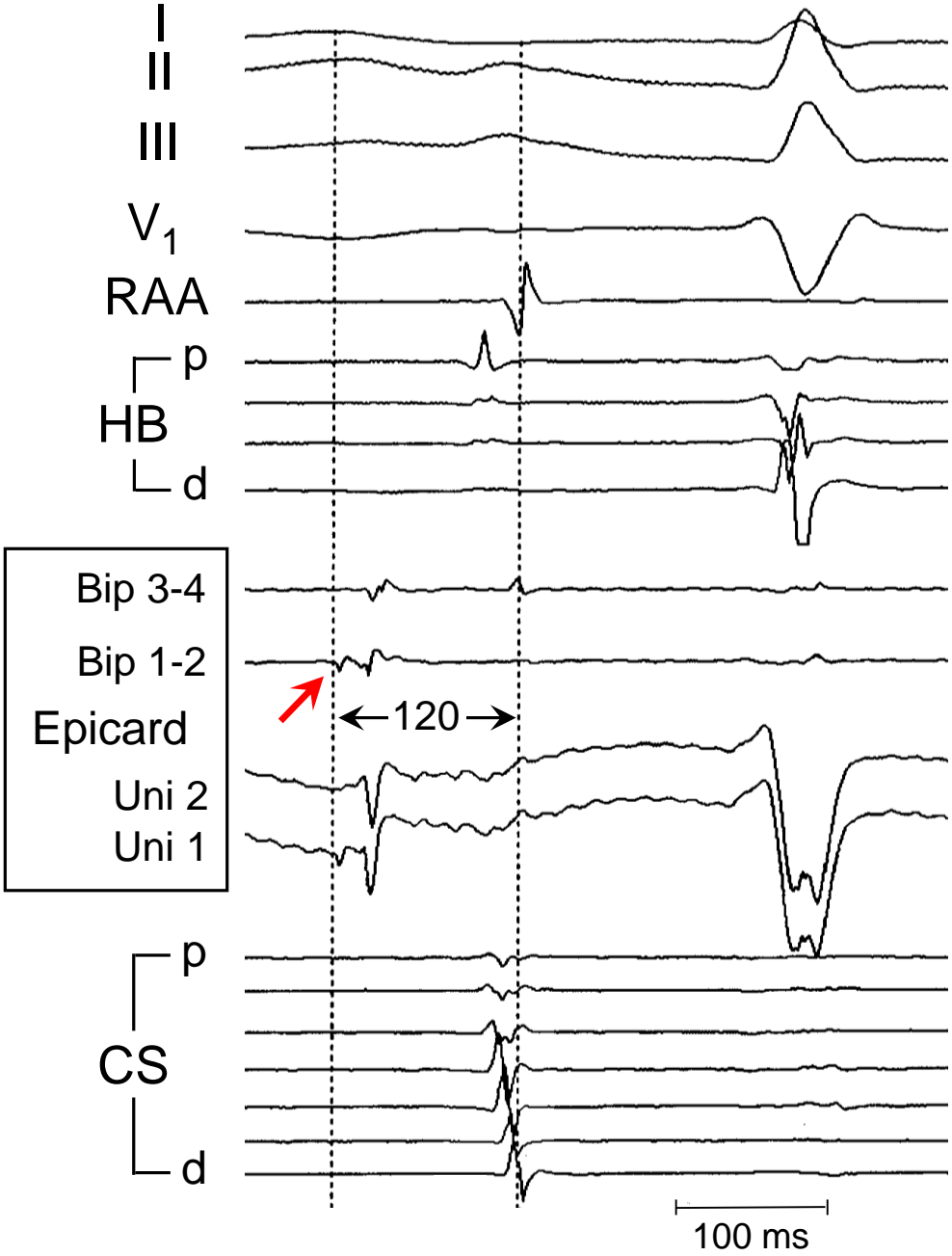
Endocardium



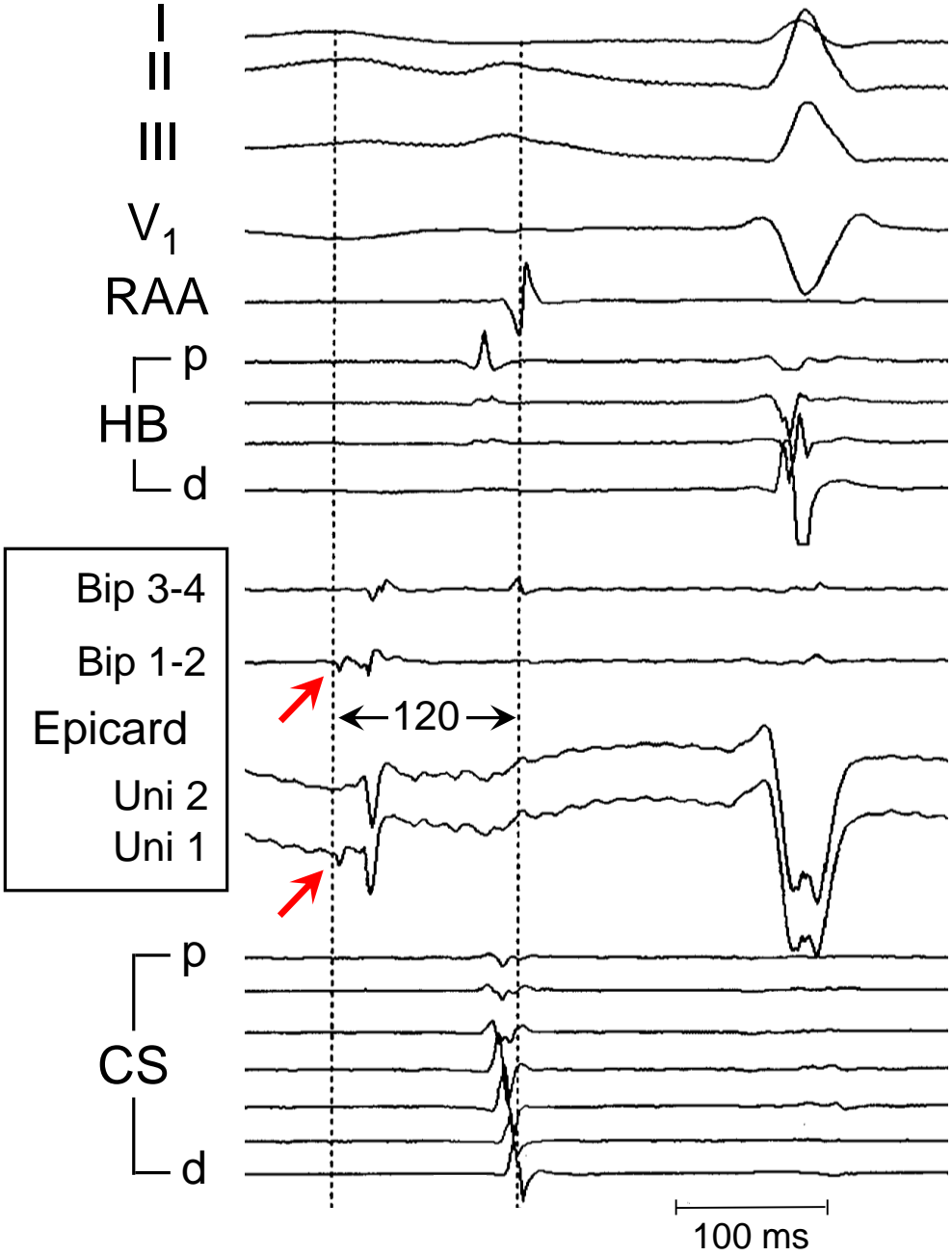
Epicardium



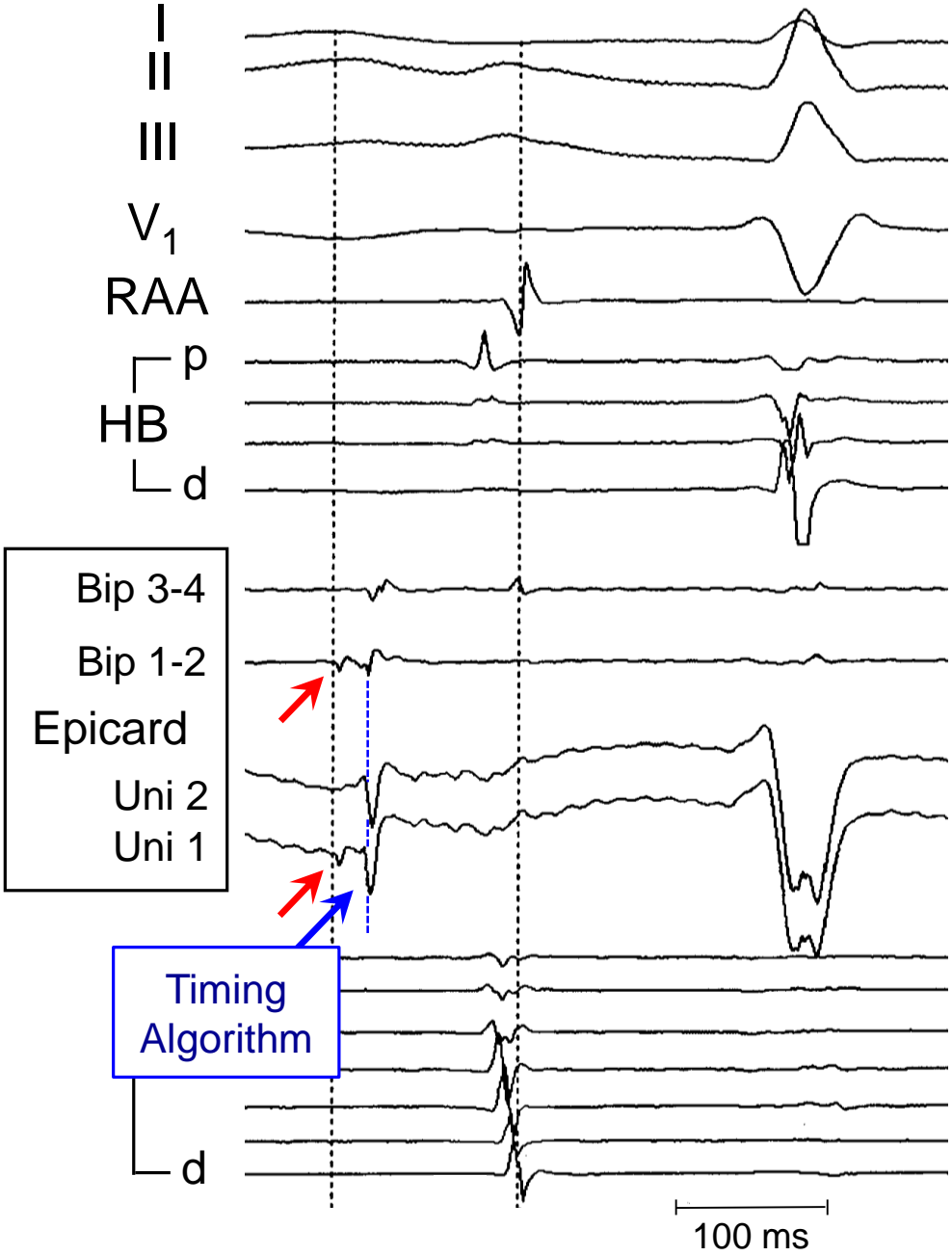
Epicardium



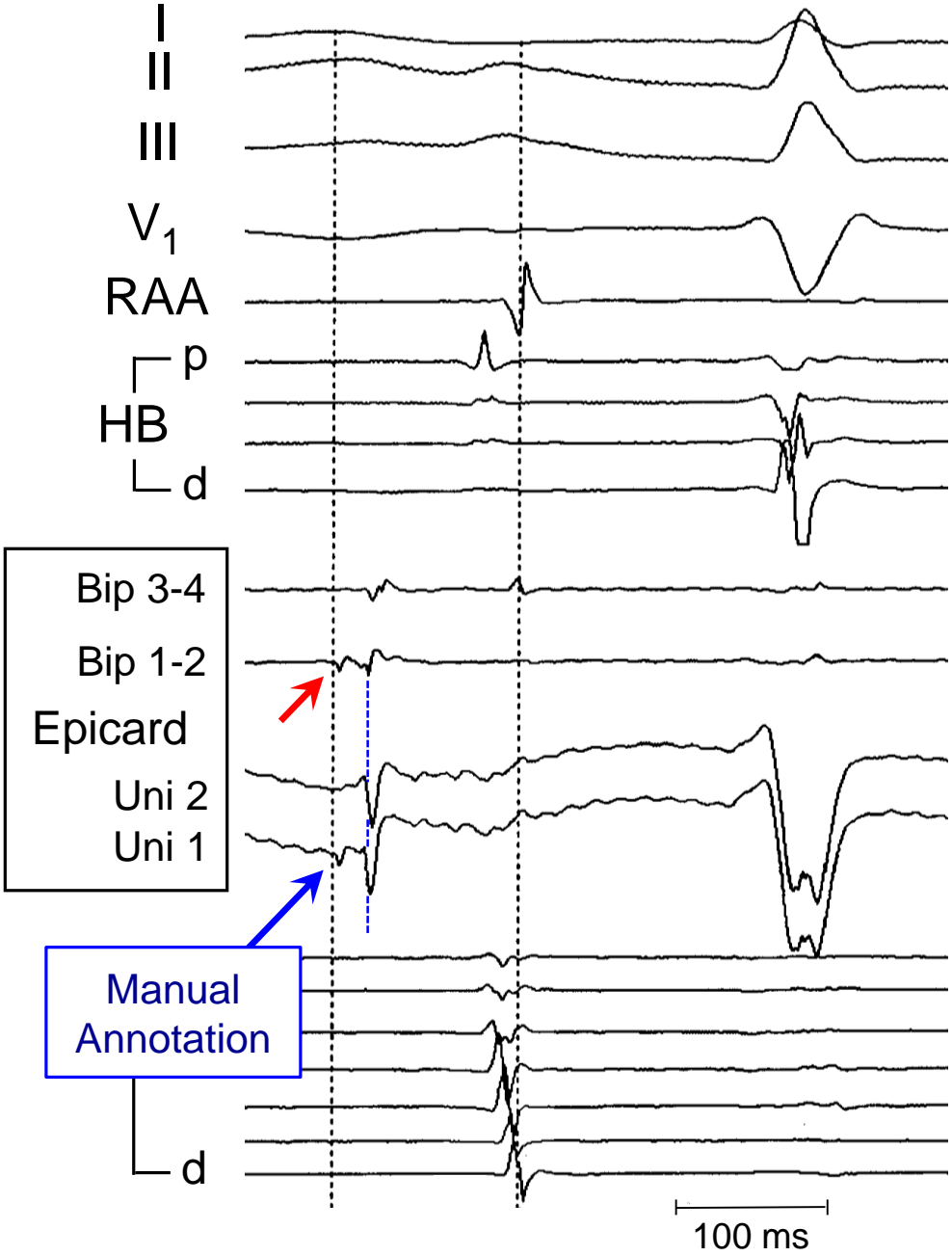
Epicardium



Epicardium



Epicardium

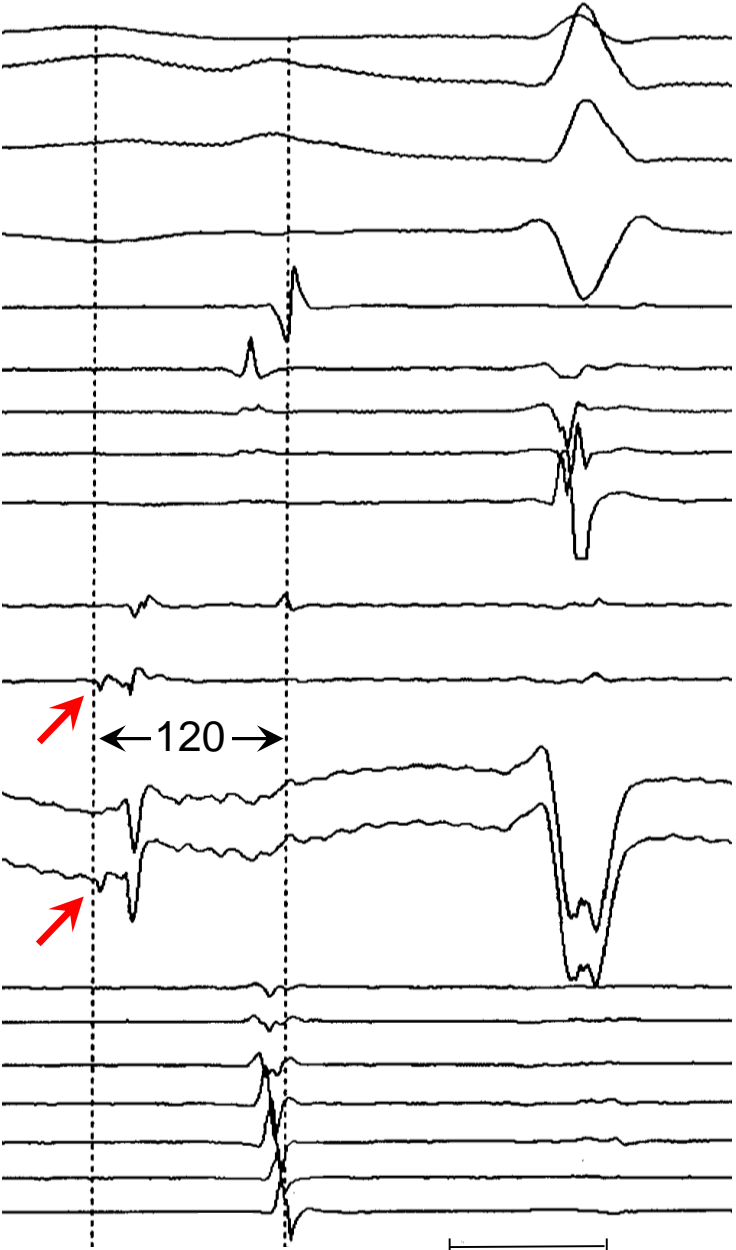


Epicardium

Ablate Here?

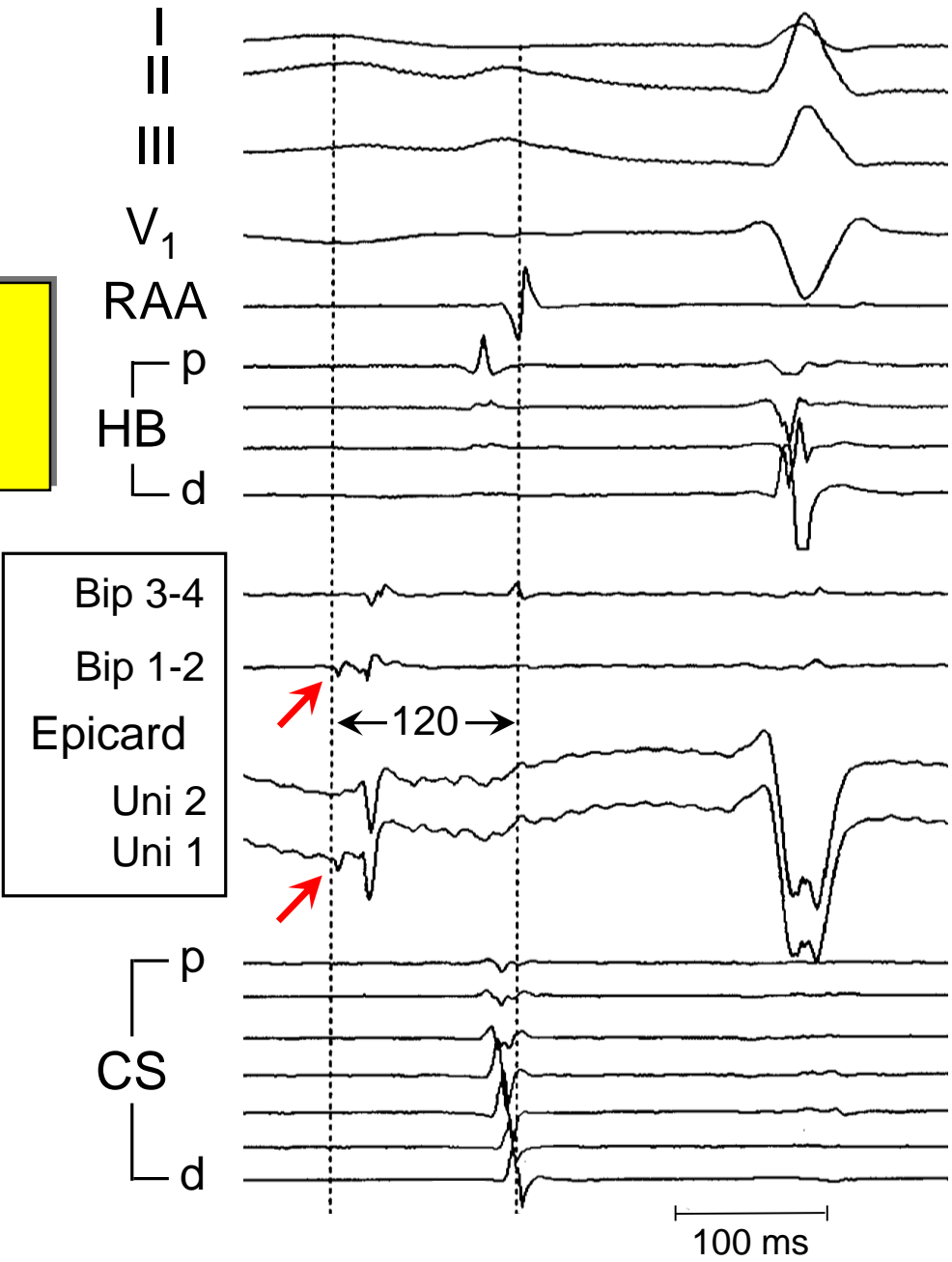
Bip 3-4
Bip 1-2
Epicard
Uni 2
Uni 1

p
CS
d

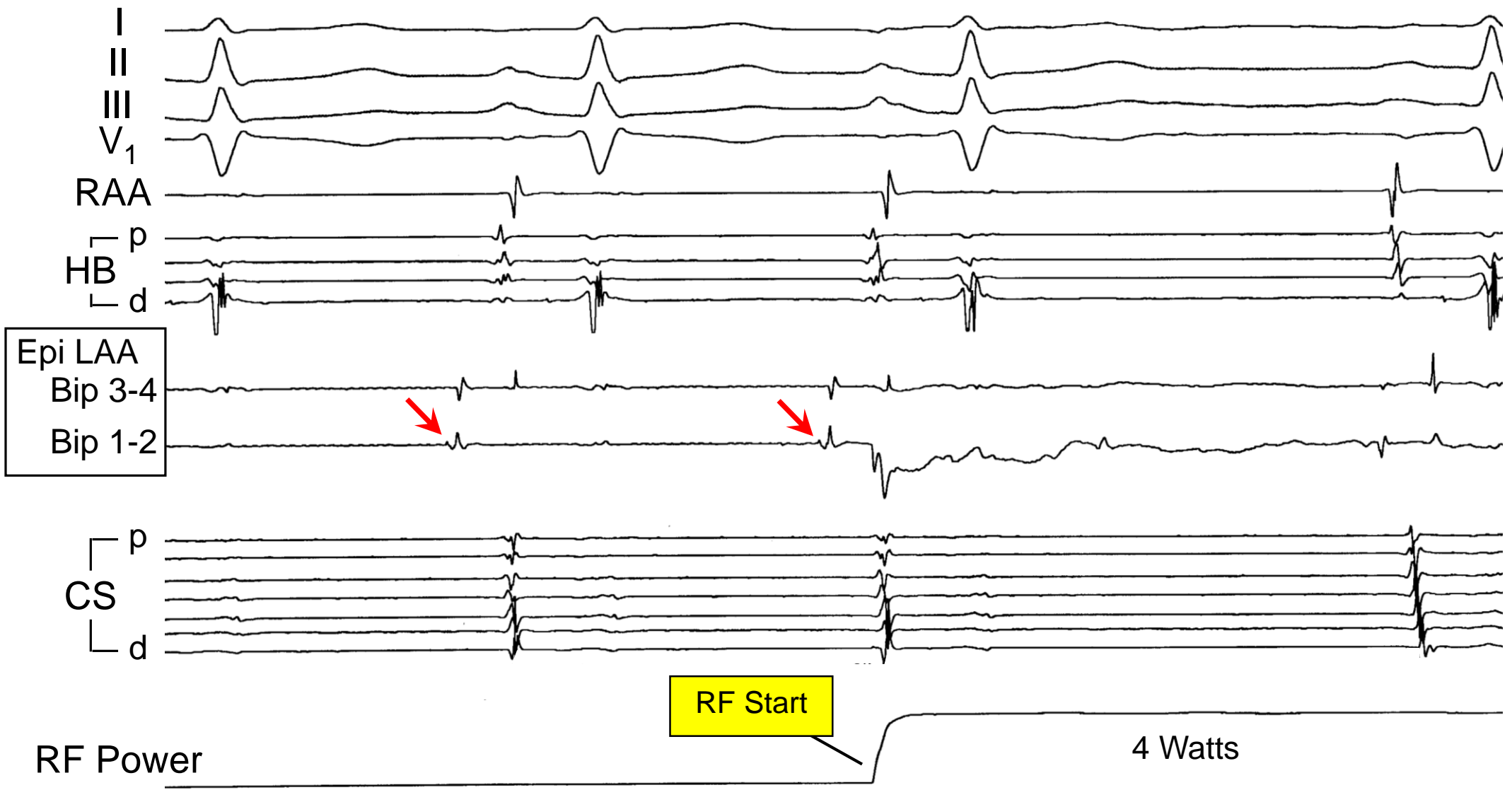


Epicardium

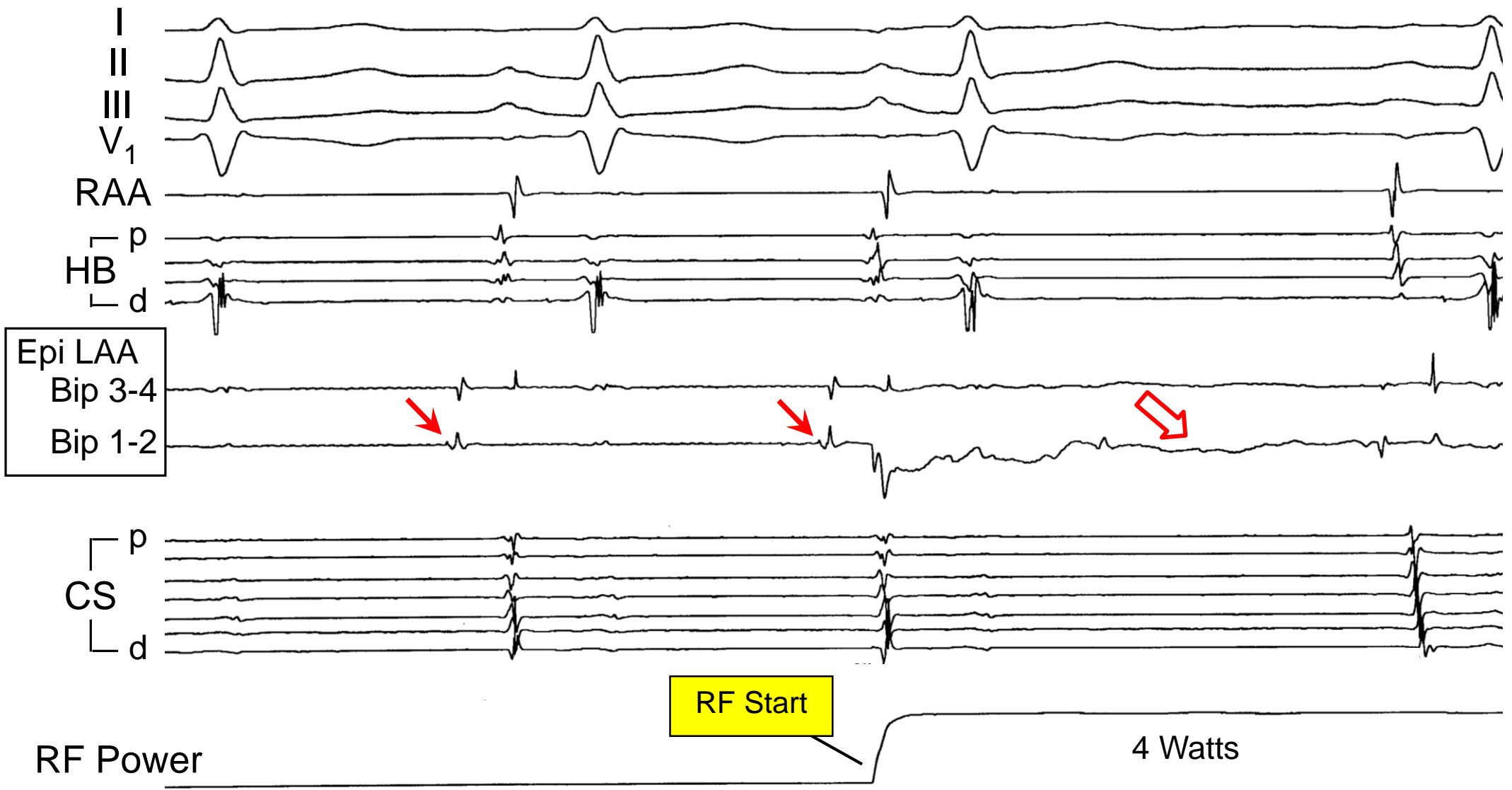
For Ablation:
Sharp Target Potential
on Uni 1



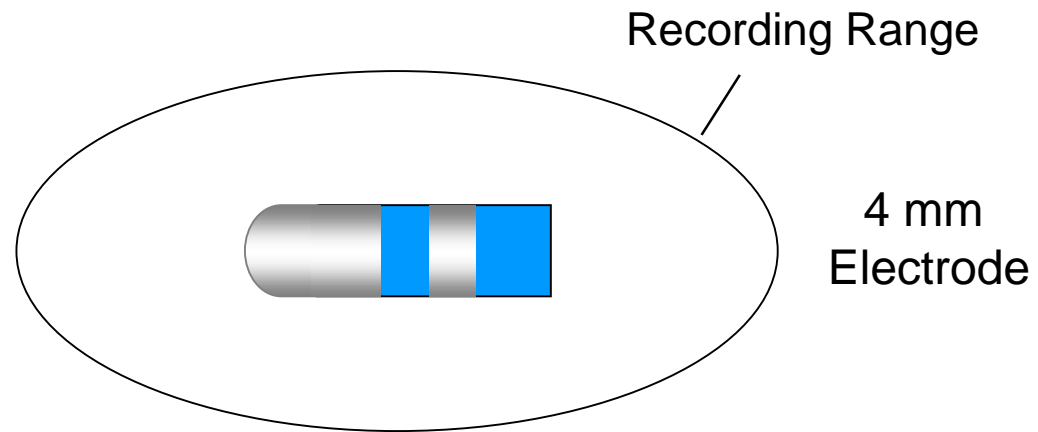
Epicardial Ablation of Left Atrial Appendage Tachycardia



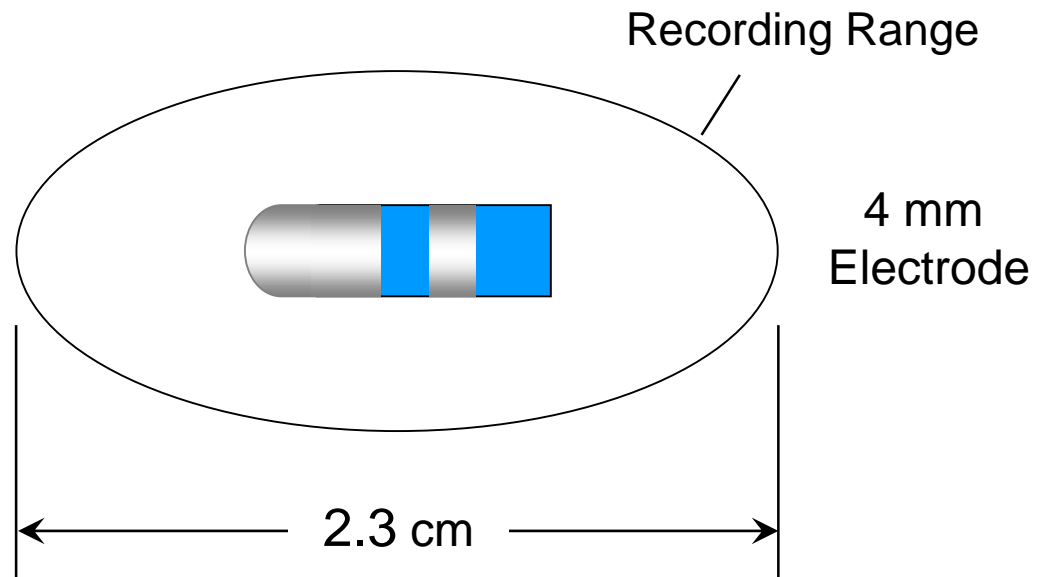
Epicardial Ablation of Left Atrial Appendage Tachycardia



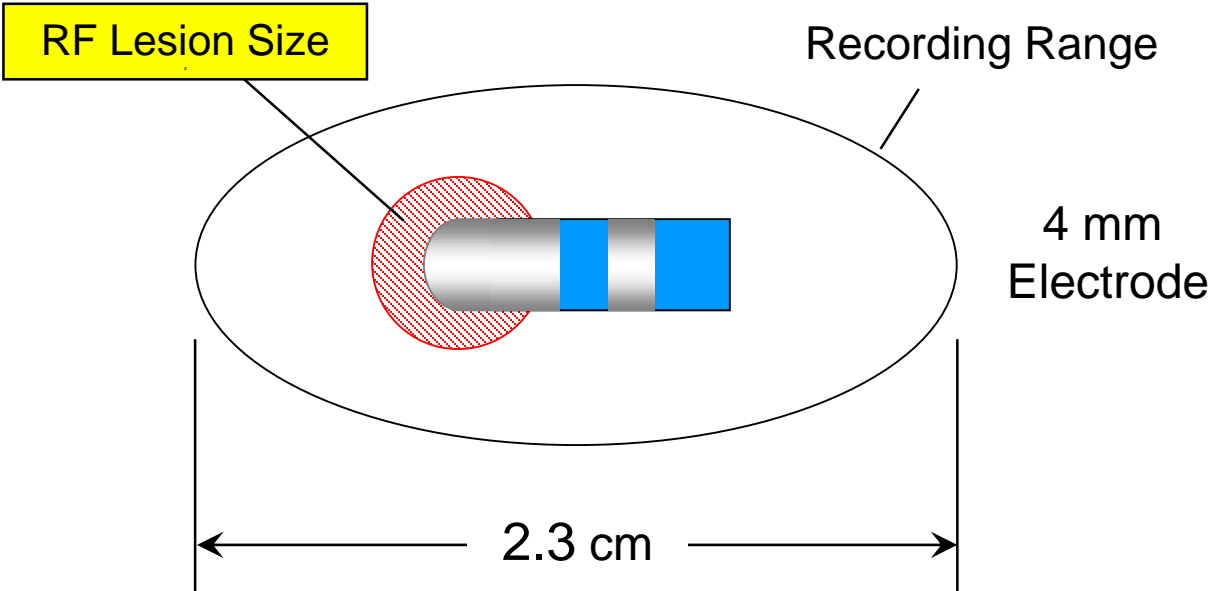
Ablation Catheter - Bipolar Electrogram



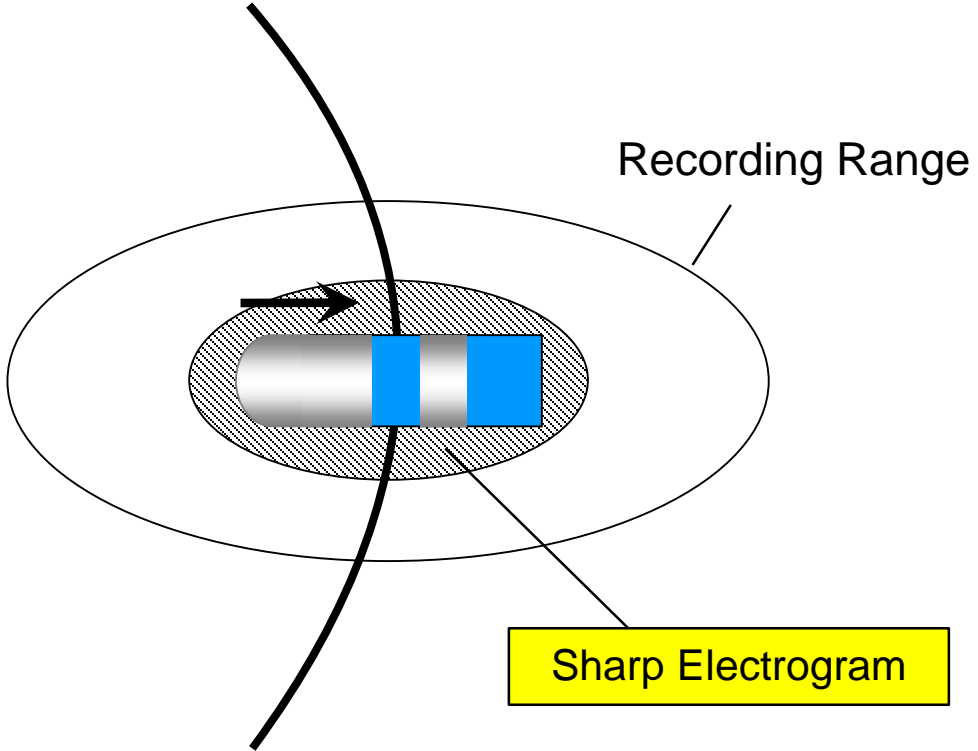
Ablation Catheter - Bipolar Electrogram



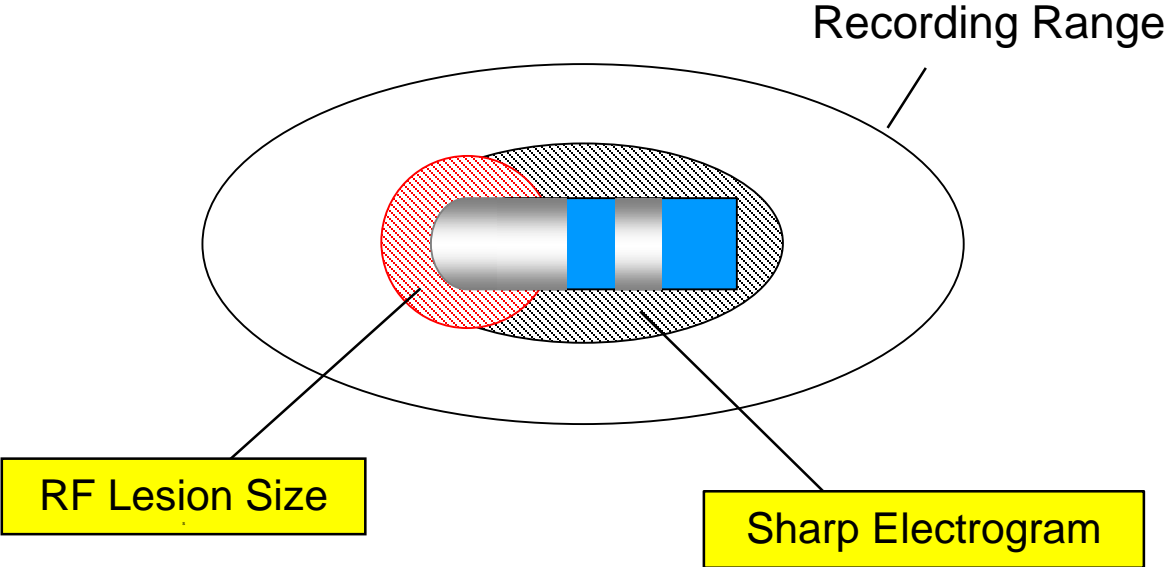
Ablation Catheter - Bipolar Electrogram



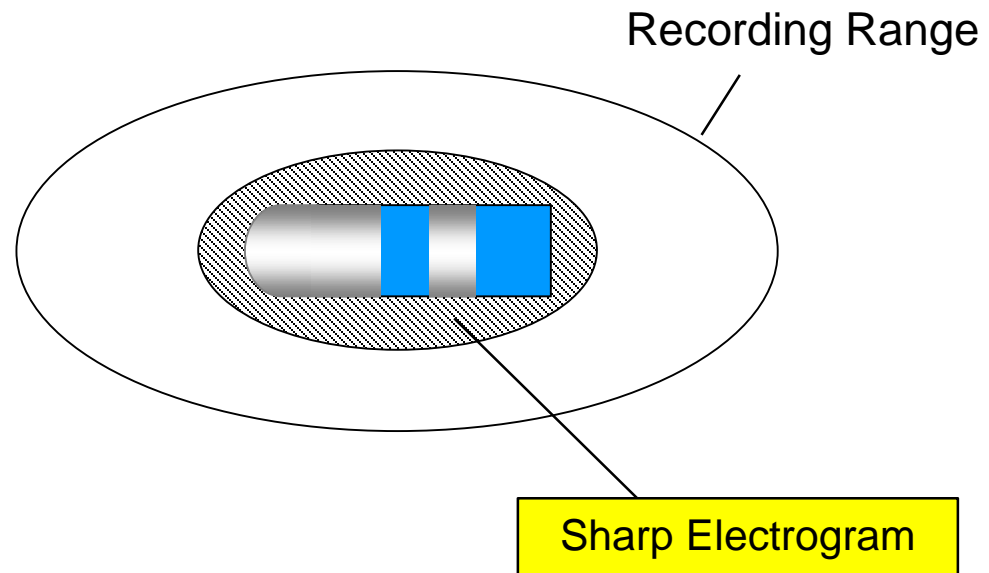
Ablation Catheter - Bipolar Electrogram



Ablation Catheter - Bipolar Electrogram

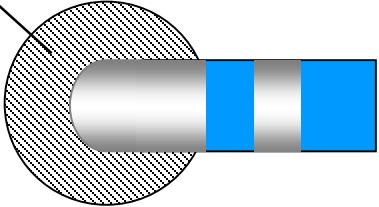


Ablation Catheter - Bipolar Electrogram



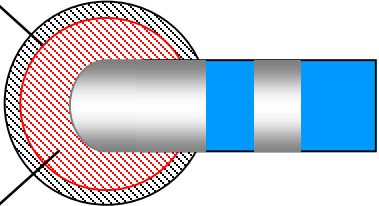
Ablation Catheter - Unipolar Electrogram

Area of Sharp Potential on Unipolar Electrogram



Ablation Catheter - Unipolar Electrogram

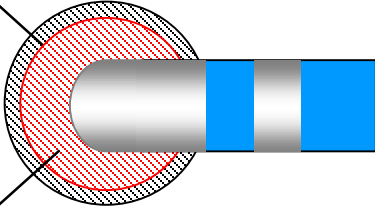
Area of Sharp Potential on Unipolar Electrogram



RF Lesion Size

Ablation Catheter - Unipolar Electrogram

Area of Sharp Potential on Unipolar Electrogram



RF Lesion Size

Final Targeting Should be Based on Uni 1 EGM



Unipolar Electrogram

- ⊕ Mapping Electrode
- ⊖ Reference Electrode (Out of Chest)

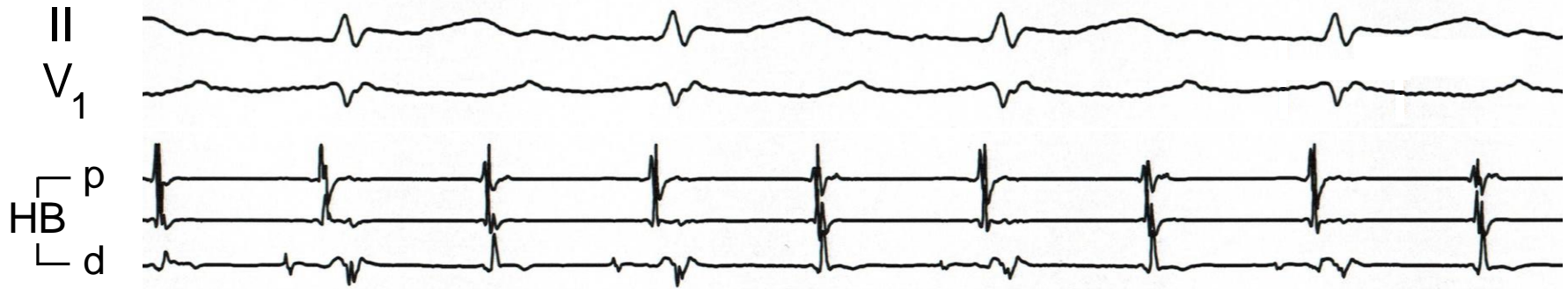

Unipolar Electrogram

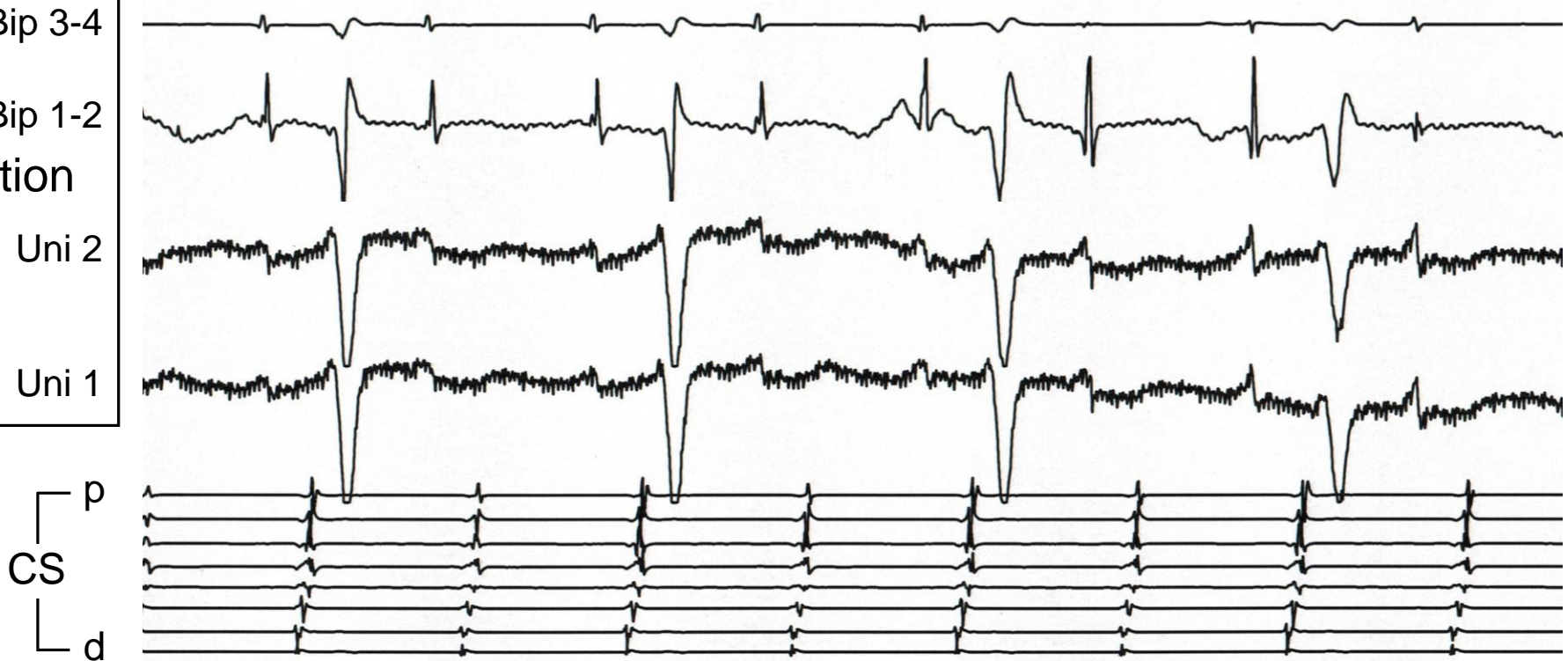
- ⊕ Mapping Electrode
- ⊖ Reference Electrode (Out of Chest)

Wilson Central Terminal

Unipolar Reference - Wilson Central Terminal



Bip 3-4
Bip 1-2
Ablation
Uni 2
Uni 1





Unipolar Electrogram

- ⊕ Mapping Electrode
- ⊖ Reference Electrode (Out of Chest)

Wilson Central Terminal

High 60 Hz Noise



Unipolar Electrogram

- ⊕ Mapping Electrode
- ⊖ Reference Electrode (Out of Chest)

Wilson Central Terminal

High 60 Hz Noise → Notch Filter

Unipolar Electrogram (Tricuspid Annulus)


Notch Filter: OFF



100 ms

Unipolar Electrogram (Tricuspid Annulus)

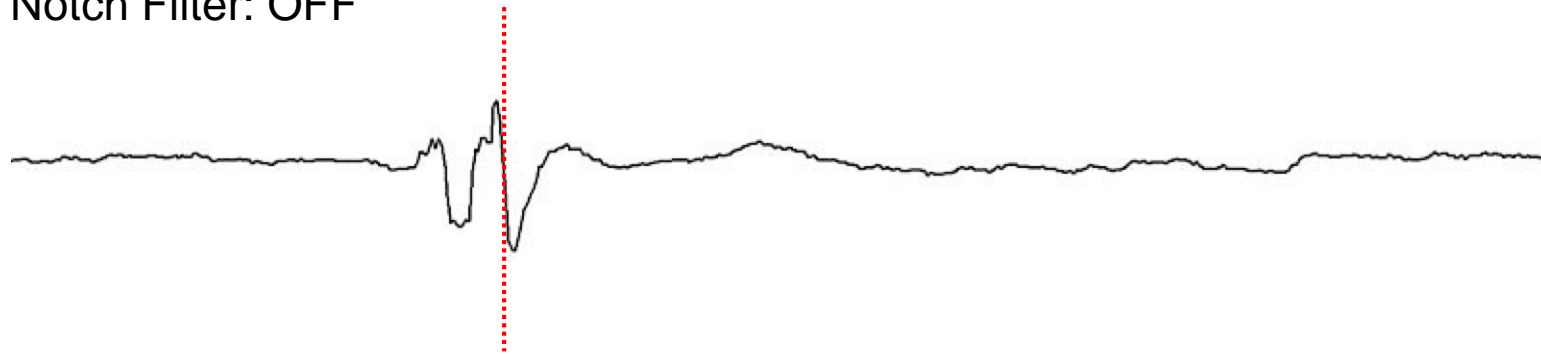
Notch Filter: OFF



100 ms

Unipolar Electrogram (Tricuspid Annulus)

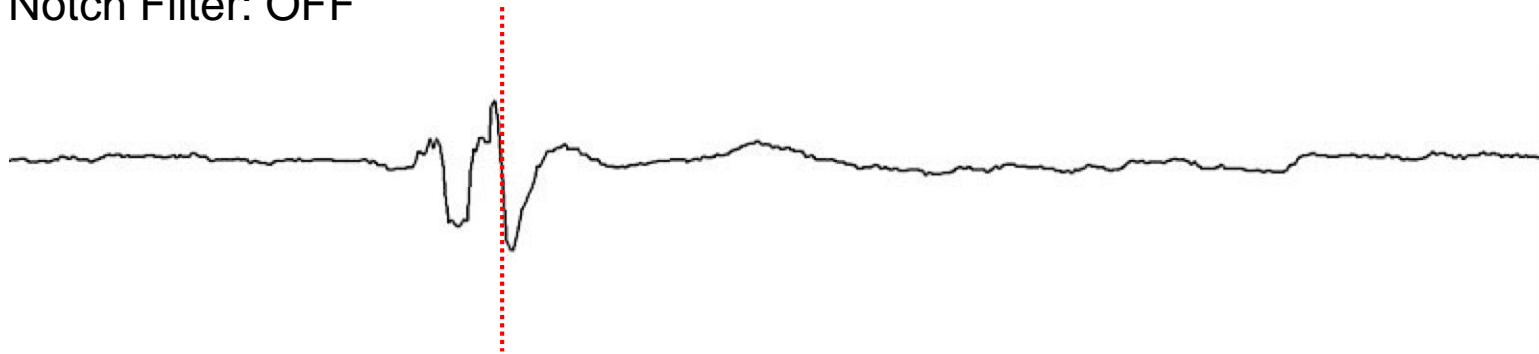
Notch Filter: OFF



100 ms

Unipolar Electrogram (Tricuspid Annulus)

Notch Filter: OFF

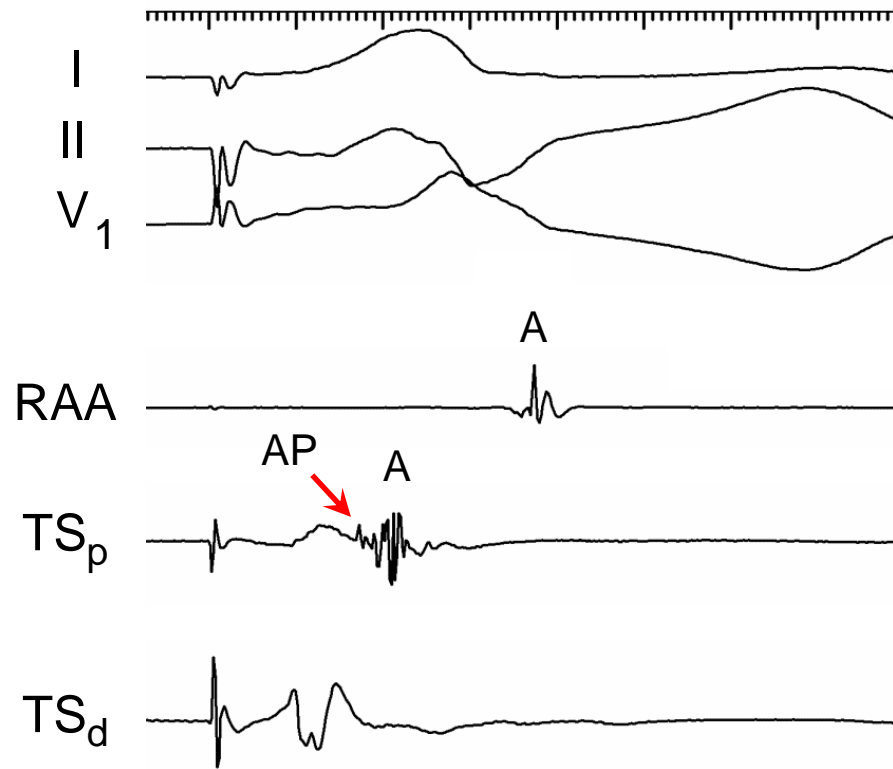


Notch Filter: ON



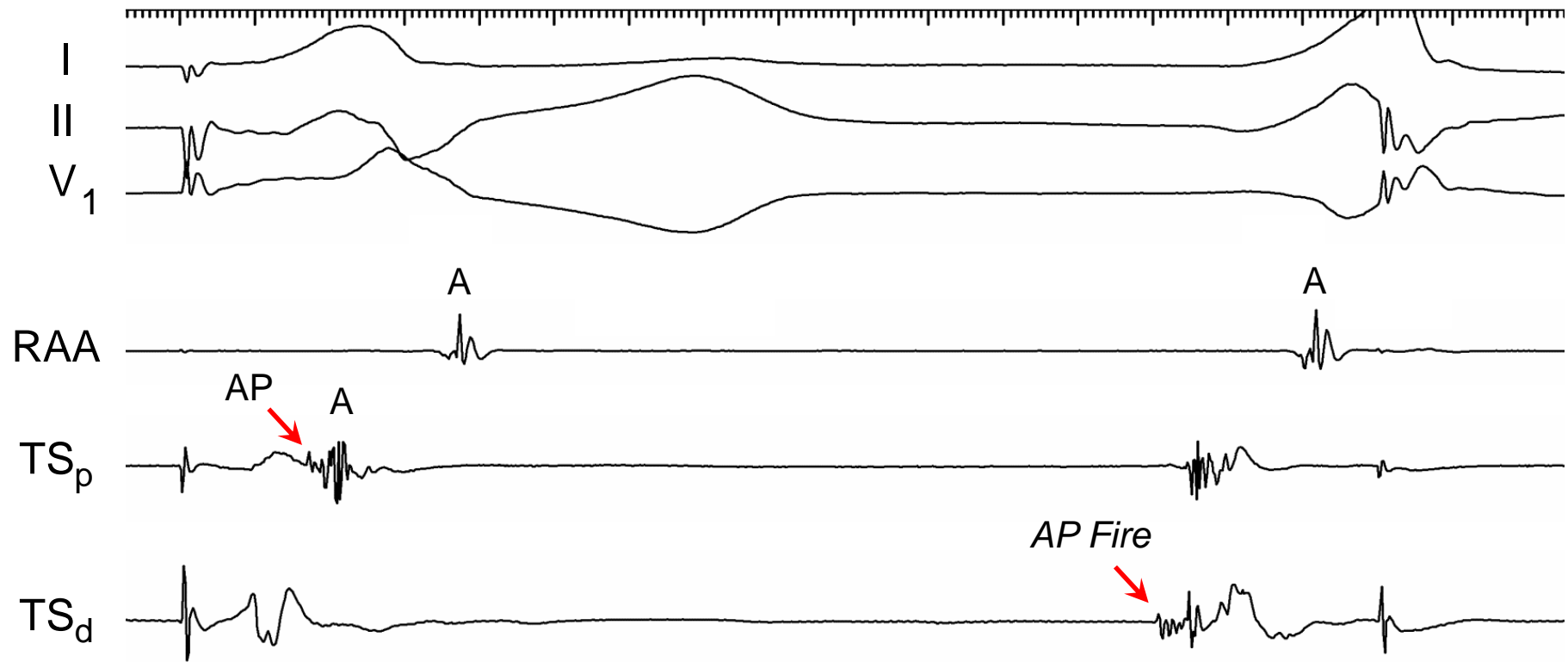
100 ms

Left Midseptal Accessory Pathway

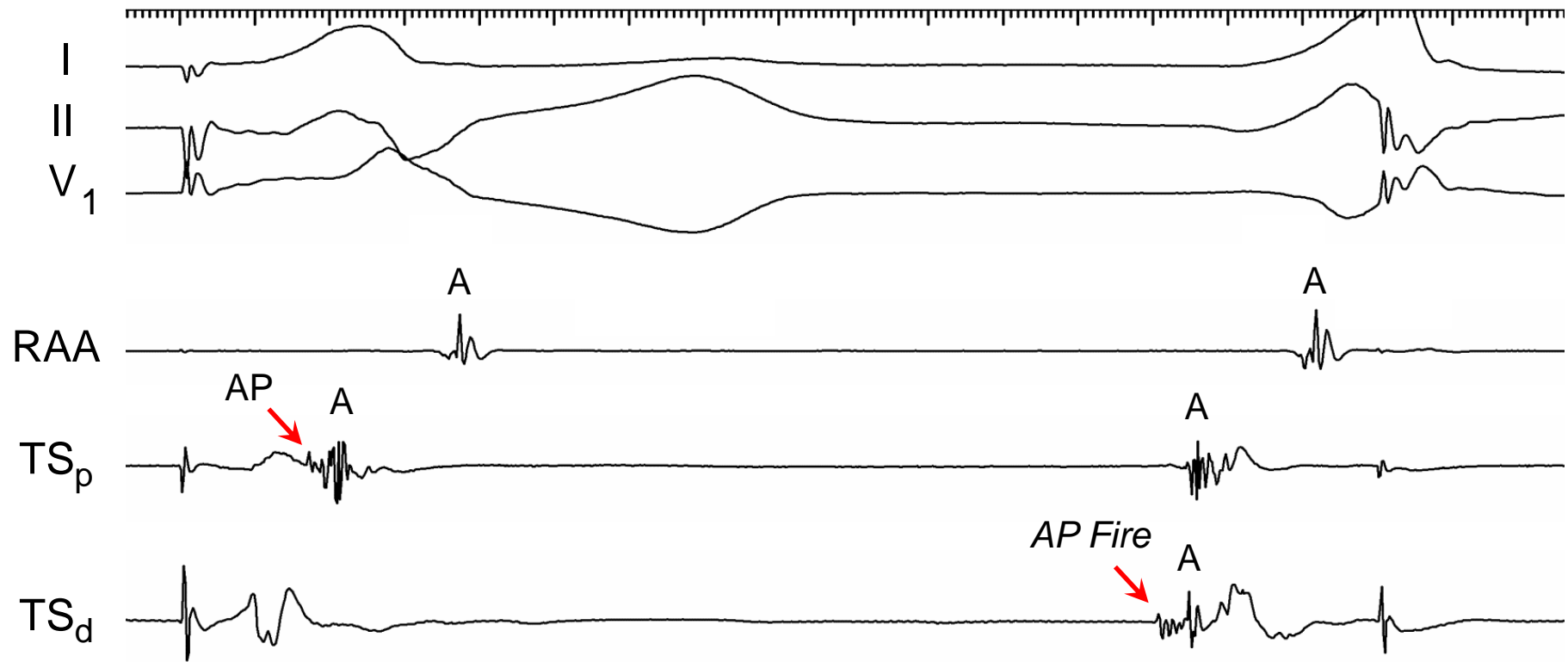


Courtesy Elad Anter

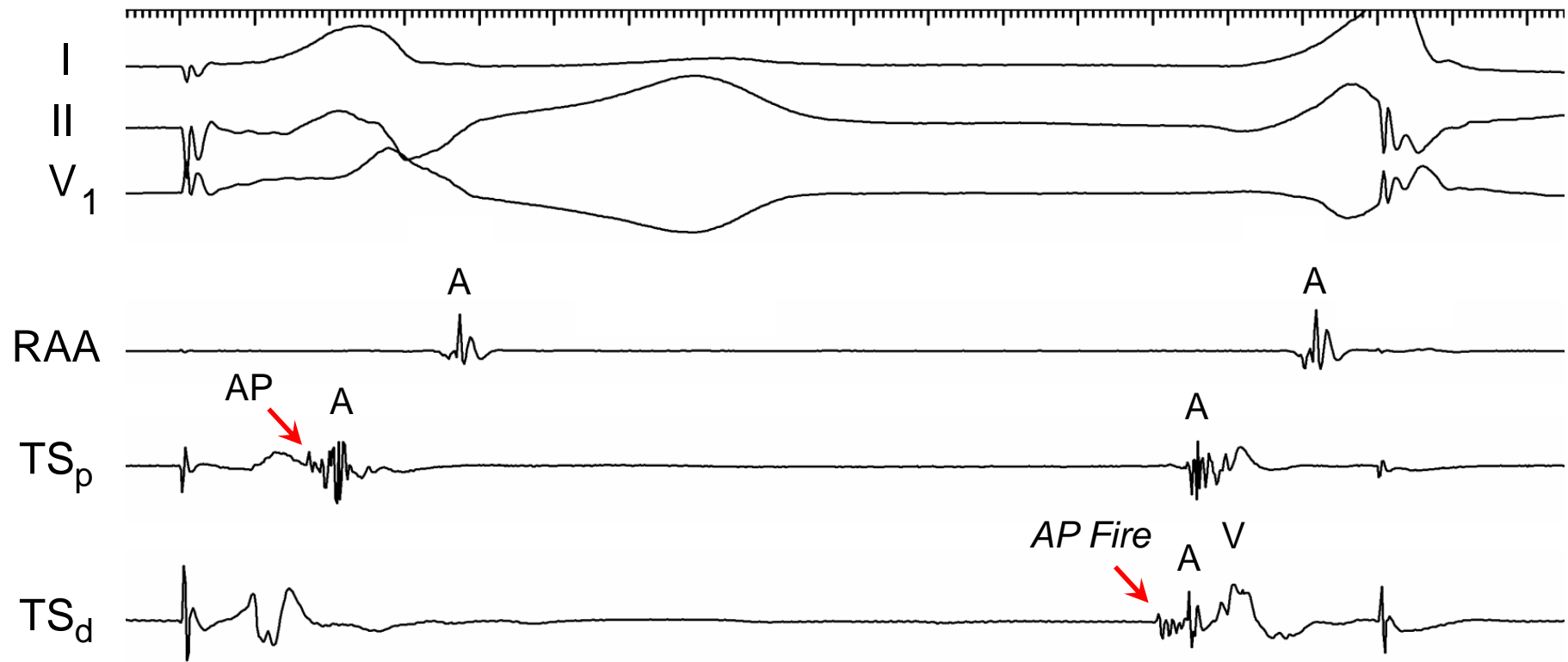
Left Midseptal Accessory Pathway



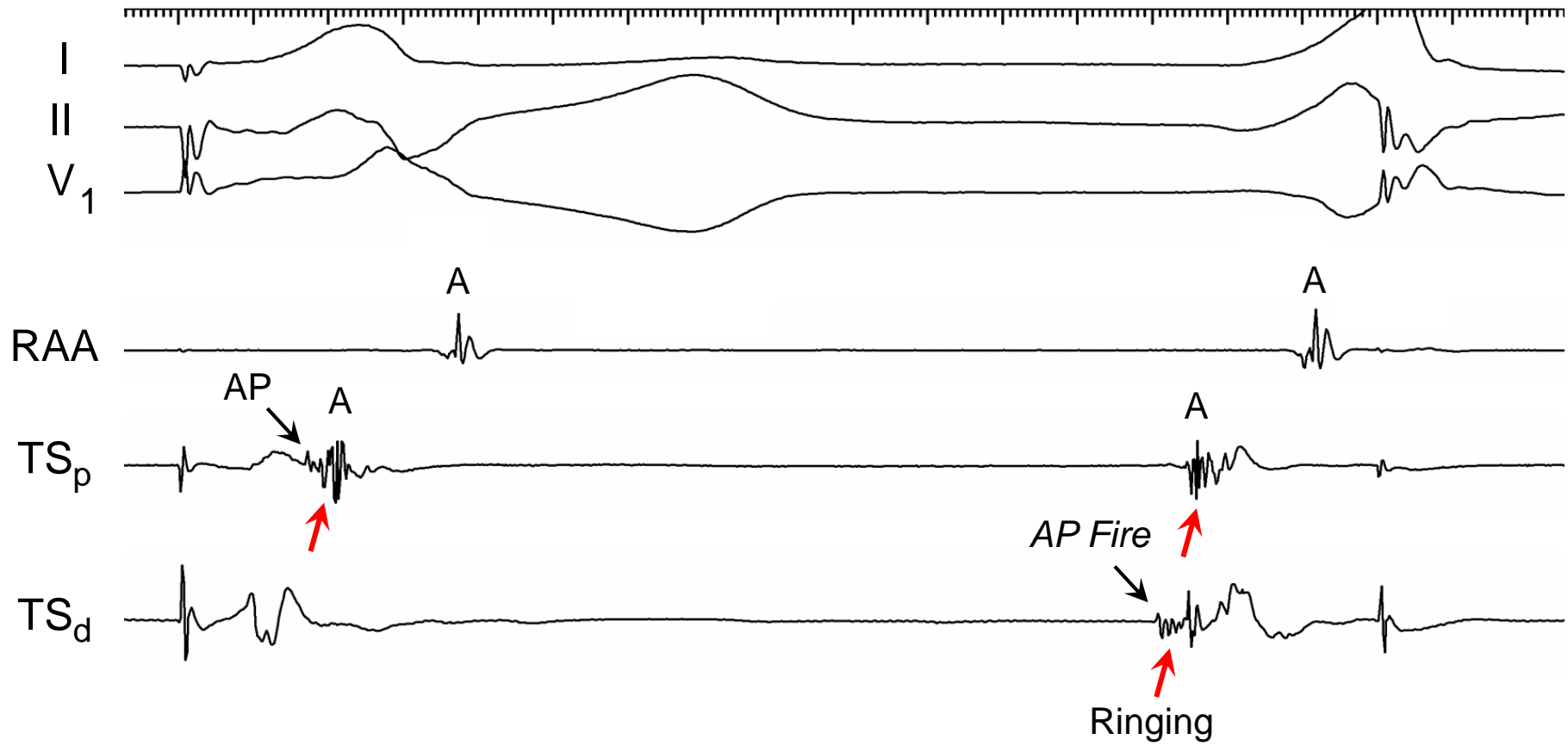
Left Midseptal Accessory Pathway



Left Midseptal Accessory Pathway



Left Midseptal Accessory Pathway





Unipolar Electrogram

- ⊕ Mapping Electrode
- ⊖ Reference Electrode (Out of Chest)

Wilson Central Terminal

High 60 Hz Noise → ~~Notch Filter~~



Unipolar Electrogram

- ⊕ Mapping Electrode
- ⊖ Reference Electrode (Out of Chest)

Wilson Central Terminal

High 60 Hz Noise → ~~Notch Filter~~

IVC Electrode



Unipolar Electrogram

- ⊕ Mapping Electrode
- ⊖ Reference Electrode (Out of Chest)

Wilson Central Terminal

High 60 Hz Noise → ~~Notch Filter~~

IVC Electrode

- RAA Catheter – Electrode #6 - 25 cm from catheter tip

Unipolar Reference

Wilson Central Terminal

IVC Electrode

II

V₁

HB
p
d

Bip 3-4

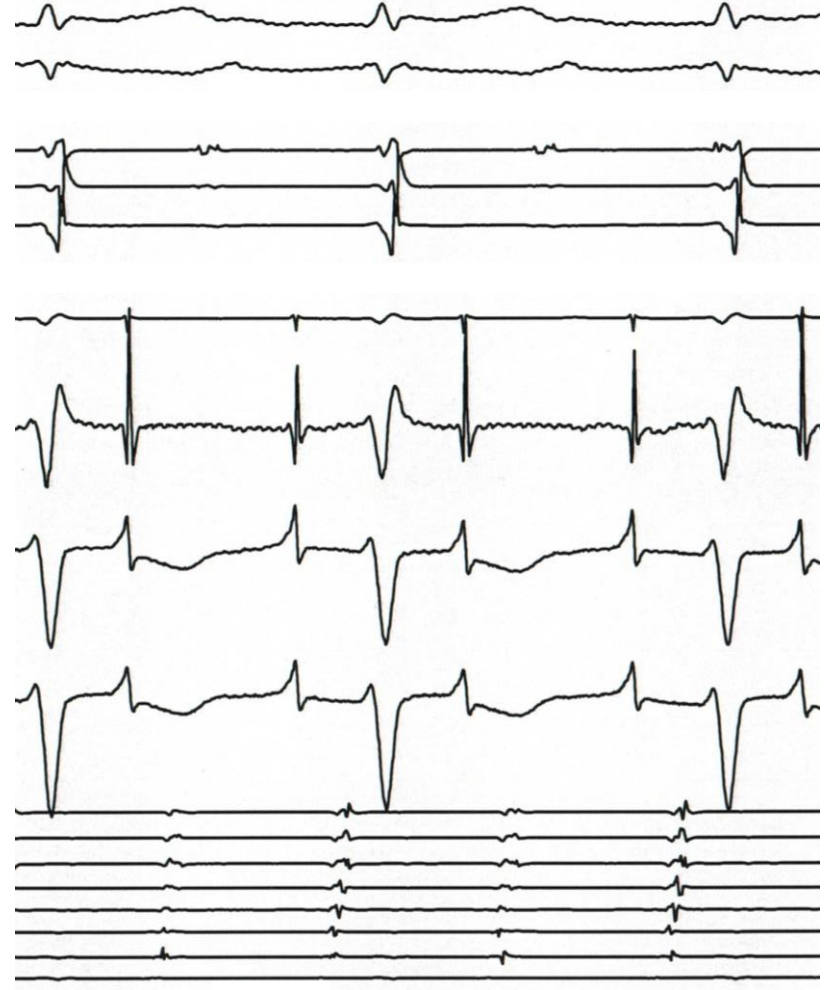
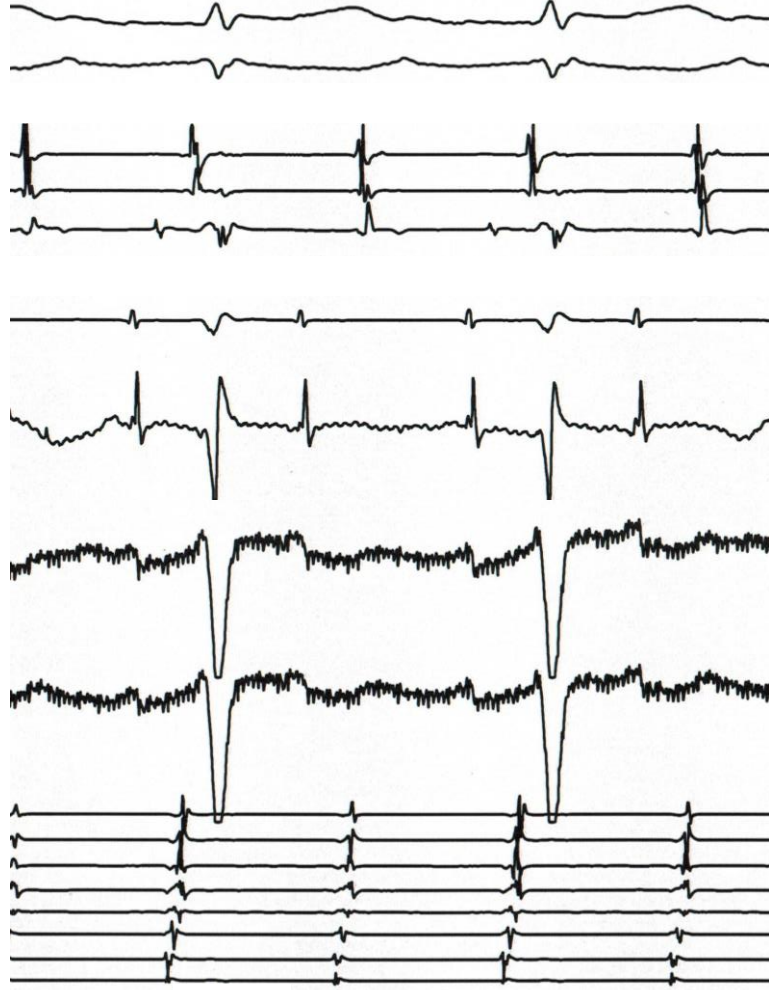Bip 1-2

Ablation

Uni 2

Uni 1

CS
p
d





Unipolar Electrogram

- ⊕ Mapping Electrode
- ⊖ Reference Electrode (Out of Chest)

Wilson Central Terminal

High 60 Hz Noise → ~~Notch Filter~~

IVC Electrode

- RAA Catheter – Electrode #6 - 25 cm from catheter tip

Filtering

0.5 or 1 Hz – 500 Hz

Thank You !