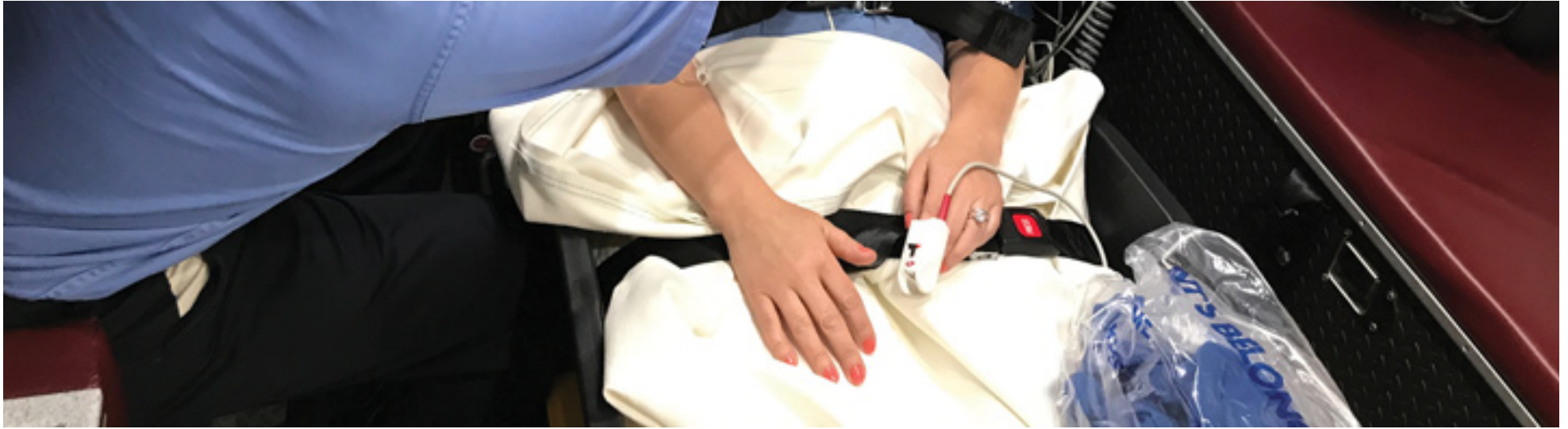



AIRWAY & RESPIRATORY, PATIENT CARE

# How to Read and Interpret End-Tidal Capnography Waveforms

Issue 8 and Volume 42.

By [Rommie L. Duckworth, LP](#) | 8.1.17



Capnography is a great way to confirm airway device placement and monitor ventilation, but it can do so much more. Carbon dioxide (CO<sub>2</sub>) is a product of metabolism transported via perfusion and

expelled through ventilation. End-tidal carbon dioxide (EtCO<sub>2</sub>) waveform monitoring allows you to measure all three simultaneously, making it the most important vital sign you use.<sup>1</sup>

To evaluate the metabolism, ventilation and perfusion of a patient through EtCO<sub>2</sub> waveform monitoring you need to read the PQRST: proper, quantity, rate, shape and trend.

*Proper* means that you should know the normal readings for quantity, rate, shape and trending of EtCO<sub>2</sub>. In this case, normal means what we find in a healthy person with no metabolism, ventilation or perfusion problems. One of the great things about EtCO<sub>2</sub> is that although ventilation rates vary based on age, normal readings for quantity, shape and trends are the same for men and women of all age groups, making them easy to remember.

*Quantity*; target EtCO<sub>2</sub> value should be 35-45 mmHg.

*Rate* of ventilation should be 12-20 breaths per minute (bpm) for adults if the patient is breathing on their own and 10-12 bpm if you're ventilating them. Children should be ventilated at a rate of 15-30 bpm; 25-50 bpm for infants. Ventilating too quickly won't let enough CO<sub>2</sub> build up in the alveoli, resulting in lower EtCO<sub>2</sub> readings. Ventilating too slowly will allow extra CO<sub>2</sub> to build up, resulting in higher readings.

*Shape* of the waveform should normally be a rectangle with rounded corners. Different waveform shapes can indicate different conditions.

*Trending* of the quantity, rate and shape of EtCO<sub>2</sub> should be stable or improving.



Although reading EtCO<sub>2</sub> waveforms can be easy, interpreting what you see requires understanding how the waveforms and numbers are produced.

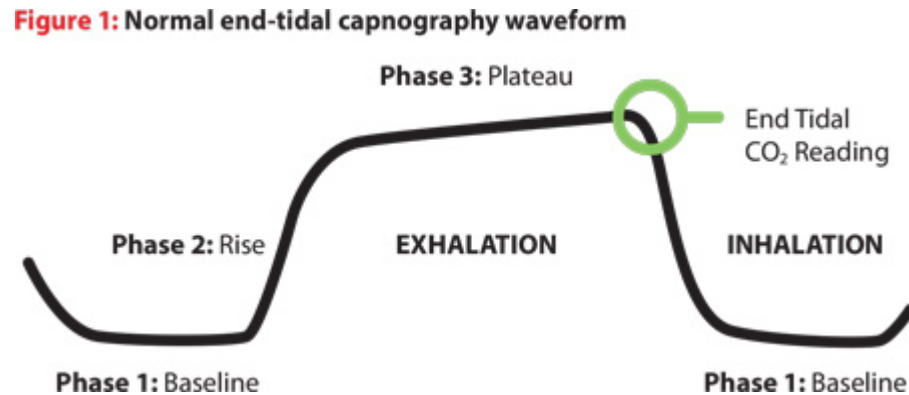


An end-tidal capnography waveform measures and displays the peak amount of CO<sub>2</sub> at the end of exhalation.

## Reading the Waves

When it comes to capnography, everyone knows the normal adult respiratory rate of 12–20 breaths per minute and most people know, or quickly learn, that the normal quantity of exhaled CO<sub>2</sub> is 35–45 mmHg. What can be intimidating is the idea of reading the shape of the waveform, but in practice it's not difficult at all.

An end-tidal capnography waveform is a simple graphic measurement of how much CO<sub>2</sub> a person is exhaling. The normal end-tidal capnography wave form is basically a rounded rectangle.<sup>2</sup> (See Figure 1, p. 48.) When a person is breathing out CO<sub>2</sub>, the graph goes up. When a person is breathing in, it goes back down.



Phase 1 is inhalation. This is the baseline. Since no CO<sub>2</sub> is going out when a patient is breathing in, the baseline is usually zero.

Phase 2 is the beginning of exhalation. CO<sub>2</sub> begins to travel from the alveoli through the anatomical dead space of the airway causing a rapid rise in the graph as the CO<sub>2</sub>.

Phase 2 measures the exhaled CO<sub>2</sub> from the alveoli mixed with the gas that was in the dead space. This part of the graph goes up as the more concentrated CO<sub>2</sub> gases from lower in the lungs rise up past the sensor.

Phase 3 is when the sensor is receiving the CO<sub>2</sub>-rich gas that was in the alveoli. Because this is a fairly stable amount, the graph levels off into a plateau. The measurement at the end of the tide of respiration, the peak measurement at the very end of phase 3, is the EtCO<sub>2</sub> reading.

After the end of phase 3, the patient inhales again, bringing clear air past the sensor, dropping the graph back down to zero to start over again at phase 1.

Although it can be intimidating to try and memorize what each phase (and the angles between them) represents, you can think of it as follows: The left side shows how quickly and easily air is moving out of the lungs; the right side shows how quickly and easily air is going in; the top shows how easily the alveoli are emptying.

If all we wanted to read from capnography was ventilation, this would be enough, but to indirectly measure a patient's perfusion and metabolic status we must understand how CO<sub>2</sub> gets to the lungs to be exhaled.

## Putting on the Pressure

Many factors affect how oxygen gets into the body and CO<sub>2</sub> gets out; however, the biggest influence is the partial pressures of these gasses.

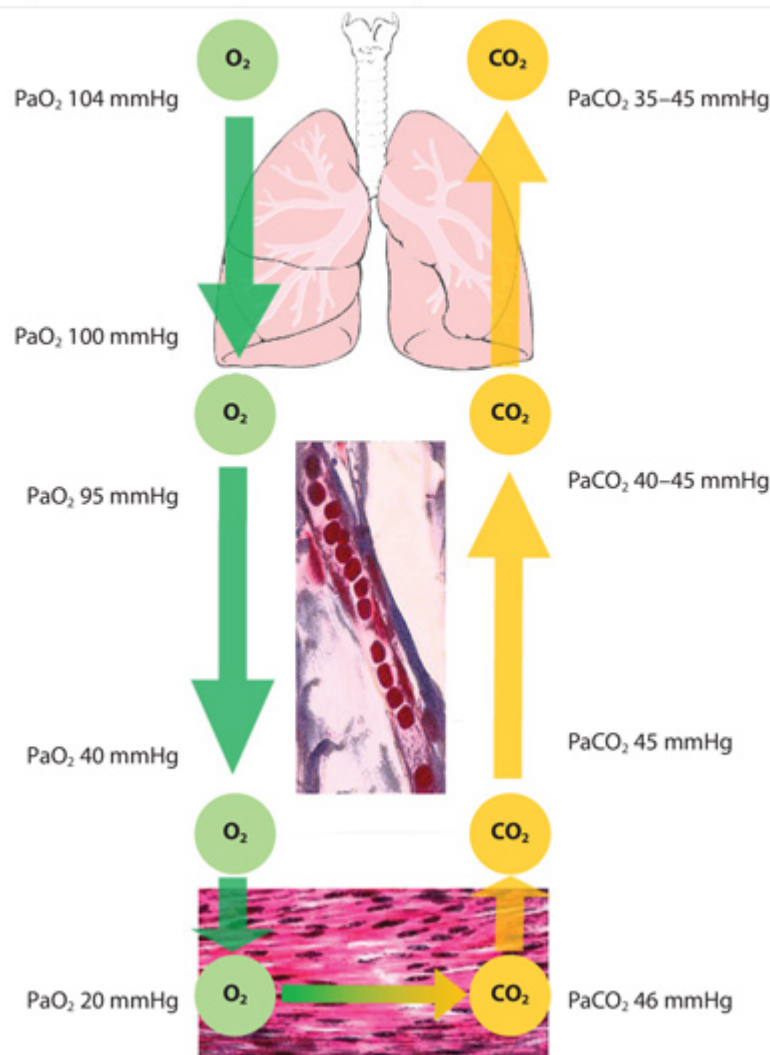
Although hemoglobin, myoglobin and other body chemicals play a part in transporting gasses, it can be helpful to begin by just picturing the partial pressures pushing the gasses from one part of the body to the next.<sup>3</sup>

The normal partial pressure of oxygen in ambient air is approximately 104 mmHg. It gets humidified and absorbed by the body as it's inhaled, bringing the partial pressure down to 100 mmHg by the time the oxygen reaches the alveoli. The partial pressure of oxygen in the alveoli is known as PaO<sub>2</sub>.

Oxygen is then pushed from the partial pressure of 100 mmHg in the alveoli to the lower partial pressure of 95 mmHg in the capillaries surrounding the alveoli. Oxygen gets carried through the circulatory system, getting absorbed along the way.

By the time the oxygen gets to the end of its journey, it has a partial pressure of approximately 40 mmHg, still high enough to allow it to move into muscles and organs that have a lower partial pressure of approximately 20 mmHg.<sup>4</sup> (See Figure 2, p. 49.)

**Figure 2:** Partial pressures as O<sub>2</sub> and CO<sub>2</sub> are pushed to different parts of the body



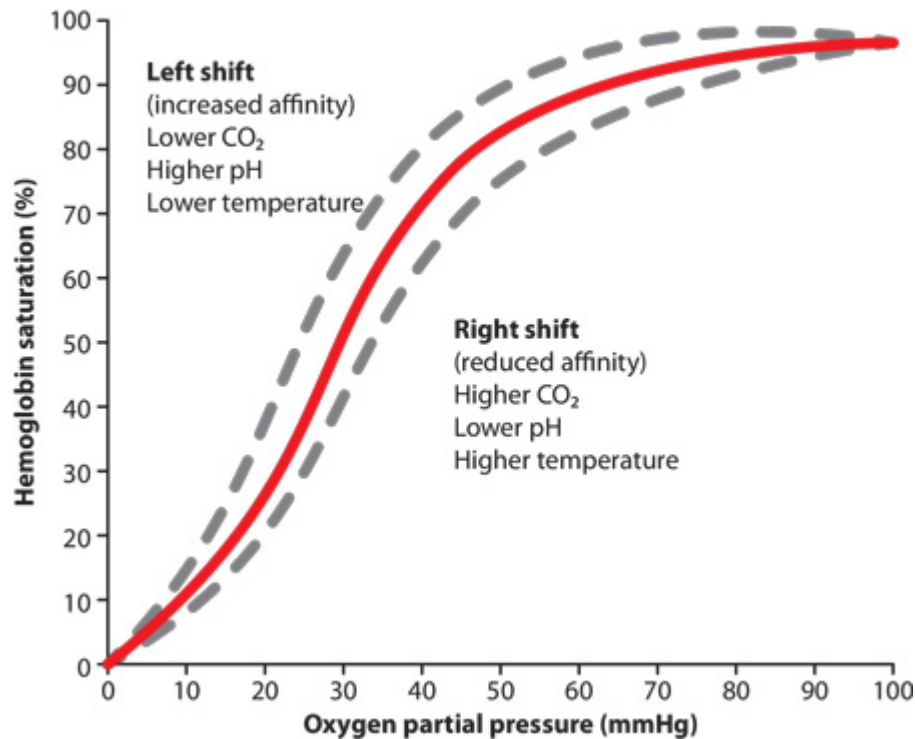
If the organs are functioning normally, the oxygen is metabolized, producing the CO<sub>2</sub> that we're ultimately going to measure. Although the journey back involves CO<sub>2</sub> moving primarily through the body's buffer system as bicarbonate (HCO<sub>3</sub><sup>-</sup>) its movement is still largely governed by partial pressures.<sup>3</sup>



The partial pressure of carbon dioxide ( $\text{PCO}_2$ ) as it leaves the organs is approximately 46 mmHg, just high enough to push it into the capillaries which have a partial pressure of only 45 mmHg.<sup>4</sup>  $\text{CO}_2$  travels through venous circulation largely untouched.

In the end it moves from 45 mmHg at the capillaries surrounding the alveoli into the alveoli themselves. From the alveoli to exhalation the  $\text{CO}_2$  is approximately 35-45 mmHg.<sup>4</sup> At this level it will get exhaled and measured by the  $\text{EtCO}_2$  sensor, letting us know that the patient's metabolism, perfusion and ventilation are all working properly taking up oxygen, converting it to  $\text{CO}_2$  and releasing it at a normal rate (or not).

If you were to know one more thing about oxygen and  $\text{CO}_2$  transport, it's that high  $\text{CO}_2$  reduces the affinity of hemoglobin for oxygen. Referred to as the Bohr effect, during normal body function this is a good thing, (the high  $\text{CO}_2$  in muscles and organs help hemoglobin release needed oxygen). However, prolonged periods of high  $\text{CO}_2$  and associated acidosis make it hard for hemoglobin to pickup and transport oxygen. This can be seen as a shift of the oxyhemoglobin dissociation curve to the right.<sup>4,5</sup> (See Figure 3, p. 50.)

**Figure 3: Oxyhemoglobin dissociation curve**

Conversely, if the patient has low CO<sub>2</sub>, perhaps because of hyperventilation, it will cause an increased affinity for oxygen, allowing hemoglobin to pick oxygen up more easily. However, if the low CO<sub>2</sub> is prolonged, the hemoglobin may not release the oxygen into the organs. This is referred to as the Haldane effect and is seen as a shift of the oxyhemoglobin dissociation curve to the left. In this case you may have a “normal” pulse oximetry reading even though organs aren’t getting the oxygen because hemoglobin is saturated with oxygen, but this oxygen remains “locked” to the hemoglobin.<sup>4,5</sup> In this way your EtCO<sub>2</sub> reading can help you better interpret the validity and meaning of other vital signs like pulse oximetry, blood pressure and more.

# Oh! PQRST

Now that we've peeked behind the curtain as to how CO<sub>2</sub> is produced in metabolism and transported via perfusion, let's use the PQRST (proper, quantity, rate, shape and trending) method to different types of emergency calls.

We read PQRST in order, asking, "What is proper?" Consider what your desired goal is for this patient. "What is the quantity?" "Is that because of the rate?" If so, attempt to correct the rate. "Is this affecting the shape?" If so, correct the condition causing the irregular shape. "Is there a trend?" Make sure the trend is stable where you want it, or improving. If not, consider changing your current treatment strategy.

Below are several examples.

## Advanced Airway/Intubation

P: Ventilation. Confirm placement of the advanced airway device.<sup>6,7</sup>

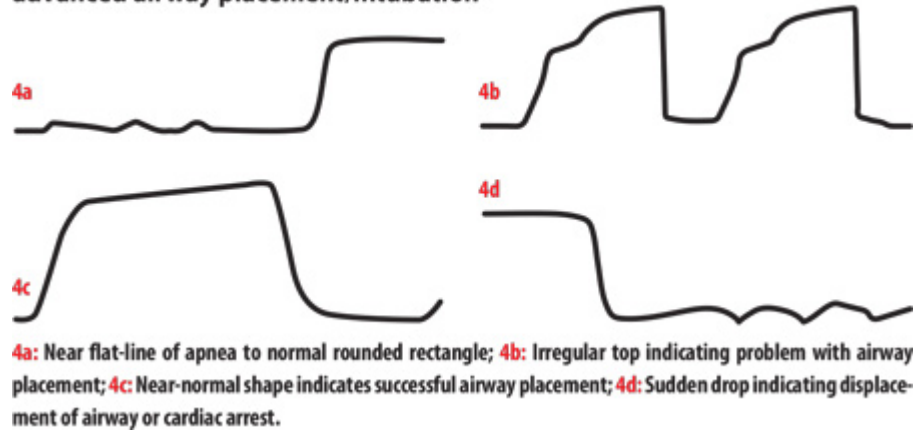
Q: Goal is 35-45 mmHg.

R: 10-12 bpm, ventilated.

S: Near flat-line of apnea to normal rounded rectangle EtCO<sub>2</sub> waveform. (See Figure 4a, p. 50.) If the top of the shape is irregular (e.g., like two different EtCO<sub>2</sub> waves mashed together) it may indicate a problem with tube placement. (See Figure 4b, p. 50.) This shape can indicate a leaking cuff, supraglottic placement, or an endotracheal tube in the right mainstem bronchus. This shape is produced when one lung—often the right lung—ventilates first, followed by CO<sub>2</sub> escaping from the

left lung. If the waveform takes on a near-normal shape (see Figure 4c, p. 50) then the placement of the advanced airway was successful.<sup>8</sup>

**Figure 4a–4d: Capnography waveforms seen during advanced airway placement/intubation**



T: Consistent Q, R and S with each breath. Watch for a sudden drop indicating displacement of the airway device and/or cardiac arrest. (See Figure 4d, p. 50.)

## Cardiac Arrest

P: Ventilation and perfusion. Confirmation of effective CPR. Monitoring for return of spontaneous circulation (ROSC) or loss of spontaneous circulation.<sup>1,6,7,9</sup>

Q: Goal is > 10 mmHg during CPR. Expect it to be as high as 60 mmHg when ROSC is achieved. (See Figure 5, p. 50.)

**Figure 5: Capnography waveform indicating ROSC after cardiac arrest**



R: 10–12 bpm, ventilated.

S: Rounded low rectangle EtCO<sub>2</sub> waveform during CPR with a high spike on ROSC.

T: Consistent Q, R and S with each breath. Watch for a sudden spike indicating ROSC or a sudden drop indicating displacement of the airway device and/or re-occurrence of cardiac arrest.

## Optimized Ventilation

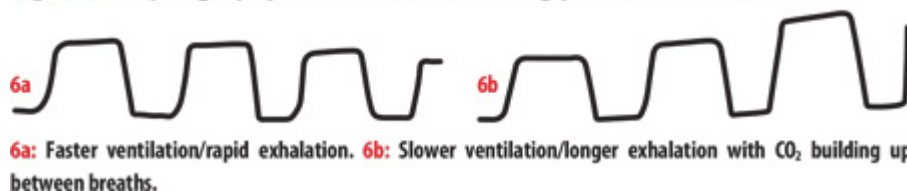
P: Ventilation. May include hyperventilation situations such as anxiety as well as hypoventilation states such as opiate overdose, stroke, seizure, or head injury.<sup>1,6,7</sup>

Q: Goal is 35–45 mmHg. Control using rate of ventilation. If EtCO<sub>2</sub> is low (i.e., being blown off too fast), begin by assisting the patient to breathe more slowly or by ventilating at 10–12 bpm. If EtCO<sub>2</sub> is high (i.e., accumulating too much between breaths), begin by ventilating at a slightly faster rate.

R: Goal is 12–20 bpm for spontaneous respirations ; 10–12 bpm, for artificial ventilations.

S: Rounded low rectangle EtCO<sub>2</sub> waveform. Faster ventilation will produce wave shapes that aren't as wide or as tall since rapid exhalation doesn't take as long and contains less CO<sub>2</sub>. (See Figure 6a, p. 51.) Slower ventilation produces wave shapes that are wider and taller as exhalation takes longer and more CO<sub>2</sub> builds up between breaths. (See Figure 6b, p. 51.)



**Figure 6: Capnography waveforms illustrating problematic ventilation**

T: Consistent Q, R and S with each breath trending towards optimal ventilation.

## Shock

P: Metabolism and perfusion. As perfusion decreases and organs go into shock—whether hypovolemic, cardiogenic, septic or another type—less CO<sub>2</sub> is produced and delivered to the lungs, so EtCO<sub>2</sub> will go down, even at normal ventilation rates. In the context of shock, EtCO<sub>2</sub> can help differentiate between a patient who's anxious and slightly confused and one who has altered mental status due to hypoperfusion. It can also indicate a patient whose metabolism is significantly reduced by hypothermia, whether or not it's shock-related.<sup>1,7,10,11</sup>

Q: Goal is 35–45 mmHg. EtCO<sub>2</sub> < 35 mmHg in the context of shock indicates significant cardiopulmonary distress and the need for aggressive treatment.

R: Goal is 12–20 bpm for spontaneous respirations; 10–12 bpm for artificial ventilations. Anxiety and distress can raise the patient's respiratory rate. Likewise, it may cause a provider to ventilate too fast. Consider that faster rates will also lower EtCO<sub>2</sub>, and may also increase pulmonary venous pressure, decreasing blood return to the heart in a patient who's already hypoperfusing.<sup>6</sup>

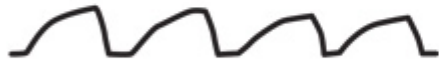S: Rounded low rectangle EtCO<sub>2</sub> waveform.

T: Quantity will continuously trend down in shock. The rate of ventilations will increase in early compensatory shock and then decrease in later non-compensated shock. The shape will not change significantly because of the shock itself. (See Figure 7, p. 51.)

**Figure 7:** Capnography waveform trending down in shock



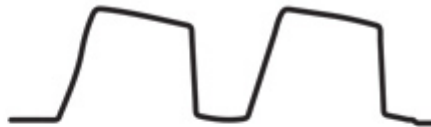**Figure 8:** Capnography waveform indicating hypoxia due to asthma



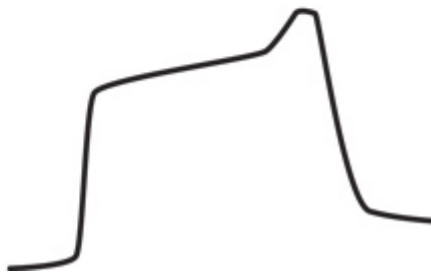**Figure 9:** Capnography waveform indicating hypoxia due to mechanical obstruction



**Figure 10:** Capnography waveform illustrating emphysema or leaking alveoli in pneumothorax



**Figure 11:** Capnography waveform indicating poor lung compliance, also seen in obese and pregnant patients



## Pulmonary Embolism

P: Ventilation and perfusion. Using EtCO<sub>2</sub> along with other vital signs can help you identify a mismatch between ventilation and perfusion.

Q: Goal is 35-45 mmHg. EtCO<sub>2</sub> < 35 mmHg in the presence of a normal respiratory rate and otherwise normal pulse and blood pressure may indicate that ventilation is occurring, but perfusion isn't as the embolism is preventing the ventilation from connecting with the perfusion. This is a ventilation/perfusion mismatch.<sup>12</sup>

R: Goal is 12–20 bpm for spontaneous respirations; 10–12 bpm for artificial ventilations.

S: Low, rounded rectangle EtCO<sub>2</sub> waveform.

T: As with shock, the quantity will continuously trend down as the patient's hypoperfusion worsens.

## Asthma

P: Ventilation. Although the classic “shark's fin” shape is indicative of obstructive diseases like asthma, EtCO<sub>2</sub> can provide additional information about your patient.<sup>7,8</sup>

Q: Goal is 35–45 mmHg. The trend of quantity and rate together can help indicate if the disease is in an early or late and severe stage.

R: Goal is 12–20 bpm for spontaneous respirations; 10–12 bpm for artificial ventilations.

S: Slow and uneven emptying of alveoli will cause the shape to slowly curve up (phase 3) resembling a shark's fin (if the shark is swimming left) instead of the normal rectangle. (See Figure 8, p. 51.)

T: Early on the trend is likely to be a shark's fin shape with an increasing rate and lowering quantity. As hypoxia becomes severe and the patient begins to get exhausted, the shark's fin shape will continue, but the rate will slow and the quantity will rise as CO<sub>2</sub> builds up.

# Mechanical Obstruction

P: Ventilation. The “shark’s fin” low-expiratory shape is present but is “bent” indicating obstructed and slowed inhalation as well.<sup>8</sup>

Q: Goal is 35–45 mmHg.

R: Goal is 12–20 bpm for spontaneous respirations; 10–12 bpm for artificial ventilations.

S: Again, slow and uneven emptying of alveoli mixed with air from the anatomical “dead space” will cause the shape to slowly curve up resembling a shark’s fin looking left instead of a rectangle. In this case, phase 4 inhalation is blocked (e.g., by mucous, a tumor or foreign body airway obstruction) causing the righthand side of the rectangle to lean left, like the shark is trying to swim left even faster. (See Figure 9.)

T: Again, as hypoxia becomes severe and the patient begins to get exhausted, the shark’s fin shape will continue, but the rate will slow and the quantity will rise as CO<sub>2</sub> builds up.

## Emphysema & Pneumothorax

P: Ventilation. Patients with emphysema may have so much damage to their lung tissue that the shape of their waveform may “lean in the wrong direction.” In a similar way, patients with a pneumothorax won’t be able to maintain the plateau of phase 3 of the EtCO<sub>2</sub> wave. The shape will start high and then trail off as air leaks from the lung, producing a similar, high on the left, lower on the right shape.<sup>8,13</sup>

Q: Goal is 35-45 mmHg.

R: Goal is 12-20 bpm for spontaneous respirations; 10-12 bpm for artificial ventilations.

S: An indication of very poor surface area for emphysema or leaking alveoli in pneumothorax is that the top of rectangle slopes down from left to right instead of sloping gradually up. (See Figure 10.)

T: Consistent Q, R and S with each breath as always is our goal. You should watch for and correct deviations.

## Patient with Diabetes

P: Ventilation and perfusion. EtCO<sub>2</sub> can aid in differentiation between hypoglycemia and diabetic ketoacidosis. Sometimes the difference is obvious, but in other situations, every diagnostic tool can help.

Q: Goal is 35-45 mmHg.

R: Goal is 12-20 bpm for spontaneous respirations. A hypoglycemic patient is likely to have a relatively normal rate of respiration. A patient who's experiencing diabetic ketoacidosis will have increased respirations, lowering the quantity of CO<sub>2</sub>. In addition, CO<sub>2</sub> in the form of bicarbonate in the blood will be used up by the body trying to buffer the diabetic ketoacidosis. In this way, low EtCO<sub>2</sub> can help indicate the presence of significant ketoacidosis.<sup>1,8,14</sup>

S: Rounded rectangle EtCO<sub>2</sub> waveform.



T: Consistent Q, R and S with each breath for hypoglycemia. A fast rate of respirations and low quantity for DKA.

## Pregnant Patients & Poor Lung Compliance

P: Ventilation. In addition to using EtCO<sub>2</sub> in the ways described above, patients with poor lung compliance, obese patients and pregnant patients may also exhibit a particular wave shape that may indicate that they're highly sensitive on adequate ventilation.<sup>8</sup>

Q: Goal is 35-45 mmHg.

R: Goal is 12-20 bpm for spontaneous respirations; 10-12 bpm for artificial ventilations.

S: Rounded low rectangle EtCO<sub>2</sub> waveform, but with a sharp increase in the angle of phase 3 that looks like a small uptick or “pig tail” on the righthand side of the rectangle, sometimes referred to as phase 4 of the waveform. This is CO<sub>2</sub> being squeezed out of the alveoli by the poorly compliant lung tissue, obese chest wall, or pregnant belly, before the same weight closes off the small bronchi. These patients are progress quickly from respiratory distress to respiratory failure.

T: Consistent Q, R and S with each breath.

## Summary

The PQRST method is designed to be a simple and practical way to expand the use of EtCO<sub>2</sub> as a diagnostic tool, but it's by no means the end of the story.

When used with patients who have been administered paralytics or who are on ventilators, other waveforms can help providers finetune their critical care by identifying medication problems such as inadequate sedation or malignant hyperthermia, mechanical problems such as air leaks and ventilator rebreathing, and physiological issues such as ventilation/perfusion mismatch conditions.<sup>3,12</sup>

Although no single vital sign is definitive, as a simultaneous measure of metabolism, ventilation and perfusion, end-tidal waveform capnography is one of the most important diagnostic tools available to EMS providers.

**Acknowledgment:** Special thanks to Patrick Holland, LP, and David Bunting, RRT, AEMT, MS, for their assistance with this article.

## References

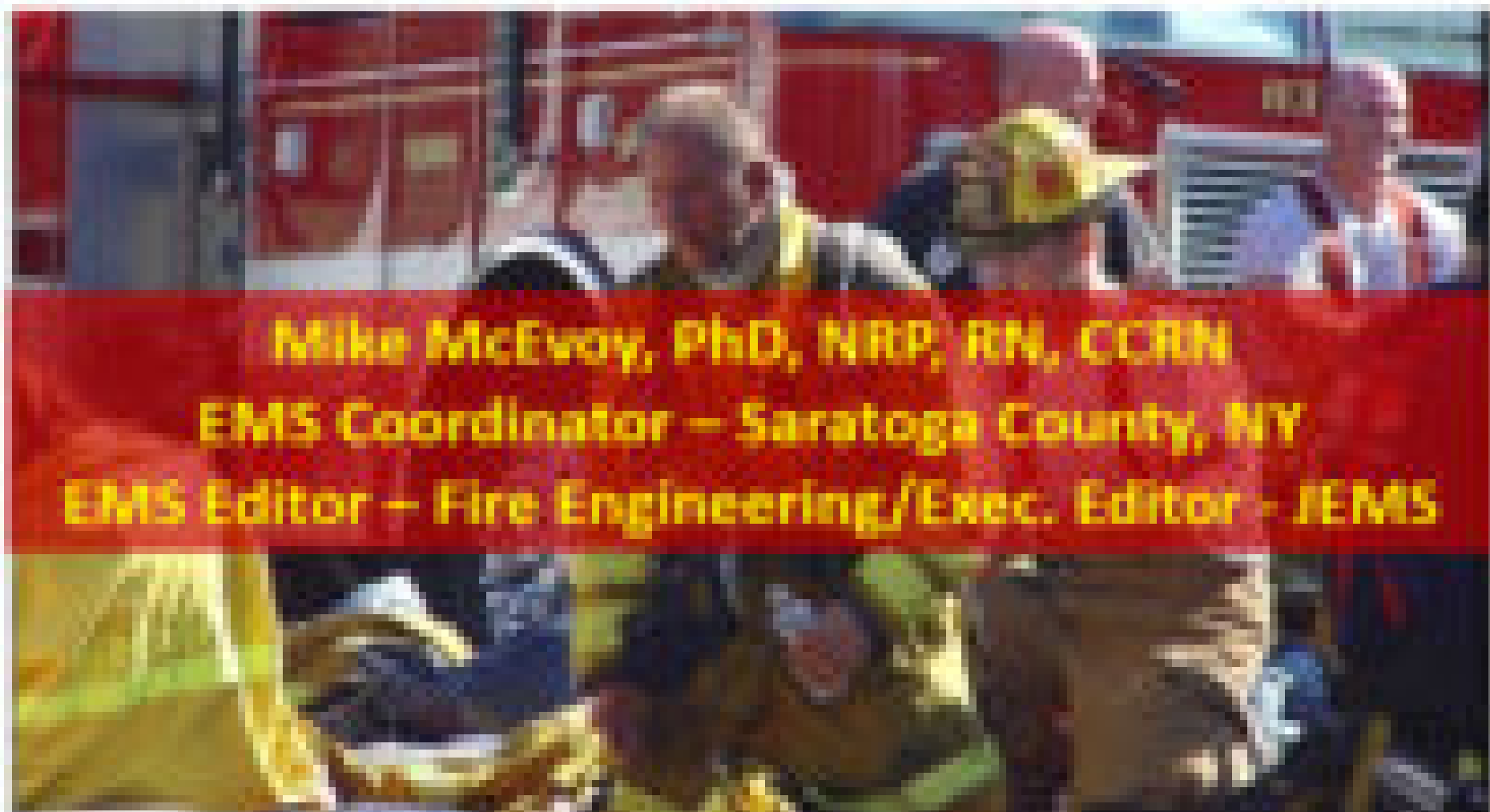
1. Rieves A, Bleess B. (2017.) Be all end-tidal: The expanding role of capnography in prehospital care. National Association of EMS Physicians. Retrieved May 19, 2017, from [www.naemsp-blog.com/emsmed/2017/3/22/be-all-end-tidal-the-expanding-role-of-capnography-in-prehospital-care](http://www.naemsp-blog.com/emsmed/2017/3/22/be-all-end-tidal-the-expanding-role-of-capnography-in-prehospital-care).
2. Bhavani-Shankar K, Philip JH. Defining segments and phases of a time capnogram. *Anesth Analg*. 2000;91(4):973-7.
3. American Academy of Orthopaedic Surgeons. *Nancy Caroline's emergency care in the streets*. Jones & Bartlett Learning: Burlington, Mass., 2017.

4. OpenStax. (March 6, 2013.) Anatomy and physiology. Retrived May 20, 2017, from [www.opentextbc.ca/anatomyandphysiology](http://www.opentextbc.ca/anatomyandphysiology).
5. Desai R. (2017.) Bohr effect vs. Haldane effect. Khan Academy. Retrieved May 20, 2017, from [www.khanacademy.org/science/health-and-medicine/advanced-hematologic-system/hematologic-system-introduction/v/bohr-effect-vs-haldane-effect](http://www.khanacademy.org/science/health-and-medicine/advanced-hematologic-system/hematologic-system-introduction/v/bohr-effect-vs-haldane-effect).
6. Link MS, Berkow LC, Kudenchuk PJ, et al. Part 7: Adult advanced cardiovascular life support: 2015 American Heart Association guidelines update for cardiopulmonary resuscitation and emergency cardiovascular care. *Circulation*. 2015;132(18 Suppl 2):S444-464.
7. DiCorpo JE, Schwester D, Dudley LS, et al. A wave as a window. Using waveform capnography to achieve a bigger physiological patient picture. *JEMS*. 2015;40(11):32-35.
8. Yartsev A. (Sep. 15, 2015.) Abnormal capnography waveforms and their interpretation. *Deranged Physiology*. Retrieved May 20, 2017, from [www.derangedphysiology.com/main/core-topics-intensive-care/mechanical-ventilation-0/Chapter%205.1.7/abnormal-capnography-waveforms-and-their-interpretation](http://www.derangedphysiology.com/main/core-topics-intensive-care/mechanical-ventilation-0/Chapter%205.1.7/abnormal-capnography-waveforms-and-their-interpretation).
9. Murphy RA, Bobrow BJ, Spaite DW, et al. Association between prehospital cpr quality and end-tidal carbon dioxide levels in out-of-hospital cardiac arrest. *Prehosp Emerg Care*. 2016;20(3):369-377.

10. Guerra WF, Mayfield TR, Meyers MS, et al. Early detection and treatment of patients with severe sepsis by prehospital personnel. *J Emerg Med*. 2013;44(6):1116–1125.
11. Hunter CL, Silvestri S, Ralls G, et al. A prehospital screening tool utilizing end-tidal carbon dioxide predicts sepsis and severe sepsis. *Am J Emerg Med*. 2016;34(5):813–819.
12. Gravenstein JS, Jaffe MB, Gravenstein N, et al., editors. *Capnography*. Cambridge University Press: Cambridge, UK, 2011.
13. Thompson JE, Jaffe MB. Capnographic waveforms in the mechanically ventilated patient. *Respir Care*. 2005;50(1):100–108; discussion 108–109.
14. Bou Chebl R, Madden B, Belsky J, et al. Diagnostic value of end tidal capnography in patients with hyperglycemia in the emergency department. *BMC Emerg Med*. 2016;16:7.

# More

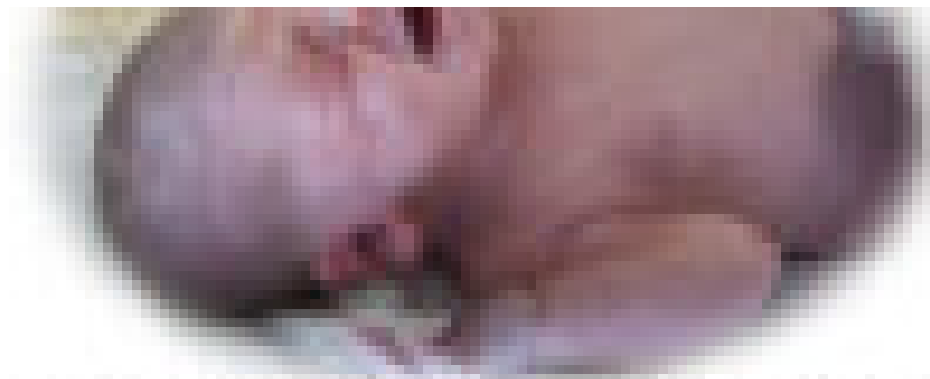
# Firefighter Rehab





**PATIENT CARE**

# **Monitoring and Hydration in Firefighter Rehab**



## **When one Patient Turns into Two! Simulation for (Premature) Field Deliveries**


**Paul E. Phrampus, MD FACEP FSSH**

Director, Winter Institute for Simulation, Education and Research (WISER)

Professor, Departments of Emergency Medicine and Anesthesiology

University of Pittsburgh and UPMC

Medical Director, Patient Safety, UPMC Health System



COMMUNITY PARAMEDICINE AND MOBILE HEALTH

## When one Patient Turns into Two! – Simulation for Field Deliveries

A PRESENTATION BY ESO

# Turning Insights into Action

Improve your agency and your community  
with the 2019 ESO EMS Index

The logo for ESO (Emergency Services Organization) features the letters 'eso' in a white, lowercase, sans-serif font. The 'e' and 's' are connected, and the 'o' is a simple circle. The logo is centered on a dark blue rectangular background.

#### DOCUMENTATION & PATIENT CARE REPORTING

## **Turning Insights into Action: Improve your agency and your community with the 2019 ESO EMS Index**

A purple rectangular graphic with white text. The text is arranged in three lines: 'Cutting Edge Airway' on the first line, 'Management:' on the second line, and 'The EMT can DO IT!' on the third line. The font is a bold, sans-serif typeface.



## TRAUMA

# Cutting-Edge First-Line Airway Management: Multiple Ways the EMT Can Make A Difference



---

## ABOUT

[About Us](#)

[Contact Us](#)

[Advertise](#)

[Submissions](#)

## TOPICS

[Operations](#)

[Training/CME](#)

[Patient Care](#)

[Major Incidents](#)

[Administration and Leadership](#)

[Community Paramedicine and Mobile Health](#)

## OUR NETWORK

[EMS Today](#)

[Fire Engineering](#)

[Fire Apparatus & Emergency Equipment](#)

[FirefighterNation](#)

[FDIC International](#)



Privacy Policy

Copyright © 2019